

# Effect of Gentian Violet, Corticosteroid and Tar Preparations in *Staphylococcus aureus*-Colonized Atopic Eczema

Knut Brockow<sup>a, b</sup> Petra Grabenhorst<sup>b</sup> Dietrich Abeck<sup>a, b</sup> Bernd Traupe<sup>c</sup>  
Johannes Ring<sup>a, b</sup> Udo Hoppe<sup>c</sup> Florian Wolf<sup>c</sup>

<sup>a</sup>Klinik und Poliklinik für Dermatologie und Allergologie am Biederstein, Technische Universität München, und  
<sup>b</sup>Universitätsklinik Hamburg-Eppendorf, und <sup>c</sup>Paul Gerson Unna Skin Research Center, Beiersdorf AG,  
Hamburg, Deutschland

## Key Words

Gentian violet · *Staphylococcus aureus* · Atopic eczema · Liquor carbonis detergens · Corticosteroids

## Abstract

**Background:** In atopic eczema (AE), skin colonization with *Staphylococcus aureus* plays a possible role in the pathophysiology of the disease. **Methods:** Thirty-eight patients with AE were screened for their cutaneous colonization with *S. aureus*. The antibacterial and clinical efficacy of topical therapy with the antiseptic dye gentian violet, a potent glucocorticosteroid or a tar solution (liquor carbonis detergens) was evaluated in vivo in 21 patients with a density of  $>10^4$  CFU/cm<sup>2</sup> and in vitro. Skin sites were treated twice daily for 4 days with the active drug or a corresponding control. Quantification of *S. aureus* was done daily during therapy as well as 3 days thereafter. The severity of the lesions was rated by a regional SCORAD. **Results:** In gentian-violet-treated skin, bacterial density decreased significantly in lesional ( $p < 0.001$ ) and unaffected skin ( $p < 0.001$ ). Bacterial densities did not decrease during therapy with glucocorticosteroid or liquor carbonis detergens but dropped afterwards. All therapeutics reduced the severity score, reduction being greatest for the glucocorticosteroid and

lowest for liquor carbonis detergens. In vitro, a high antibactericidal efficacy was demonstrated only for gentian violet. **Conclusions:** Antibacterial therapy with gentian violet not only reduces *S. aureus* dramatically, but also reduces the severity of the eczema. Reduction of *S. aureus* after therapy with glucocorticosteroids and LCD seems to be secondary to improvement of the skin condition.

## Introduction

Abnormal cutaneous staphylococcal colonization is a typical feature in patients with atopic eczema (AE) [1]. The density of *S. aureus* has been shown to correlate with eczema severity [2]. Skin colonization with *S. aureus* is considered to be an important factor for maintenance of chronic inflammation in AE. Bacterial products like staphylococcal  $\alpha$ -toxin, different lipases and collagenases can produce direct cell damage and others like staphylococcal enterotoxin A and B are immunologically active superantigens [3]. Antibacterial therapy leads in many cases to an improvement of AE, even without signs of active infection [4]. These findings provide the rationale for the use of antiseptics and antibiotics in addition to standard treatment regimens.

Gentian violet, a mixture of methyl violet and crystal violet, is a triphenylmethane dye with a broad antibacterial spectrum and high bactericidal efficacy [5]. It has been used for decades in the treatment of impetiginized eczema and bacterial skin infections. However, although it is widely applied in clinical practice, studies on its efficacy are missing. The purpose of this study was to investigate the antibacterial efficacy *in vivo* and *in vitro* as well as the clinical efficacy of topical 0.3% aqueous gentian violet in comparison to the potent topical corticosteroid diflucortolone-21-valerate and a 10% tar solution, liquor carbonis detergens, in patients with *S.-aureus*-colonized AE.

## Patients and Methods

### Patients

Thirty-eight consecutive Caucasian outpatients with mild to moderate chronic AE according to the criteria of Hanifin and Rajka were screened for cutaneous colonization with *S. aureus* [6]. The patients had not used topical glucocorticosteroids for 1 week and topical or oral antibiotics for 4 weeks prior to the study. Patients with severe eczema that required therapy with glucocorticosteroids or with a colonization of less than  $10^4$  colony-forming units (CFU)/cm<sup>2</sup> were excluded. The 21 patients with *S.-aureus*-colonized AE, who were included in the study (11 women and 10 men; 14–58 years of age; mean age 31.7 years) were tested after their informed consent had been obtained.

### Clinical Evaluation

Before and 2 days after treatment the severity of the atopic eczema was assessed with the SCORAD index, which gives a highest score of 103 [6]. Treatment and control areas were scored with a modified local SCORAD. Six intensity items were selected: (1) erythema; (2) edema/papulation; (3) oozing/crusts; (4) excoriations; (5) lichenification, and (6) local pruritus. Each item was graded on a 4-point scale (0 = absent; 1 = mild; 2 = moderate; 3 = severe). A total severity score was calculated as the sum of the grading. This gives a highest possible score of 18.

### Treatment Protocol

Four symmetrical sites of typical eczematous skin lesions on the flexor aspects of the forearms (diameter 5 cm) and of unaffected skin (predominantly on the upper arm) were chosen for treatment; the total number of sites was 84. 0.3% aqueous gentian violet was applied to 11 patients (group A), the 10% tar solution liquor carbonis detergens in a water-in-oil emulsion (Neribas Salbe®; group B) and diflucortolone-21-valerate (Nerisona Salbe®; group C) to 5 patients each. The therapeutics were applied to eczematous skin lesions and areas of unaffected skin twice daily over 4 days. Symmetrically corresponding control sites were treated with the corresponding vehicle only (water or Neribas Salbe®).

### Bacteriologic Assessment

Samples for quantification of *S. aureus* were consecutively taken on days 1–5 as well as 3 days thereafter. Bacterial solutions were collected from each site using a scrub method developed by Williamson and Kligman [7]. The solutions were immediately diluted into liquid

**Table 1.** Bacterial colonization with *S. aureus* and clinical severity of eczema in treated skin lesions in 21 patients with *S.-aureus*-colonized AE

	Gentian violet 0.3%	Diflu- cortolone	LCD 10%
Patients			
Number	11	5	5
Age, years	28.8 ± 8.6	37.6 ± 14.6	34.6 ± 12.6
<i>S. aureus</i> density, log <sub>10</sub> CFU/cm <sup>2</sup>	5.7 ± 6.0	5.9 ± 6.0	5.5 ± 5.8
Local SCORAD	7.6 ± 2.7	9.0 ± 2.9	6.8 ± 2.3
SCORAD	44.9 ± 18.3	47.9 ± 6.3	41.5 ± 12.0

Results are expressed as means ± SD. LCD = Liquor carbonis detergens.

*S.-aureus*-selective Vogel-Johnson agar and were counted with an impedance technique (DW Rapid Automated Bacterial Impedance technique; MAST Diagnostics, Reinfeld, Germany) [8].

### *In vitro* Suspension Test

1% chlorhexidine, 1% triclosan and 1% Clioquinol were suspended in a vehicle containing 20% ethanol and 1.5% PEG-40-hydrogenated Castor oil. One colony of *S. aureus* was isolated and incubated for 3 h at 30°C in 20 ml of brain-heart infusion medium. 100 µl of bacterial suspension was mixed with 90 µl gentian violet 0.1%, 500 mg diflucortolone and 500 µl LB medium, or 500 µl bacterial suspension was mixed with 500 µl liquor carbonis detergens, chlorhexidine, triclosan and Clioquinol. Vehicles and brain-heart infusion medium served as controls. After 0, 20, 60 and 180 min undiluted and diluted samples were placed on a blood agar medium and incubated at 37°C. The colony number was counted after 48 h.

### Statistical Analysis

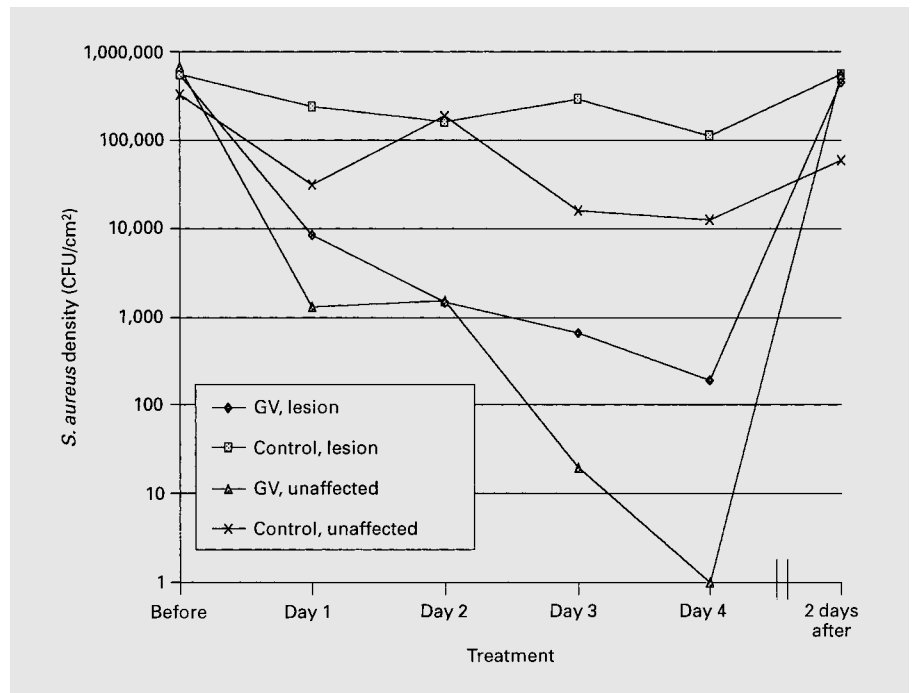
The number of bacterial counts was expressed in log<sub>10</sub> values. Wilcoxon's two-tailed matched-pair signed rank test and Wilcoxon's U test were applied when appropriate. For correlating the density of *S. aureus* with clinical severity, Spearman's correlation coefficient was chosen. A significance level of  $p = 0.05$  was chosen,  $p < 0.01$  was highly significant.

## Results

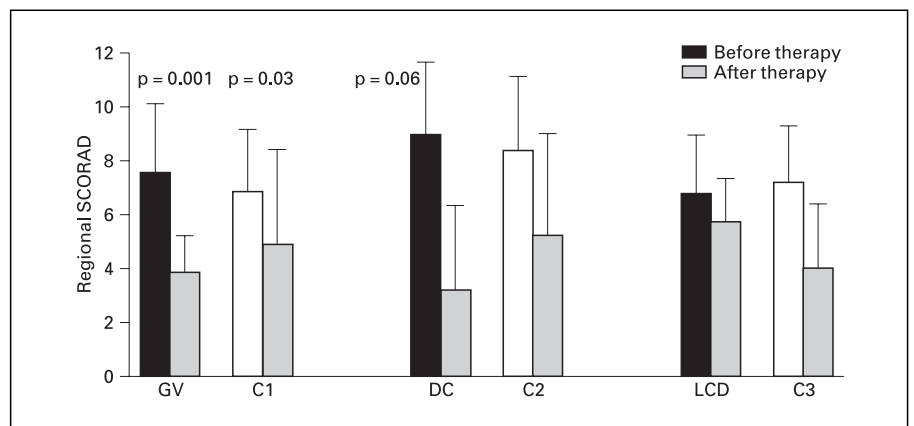
*S. aureus* was isolated from lesional skin in all of the 21 patients with density numbers between  $10^4$  and  $10^{6.5}$  CFU/cm<sup>2</sup> in affected and  $10^0$  to  $10^{6.8}$  CFU/cm<sup>2</sup> in unaffected skin. Mean densities ± SD were  $10^{5.8} \pm 10^{5.9}$  CFU/cm<sup>2</sup> and  $10^{5.5} \pm 10^{6.1}$  CFU/cm<sup>2</sup>, respectively.

The mean initial overall severity ± SD of the eczema graded by SCORAD was  $45 \pm 37$ . Regional severity was assessed to be between 3 and 12, the mean was  $8 \pm 3$  on test

**Fig. 1.** Mean bacterial density of skin *S. aureus* colonization within lesional and unaffected skin during therapy with gentian violet 0.3% (GV) in patients with AE. In gentian-violet-treated lesional or unaffected skin bacterial counts decreased significantly ( $p = 0.001$ ). However, 2 days after therapy skin colonization was nearly as high as before.



**Fig. 2.** Clinical improvement of the skin in patients with AE scored with a regional SCORAD before and after therapy with gentian violet 0.3% (GV), diflucortolone (DC), liquor carbonis detergens 10% (LCD) and corresponding controls (C1–C3). Clinical improvement was higher in diflucortolone- and gentian-violet-treated than in liquor-carbonis-detergens-treated sites compared with control areas.



sites before treatment. Regarding all patients in all test groups before therapy, there was a significant correlation between colonization with *S. aureus* and the regional severity of the disease (correlation coefficient  $r = 0.25$ ;  $p = 0.004$ ). A significant difference regarding the density of *S. aureus* colonization or the clinical severity between patients of groups A–C was not present (table 1).

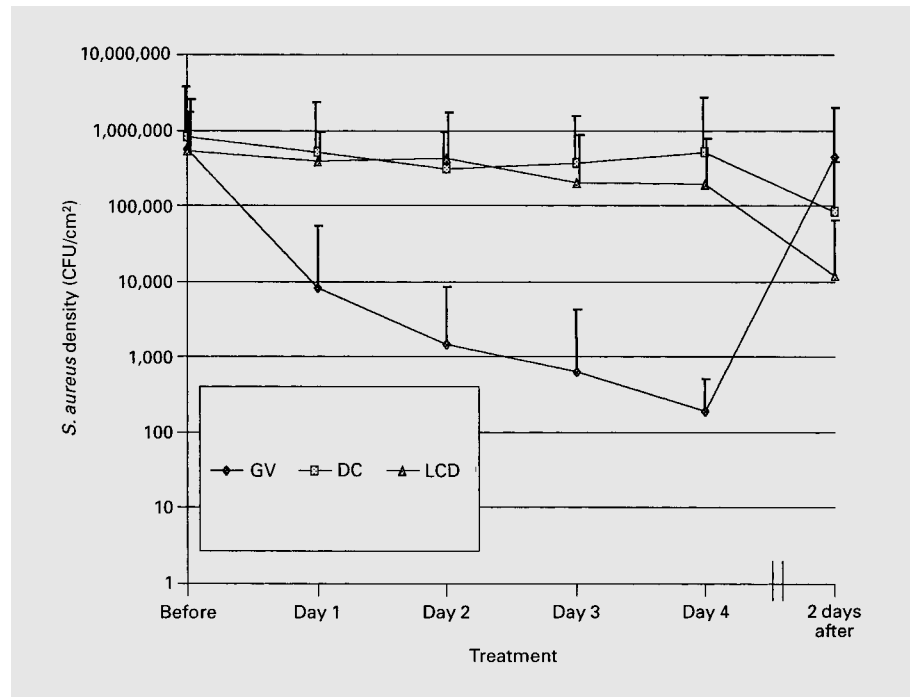
#### Group A

In patients treated with gentian violet, a significant reduction of *S. aureus* density was seen in lesional and unaffected skin ( $p < 0.001$ ) after 4 days (fig. 1). The difference to control areas was highly significant ( $p = 0.002$ ). Density

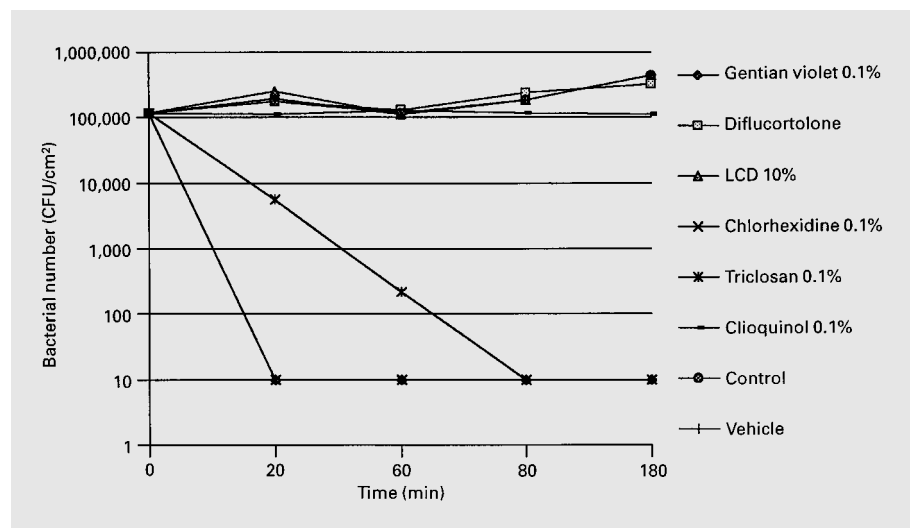
decreased from  $10^{5.7} \pm 10^{6.0}$  to  $10^{2.3} \pm 10^{2.8}$  CFU/cm<sup>2</sup> in affected and from  $10^{5.8} \pm 10^{5.3}$  to  $10^1 \pm 10^0$  CFU/cm<sup>2</sup> in unaffected skin (fig. 1). The steepest decline was noted after the first day of treatment, but *S. aureus* counts continued to decrease during the 4 days of therapy. However, 3 days thereafter *S. aureus* density numbers were nearly as high as before ( $10^{5.7} \pm 10^{5.9}$  CFU/cm<sup>2</sup> in treated areas). No differences in the kinetics of bacterial colonization were observed between densities of affected and unaffected skin.

Reduction of the local SCORAD in group A was highly significant for skin lesions ( $p = 0.001$ ). Mean scores decreased from  $7.6 \pm 2.7$  to  $3.9 \pm 1.5$ . However, a modest but significant improvement was also seen in control areas

**Fig. 3.** Mean bacterial density of skin colonization with *S. aureus* in lesional skin during therapy with gentian violet 0.3% (GV), diflucortolone (DC) and liquor carbonis detergens 10% (LCD) in patients with AE. Whereas in gentian-violet-treated skin bacterial counts decreased significantly from day 1 to day 4 of therapy ( $p = 0.001$ ), they remained stable in diflucortolone- and liquor-carbonis-detergens-treated skin and fell slightly after therapy.



**Fig. 4.** Reduction of *S. aureus* after incubation with equivalent suspensions of gentian violet 0.1%, diflucortolone, liquor carbonis detergens (LCD) 10%, chlorhexidine 0.1%, triclosan 0.1%, Clioquinol 0.1%, brain-heart infusion medium (control) and the vehicle in an in vitro suspension test. Gentian violet and chlorhexidine eliminated *S. aureus* after 20 min and triclosan after 80 min, the other suspensions did not reduce bacterial numbers.



(fig. 2). A reduction of scores from  $6.9 \pm 2.6$  to  $4.9 \pm 3.5$  was noted ( $p = 0.03$ ), which paralleled the improvement of overall SCORAD from  $45 \pm 18.3$  to  $39 \pm 17.2$ .

#### Groups B and C

Figure 3 shows the change of bacterial skin colonization on skin lesions to treatment of patients in groups A–C.

Diflucortolone and tar solution did not significantly reduce the density of *S. aureus* in lesional and unaffected skin during the 4-day treatment period. However, a slight reduc-

tion of *S. aureus* density numbers was noted in lesional skin 3 days after cessation of therapy falling from  $10^{5.9} \pm 10^{6.0}$  to  $10^{4.9} \pm 10^{5.0}$  in group B and from  $10^{5.5} \pm 10^{5.8}$  to  $10^{3.9} \pm 10^{4.3}$  in group C.

In groups B and C a reduction of the local SCORAD was achieved. The clinical response to treatment for patients in group B was excellent with a reduction of severity from  $8 \pm 3.4$  to  $3 \pm 3.1$  ( $p = 0.06$ ) and moderate in group C from  $7.8 \pm 2.9$  to  $5.8 \pm 2.0$  (n.s.). On control sites, a slight but less pronounced clinical improvement was seen, which was not

significant. Overall the SCORAD paralleled these clinical improvements and decreased from  $48 \pm 6.3$  to  $40 \pm 12.2$  in group B and from  $41.5 \pm 12.0$  to  $40.4 \pm 6.7$  in group C.

#### *In vitro* Suspension Tests

Figure 4 shows the results of the suspension test. Incubation with gentian violet and chlorhexidine eliminated *S. aureus* after 20 min, incubation with triclosan after 80 min, whereas there was no significant antibacterial effect of diflu-cortolone, liquor carbonis detergens, Clioquinol and controls.

## Discussion

In the present study, patients suffering from mild to moderate AE colonized with *S. aureus* but without signs of active superinfection were investigated. In these patients excoriations and oozing were not a predominant feature. However, when analyzed before therapy in all test groups together, even in these patients *S. aureus* densities were correlated with the severity of the eczema. Gentian violet showed a potent anti-*S. aureus* efficacy in vivo and together with chlorhexidine had the highest efficacy of all tested antiseptics in vitro. A substantial reduction of *S. aureus* numbers was achieved immediately after initiation of therapy. However, the efficacy was limited to the time of application; already 3 days after cessation of therapy *S. aureus* numbers were as high as before treatment. In gentian-violet-treated patients the reduction of *S. aureus* density was paralleled by a reduction of clinical severity. The mechanism of gentian violet efficacy for the clinical improvement in atopic eczema in vivo is not fully elucidated. Whereas an indirect effect with reduction of bacterial adherence to the atopic corneocytes, e.g. by changes of keratinization, seems also to be possible on theoretical grounds, the most likely and most intensively studied mechanism is through its direct antibacterial efficacy [9, 10]. Similar clinical results were observed in the study from Lever et al. [11], who could demonstrate an antibacterial and clinical effect of the topical antibiotic mupirocin.

In the therapy of superinfected AE topical disinfectants or antibiotics are often added to glucocorticosteroids [12]. In the last decades its value has been discussed controversially. After Marples et al. [13] had shown a superior effect of an antibiotic-steroid combination in comparison to steroid application in experimentally induced human skin infections, this finding was confirmed by a number of clinical trials [14–18]. However, more recently, other studies applying potent glucocorticosteroids were not able to show a significant benefit of combining steroids with antibiotics or antiseptics [19–21].

In patients treated with topical glucocorticosteroids or tar solution a decrease in clinical severity without a reduction of *S. aureus* density numbers was achieved during the active treatment period. This is in accordance with in vitro findings showing no reduction of bacterial counts. Antibacterial efficacy may not be the primary causative mechanism for the clinical improvement seen after treatment. Interestingly, a reduction of *S. aureus* density was demonstrated between cessation of active treatment and 3 days thereafter. This indicates that the reduction of *S. aureus* is probably a secondary phenomenon, possibly being due to less favorable skin conditions for colonization. It could also explain why in studies, in which potent topical glucocorticosteroids were applied for a period of 7 days or longer, a significant reduction of *S. aureus* was demonstrated that was not substantially increased by combining the steroid with an antibiotic [19, 20]. However, data about the kinetics of antibacterial and clinical efficacy are lacking in these studies.

During therapy an overall improvement of atopic eczema was also observed in most patients, which was probably due to a placebo effect rather than to the therapy of the test sites alone. This and the limited number of patients, especially in groups 2 and 3, may have concealed significant clinical differences.

In comparison to antibiotics, antiseptics have a much lower rate of contact sensitivity and much less risk of bacterial resistance. Even though the toxicity of dyes in higher concentrations (1%) and the unfavorable cosmetic appearance have to be considered, in clinical practice antiseptic treatment of patients with superinfected AE is widely used. We apply gentian violet in concentrations which are nontoxic in vivo (0.3% on skin and 0.1% on intertriginous areas and mucous membranes), preferentially in combination with topical glucocorticosteroids. The results of this study are in accordance with our observation that a faster clearance of AE is achieved, when gentian violet is added. The results could indicate that by combining topical glucocorticosteroids with antiseptics an identical clinical efficacy may be achieved by using steroids of lesser potency and fewer side effects.

In conclusion, gentian violet reduces colonization with *S. aureus* as well as clinical severity in patients with *S. aureus*-colonized AE. The causative mechanism for the clinical efficacy of gentian violet may be its antibacterial efficacy. Topical therapy with antiseptics may be a useful tool in the treatment of AE colonized with *S. aureus*. It exerts an anti-inflammatory activity and may be used alone or in combination with glucocorticosteroids. The reduction of *S. aureus* density after treatment with topical glucocorticosteroids or tar solution is probably secondary to the improvement of the skin condition.

## References

- 1 Abeck D, Ruzicka T: Bacteria and atopic eczema: Merely association or etiologic factor? in Ruzicka T, Ring J, Przybilla B (eds): Handbook of Atopic Eczema. Heidelberg, Springer, 1991, pp 212–220.
- 2 Williams REA, Gibson AG, Aitchison TC, Lever R, Mackie RM: Assessment of a contact-plate sampling technique and subsequent bacterial studies in atopic eczema. *Br J Dermatol* 1990;123:493–501.
- 3 Ring J, Abeck D, Neuber K: Atopic eczema: Role of microorganisms on the skin surface. *Allergy* 1992;47:265–269.
- 4 David TJ, Cambridge GC: Bacterial infection and atopic eczema. *Arch Dis Child* 1986;61:20–23.
- 5 Niedner R, Pfister-Wartha A: Farbstoffe in der Dermatologie. *Akt Dermatol* 1990;16:255–261.
- 6 European Task Force on Atopic Dermatitis: Severity scoring of atopic dermatitis: The SCORAD index. *Dermatology* 1993;186:23–31.
- 7 Williamson P, Kligman AM: A new method for quantitative investigation of cutaneous bacteria. *J Invest Dermatol* 1965;45:498–503.
- 8 Brockow K, Grabenhorst P, Traupe B, Ring J, Hoppe U, Abeck D, Wolf F: A rapid impedimetric procedure for quantification of staphylococcal skin colonisation in atopic eczema. *J Invest Dermatol* 1998;110:668.
- 9 Bible DJ, Aly R, Shinefield HR, Maibach HI, Strauss WG: Importance of the keratinized epithelial cell in bacterial adherence. *J Invest Dermatol* 1982;79:250–253.
- 10 Bakker P, Van Doorne H, Gooskens V, Wieringa NF: Activity of gentian violet and brilliant green against some microorganisms associated with skin infections. *Int J Dermatol* 1992;31:210–213.
- 11 Lever R, Hadley K, Downey D, Mackie R: Staphylococcal colonization in atopic dermatitis and the effect of topical mupirocin therapy. *Br J Dermatol* 1988;119:189–198.
- 12 Ring J, Brockow K, Abeck D: The concept of patient management in atopic eczema. *Allergy* 1996;51:206–213.
- 13 Marples RR, Rebora A, Kligman AM: Topical steroid-antibiotic combinations: Assay of use in experimentally induced human infections. *Arch Dermatol* 1973;108:237–240.
- 14 Leyden JJ, Kligman AM: The case for steroid-antibiotic combinations. *Br J Dermatol* 1977;96:179–187.
- 15 Gehring W, Forssmann T, Gloor M: Die keim-reduzierende Wirkung von Erythromycin und Triclosan bei der atopischen Dermatitis. *Akt Dermatol* 1996;22:28–31.
- 16 Lloyd KM: The value of neomycin in topical corticosteroid preparations. *South Med J* 1969;62:94–96.
- 17 Clark RF: The case for corticosteroid-antibiotic combinations. *Cutis* 1974;14:737–741.
- 18 Wachs GN, Maibach HI: Co-operative double-blind trial of an antibiotic corticoid combination in impetiginized atopic dermatitis. *Br J Dermatol* 1976;95:323–328.
- 19 Nilsson EJ, Henning CG, Magnusson J: Topical corticosteroids and *Staphylococcus aureus* in atopic dermatitis. *J Am Acad Dermatol* 1992;27:29–34.
- 20 Korting HC, Zienicke H, Braun-Falco O, Bork K, Milbradt R, Nolting S, Schopf E, Tronnier H: Modern topical glucocorticosteroids and anti-infectives for superinfected atopic eczema: Do prednicarbate and didecyltrimethylammoniumchloride form a rational combination? *Infection* 1994;22:390–394.
- 21 Davies CM, Fulghum DD, Taplin D: The value of neomycin in a neomycin-steroid cream. *JAMA* 1968;203:136–138.