

Infected Necrosis in Severe Pancreatitis – Combined Nonsurgical Multi-Drainage with Directed Transabdominal High-Volume Lavage in Critically Ill Patients

V. Becker^a W. Huber^a A. Meining^a C. Prinz^a A. Umgelter^a L. Ludwig^a M. Bajbouj^a
J. Gaa^b R.M. Schmid^a

^aSecond Medical Department, and ^bInstitute of Radiology, Klinikum rechts der Isar, University of Munich, Munich, Germany

Key Words

Infected pancreatic necrosis · Minimally invasive percutaneous/endoscopic approach · Endoscopic drainage · High-volume lavage

Abstract

Background: Infection of pancreatic necrosis is a life-threatening complication during the course of acute pancreatitis. In critically ill patients, surgical or extended endoscopic interventions are associated with high morbidity and mortality. Minimally invasive procedures on the other hand are often insufficient in patients suffering from large necrotic areas containing solid or purulent material. We present a strategy combining percutaneous and transgastric drainage with continuous high-volume lavage for treatment of extended necroses and liquid collections in a series of patients with severe acute pancreatitis. **Patients and Methods:** Seven consecutive patients with severe acute pancreatitis and large confluent infected pancreatic necrosis were enrolled. In all cases, the first therapeutic procedure was placement of a CT-guided drainage catheter into the fluid collection surrounding peripancreatic necrosis. Thereafter, a second en-

dosonographically guided drainage was inserted via the gastric or the duodenal wall. After communication between the separate drains had been proven, an external to internal directed high-volume lavage with a daily volume of 500 ml up to 2,000 ml was started. **Results:** In all patients, pancreatic necrosis/liquid collections could be resolved completely by the presented regime. No patient died in the course of our study. After initiation of the directed high-volume lavage, there was a significant clinical improvement in all patients. Double drainage was performed for a median of 101 days, high-volume lavage for a median of 41 days. Several endoscopic interventions for stent replacement were required (median 8). Complications such as bleeding or perforation could be managed endoscopically, and no subsequent surgical therapy was necessary. All patients could be dismissed from the hospital after a median duration of 78 days. **Conclusion:** This approach of combined percutaneous/endoscopic drainage with high-volume lavage shows promising results in critically ill patients with extended infected pancreatic necrosis and high risk of surgical intervention. Neither surgical nor endoscopic necrosectomy was necessary in any of our patients.

Copyright © 2009 S. Karger AG, Basel and IAP

Introduction

Among patients with acute pancreatitis, up to 15% will have a severe course of the disease. Severe acute pancreatitis (SAP) is still associated with a significant morbidity and mortality ranging from 10–42% [1]. The early phase of acute pancreatitis is characterized by an inappropriate activation of pancreatic enzymes inside the organ. In severe cases, destruction of pancreatic tissue is parallel to local inflammation which progresses to a systemic inflammatory response syndrome, often with multi organ failure [1]. A second peak of the disease is predominantly caused by infectious complications, namely infection of necrosis [2]. As classified by the International Symposium on Acute Pancreatitis in Atlanta, on contrast-enhanced CT, the necrotic pancreatic tissue presents as diffuse or focal area with decreased or missing contrast enhancement compared to normal pancreatic parenchyma [3]. Necrosis may extend far beyond the margins of the pancreas. Infection of the necrotic tissue should be considered in case of fever $\geq 38.5^{\circ}\text{C}$, leukocytosis, increasing plasma C-reactive protein (CRP) or rapid clinical deterioration. Signs of gas inclusion in pancreatic or extrapancreatic necrosis are highly suspicious for infection [4].

In general, treatment of necrotizing disease is based on removal of the necroses and prophylactic antibiotic therapy. Nevertheless, particularly in necrotizing pancreatitis, the benefit of surgery as well as antibiotics is matter of an ongoing debate [5, 6]. Concerning antibiotics, the two largest and recent studies failed to demonstrate significant benefits [2, 7]. However, this might be due to the limited number of patients with severe pancreatitis as well as inter-current antibiotics in the 'placebo' group due to other indications than necrotizing pancreatitis. Unexpectedly, the infectious potential of necroses was underlined by the results of a recent trial on probiotics in necrotizing pancreatitis [8]. This underlines the importance of sufficient and fast removal of necrotic tissue.

The aim of all therapeutic strategies in infected pancreatic necrosis is to remove necrotic material and surrounding fluid collections. This leads to a decrease in concentration of digestive enzymes, proinflammatory mediators and endotoxins, and thereby stops the progress of infection [9]. Surgical strategies have combined necrosectomy with extensive continuous or repeated lavage [10–12]. However, due to the operative stress in critically ill patients, surgical approaches have been associated with high morbidity and mortality (20–30%). Furthermore, about two thirds of patients developed long-term complications, making repeated laparotomies necessary (17–71%) [13–

17]. For that reason, treatment of infected pancreatic necrosis has progressively been shifted from surgical to non-surgical strategies, particularly in sterile necroses [5]. Whereas there are few data on nonsurgical management of infected necroses, these approaches normally apply different numbers of percutaneous and endoscopic drainages (percutaneous, transgastric, transduodenal, transpapillary), mostly in combination with repeated irrigations or endoscopic necrosectomies. Single endoscopic procedures are often insufficient in treatment of huge necrotic areas containing large amounts of solid or purulent necrotic material [18–20]. In these cases, repeated necrosectomies with the risk of losing vital pancreatic tissue and of causing severe bleedings are required [21].

To overcome this problem, we aimed to combine a strategy of continuous directed high-volume lavage from external percutaneous to internal transgastric drainages to resolve necrotic material and limit local infection in critically ill patients with SAP and infected pancreatic necrosis. In this case series, we report on feasibility and outcome of this concept in critically ill patients with extended pancreatic necroses and fluid collections.

After initial experience in 3 patients, a consensus on future management of patients with extended necroses accessible to both radiologic as well as endoscopic drainage was established.

Patients and Methods

In a time period of 31 months, 7 consecutive patients (3 women, 4 men) with SAP and infected pancreatic necrosis were analyzed. The etiologies of pancreatitis were the following: biliary in 5 patients, alcoholic in 1 patient and idiopathic in 1 patient. Patient demographics, duration of drainage therapy, complications and outcome are shown in tables 1 and 2. All patients were critically ill (median APACHE II score: 11), had extensive necrosis and high risk towards surgical intervention.

Therapy Regime

In the first few days of acute pancreatitis, all patients were treated with high-volume fluid resuscitation and intravenous analgetics. No prophylactic antibiotics were used. Subsequently, in case of fever $\geq 38.5^{\circ}\text{C}$, rapidly increasing leukocytosis, plasma CRP or clinical deterioration, antibiotic treatment with imipenem was started and abdominal contrast-enhanced CT was performed. If necrosis was revealed, a CT-guided drainage catheter (12F; Boston Scientific International, Natick, Mass., USA) was placed in the same session (fig. 1–3). 'Low-volume' irrigation was started with 40 ml saline solution every 4 h. Additionally, within the next days, an endosonographically guided drainage was inserted through the gastric or the duodenal wall. Endoscopic ultrasound was used to define the optimal puncture position and to exclude vessel interposition. Therefore, a curvilinear echoendoscope (Olympus,

Table 1. Patient demographics and therapy regime

Case/gender	Age, years	Etiology	Drainage	Duration of double drainage, days	Complications	Maximum lavage, ml/day	Endoscopic procedures	Hospitalization, days	Outcome
1/M	66	biliary	transduodenal	150	perforation duodenum	500	16	150	completely resolved
2/F	55	biliary	transgastric	154		500	14	89	completely resolved
3/M	75	other	transduodenal	8		500	7	45	completely resolved
4/M	73	biliary	transgastric	75	colonic fistula	1,500	16	61	completely resolved
5/F	84	biliary	transduodenal	125	bleeding	1,500	14	54	completely resolved
6/M	42	alcoholic	transgastric	65	retroperitoneal fistula	2,000	21	74	completely resolved
7/F	35	biliary	transgastric	132		2,000	16	74	recurrent pseudocysts

Table 2. Patient data

Case	Extent of pancreatic necrosis, mm	Days from onset of symptoms to intervention	Bacteriology	CRP at the time of intervention, mg/dl	APACHE II score
1	120 × 55	18	<i>Klebsiella pneumoniae</i>	33	19
2	100 × 50	24	<i>Enterococcus faecium</i>	28	12
3	86 × 52	30	<i>Escherichia coli</i>	30	8
4	80 × 60	28	<i>Enterococcus faecium</i>	29	8
5	130 × 80	21	<i>Pseudomonas aeruginosa</i>	34	10
6	90 × 80	27	<i>Klebsiella pneumoniae</i>	28	10
7	80 × 50	20	<i>Escherichia coli</i>	36	11

Hamburg, Germany) and a puncture system (Boston Scientific International) were used. The necrotic areas with surrounding fluid collections were punctured with a 22-gauge needle. Liquefied material or pus were aspired for bacteriologic examination and resistance testing. Using the puncture device, one or two 7 F pigtail catheters were placed. Contrast medium was injected to evaluate extension of the cavity and to prove continuity of the necrotic cavity between the transcutaneous and internal drainages. If communication of fluids between the drains could be demonstrated, high-volume lavage irrigation from the percutaneous to the endoscopically placed catheter with a daily volume of 500 ml up to 2,000 ml was started (table 1) avoiding infusion pumps by using a gravity-driven infusion (40 cm H₂O above symphysis).

Declining size of the cavity as well as significant clinical improvement were used as parameters for drain removal. First, the percutaneous drainage was removed. Four of 7 patients were dismissed from the hospital with the transgastric/transduodenal drainage in situ. All patients were monitored in short intervals by clinical presentation, ultrasound examination and laboratory tests. The transgastric/transduodenal drainages were removed after a complete resolution of the necrotic area.

Results

In all patients, percutaneous as well as transgastric/transduodenal drainages could be applied without any complications during endoscopic procedures. In 4 patients, a transgastric drainage was placed. Three patients received transduodenal pigtail catheters.

In each patient, fluid collections containing large amounts of solid necrotic material and pus were evacuated after insertion of the CT-guided percutaneous drainage. Prior to intervention in 2 of 7 patients, presence of bacteria (*Escherichia coli*, *Enterococcus faecium*) was proven in the blood during ongoing therapy with imipenem. In the effluates, bacteria were detected in all 7 patients (table 2). Antibiotic therapy was adjusted according to resistance testing. With the 'low-volume' lavage of 40 ml saline every 4 h, the effluates remained viscous containing large amounts of solid necrotic material and pus.

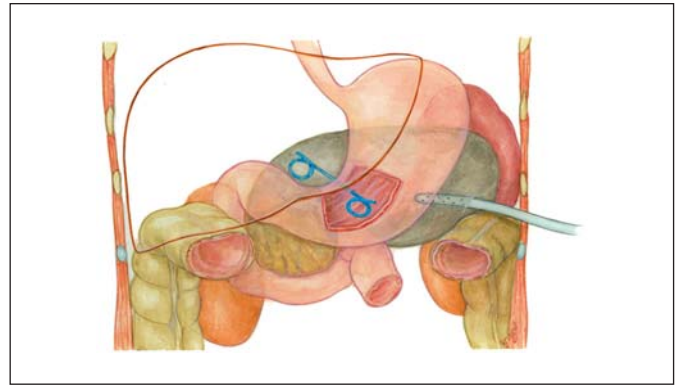
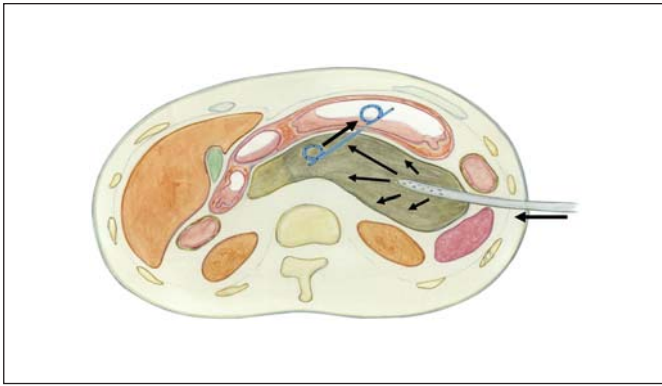


Fig. 1. Schematic illustration of combined percutaneous and transgastric drainage regime.

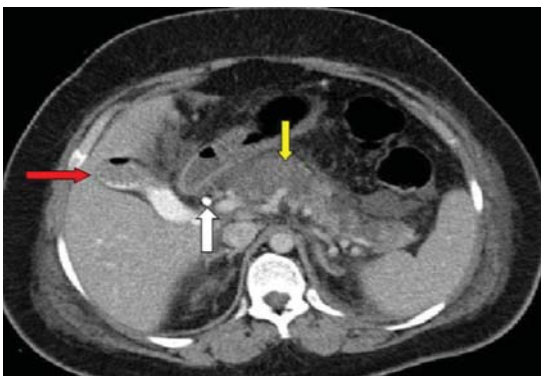

Fig. 2. CT scan before intervention with infected pancreatic necrosis (yellow arrow) after biliary stent placement (white arrow). Red arrow shows multiple gallstones and air in lumen of gallbladder.

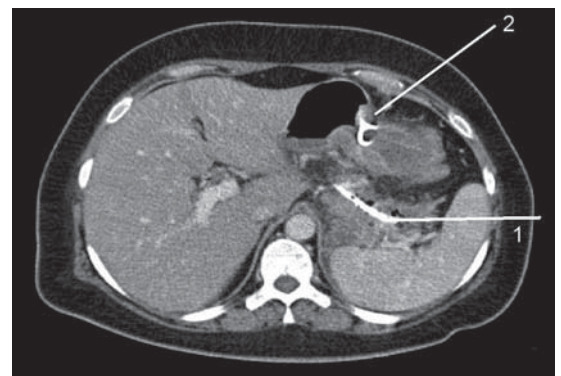


Fig. 3. CT scan with percutaneous (1) and transgastric (2) drainage. High-volume lavage was directed from the percutaneous to the endoscopically placed catheter.

After endoscopic ultrasound-guided transgastric/transduodenal drainage, a directed high-volume lavage from the percutaneous drainage to the internal drainage was started with a daily amount of 500–2,000 ml. After initiation of the directed high-volume lavage, there was a significant improvement with respect to clinical condition and infective parameters in all patients (fig. 4).

During drainage therapy, episodes of fever and drain occlusions or dislocations occurred. Therefore, several endoscopic interventions for drainage replacement were required. The median number of reinterventions was 8 (table 1). In 1 patient, a spontaneous duodenal perforation occurred (patient 1), 1 patient developed a pancreatico-colonic fistula (patient 4), a 3rd patient developed a fistula to the retroperitoneal space (patient 6). A spontaneous gastric bleeding occurred in patient 5. However, all

complications could be managed endoscopically. Infections during drainage therapy were treated according to the results of microbiological testing acquired from the effluate. Fistulas had spontaneous closure and no recurrence was observed during follow-up. No subsequent surgical therapy was necessary. High-volume lavage did not affect any clinical complications such as profuse diarrhea. During the stay on intensive care unit, patients received total parenteral nutrition. Enteral feeding using a nasogastric tube was started with clinical improvement. Temporarily, both methods parenteral nutrition as well as nasojejunal feeding were necessary.

The median duration of high-volume lavage was of 41 days, the duration of double drainage 101 days. All patients could be dismissed from the hospital after a median duration of 78 days. If necessary, drainage therapy was contin-

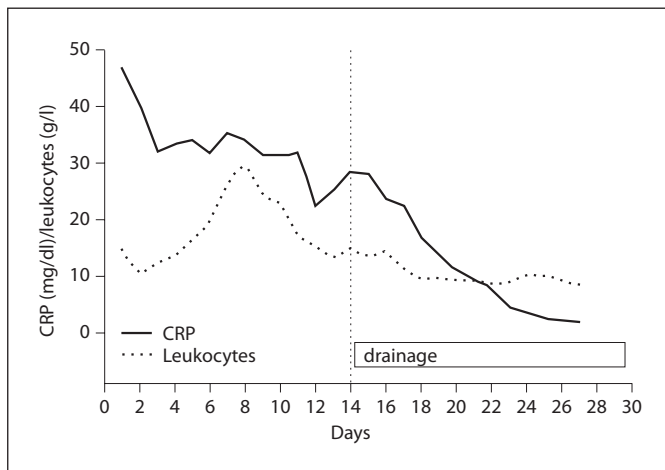


Fig. 4. Representative decline of infective parameters (patient 6) after directed high-volume lavage from the percutaneous drainage to the internal drainage was started (CRP: normal value <0.5 mg/dl).

ued in an outpatient regime. Subsequently, the patients were monitored in short intervals for clinical presentation, ultrasound examination and laboratory tests. In all patients, a complete remission of all visible abscess cavities was achieved. All drains were removed endoscopically. At a minimum follow-up of 10 months, all patients showed a complete resolution of the necrotic areas. One patient (patient 7) suffered from recurrent pancreatic pseudocysts, which were drained endoscopically. Two of the 7 patients developed exocrine insufficiency with diarrhea. Pancreatic enzyme replacement therapy was started.

Discussion

Here, we present a regimen of percutaneous CT-guided and transgastric/transduodenal drainage combined with directed continuous high-volume lavage in critically ill patients with severe necrotizing pancreatitis and high risk of surgical intervention.

The main issues concerning treatment of infected pancreatic necrosis are removal of solid infected necrotic material as well as fluid collections and a consistent reduction in concentration of digestive enzymes, pro-inflammatory mediators and endotoxins to facilitate healing and granulation. Surgical approaches require large abdominal incisions for open necrosectomy. This is followed by insertion of multiple external drainage catheters. These large catheters enable effective continuous

high-volume lavage to remove residual necrotic tissue and infected debris [10]. The benefit of continuous high-volume lavage in this context is generally accepted [10]. However, due to high peri- and postoperative stress of open necrosectomy, surgical approaches are associated with high morbidity and mortality in critically ill patients ranging between 15 and 30% [16].

The rationale of percutaneous/endoscopic procedures is to minimize the peri- and postoperative stress in critically ill patients. Therefore, less invasive surgical techniques such as minimal access surgery have been developed. The results of these approaches, with a lower incidence of postoperative organ failure when compared with open surgery, are encouraging [22]. However, strategies avoiding surgery by using only drainage catheters and repeated irrigations often fail in completely resolving infected necrotic and purulent material. Thus, in most endoscopic series, repeated necrosectomies or delayed surgical debridement were necessary [21, 23]. For endoscopic necrosectomy, complex and time-consuming techniques with large stoma for retroperitoneal endoscopy via transgastric fenestration, or aggressive daily endoscopic necrosectomies after balloon dilatation are applied [20, 21, 23]. However, large stoma are a risk for bleeding, free perforation, fistulas or embolism due to the presence of eroded vessels. Furthermore, surgical or endoscopic necrosectomies are 'local procedures' and therefore limited in spatial extension. So, in many cases, large areas of necrotic material as well as huge fluid collections cannot be resolved completely.

The aim of the presented strategy was to combine the effectiveness of continuous high-volume lavage used in surgical procedures with the minimally invasive percutaneous/endoscopic approach. Our data suggest that high-volume lavage, which follows the surgical concept, can efficiently reduce the concentration of digestive enzymes and proinflammatory mediators. High-volume lavage can also physically remove solid necrotic material due to the continuous outflow of the remaining necrotic tissue. Furthermore, high-volume lavage is not limited to local cavities. In all patients presented here, pancreatic necrosis and fluid collections could be resolved completely by directed high-volume lavage, and no additional necrosectomy or delayed surgery was required. This suggests that high-volume lavage can be used as a 'non-invasive necrosectomy' in critically ill patients with infected pancreatic necrosis and huge fluid collections. The benefit of this approach is highest in patients with severe disease and multiple organ failure, because in these patients minimizing peri- and postoperative stress is essen-

tial. This might be the reason for the reduced mortality in comparison to the surgical management.

One might argue that large amounts of intra-abdominal lavage fluid might spread infection, increase fluid collections or raise intra-abdominal pressure. To minimize these risks, we limited the perfusion pressure to 40-cm water column. High-volume lavage was monitored closely and stopped immediately in case of drain occlusion or increase in fluid collections. No episodes of fever were assessed after initiation of lavage. Because of the long treatment period, detailed evaluation of the effectiveness and benefit of high-volume lavage is difficult and reliable parameters are missing. Therefore, one might use the concentration of digestive enzymes, e.g. lipase concentration in the effluate. Lipase concentration was monitored. During lavage, lipase concentration was reduced more than a hundredfold. However, due to the small number of patients, the clinical relevance of this specific issue remains unanswered. In future studies, monitoring of pro-inflammatory cytokines like IL-1, IL-6, IL-8 and TNF- α , which are involved in the pathogenesis of acute pancreatitis and its systemic complications, might help to answer this question.

The disadvantage of the presented strategy is the high number of endoscopic procedures as well as the long duration of overall treatment. The solid necrotic material is a substantial risk for drainage occlusion. Therefore, in order to sustain continuous lavage, repeated endoscopic procedures to readjust or replace occluded drainages are required. However, the use of percutaneous guided drainage is safe and generally accepted in the therapy of pan-

creatic pseudocysts. Endosonography allows a precise transgastric/duodenal drainage placement with a low risk of endoscopy-associated complications [21]. The long duration of hospitalization results from the critical medical condition in all patients and is according to previous reports of patients with SAP. Two of the 7 patients developed long-term complications, namely exocrine pancreatic insufficiency, which is in accordance with previous studies [14]. Despite the promising results in this series, it should be stressed that treatment of infected pancreatic necrosis is still complex and should be performed in specialized centers. However, to prove the benefit and cost effectiveness of the presented approach, a higher number of patients is needed.

Taken together, the presented strategy combines continuous high-volume lavage used in surgical procedures with a minimally invasive percutaneous/endoscopic approach in critically ill patients with SAP and infected necrosis. We estimate that high-volume lavage is able to remove solid necrotic material without limitation to local cavities. Thereby, concentration of digestive enzymes, proinflammatory mediators and endotoxins can be reduced and progress of infection can be stopped. The disadvantage of this approach is the high number of endoscopic procedures and the long duration of hospitalization. However, this is balanced by avoiding surgery with high operative stress and long-term complications. All 7 patients had a complete resolution of the necrotic area. The benefit and cost effectiveness of this approach have to be proven in a higher number of patients.

References

- 1 McKay CJ, Imrie CW: The continuing challenge of early mortality in acute pancreatitis. *Br J Surg* 2004;91:1243–1244.
- 2 Isenmann R, Rau B, Beger HG: Bacterial infection and extent of necrosis are determinants of organ failure in patients with acute necrotizing pancreatitis. *Br J Surg* 1999;86:1020–1024.
- 3 Bradley EL: A clinically based classification system for acute pancreatitis. *Arch Surg* 1993;128:586–590.
- 4 Whitcomb DC: Acute pancreatitis. *N Engl J Med* 2006;354:2142–2150.
- 5 Nathens AB, Curtis JR, Beale RJ, et al: Management of the critically ill patient with severe acute pancreatitis. *Crit Care Med* 2004;32:2524–2536.
- 6 Nordback I, Sand J, Saaristo R, Paajanen H: Early treatment with antibiotics reduces the need for surgery in acute necrotizing pancreatitis – a single-center randomized study. *J Gastrointest Surg* 2001;5:113–120.
- 7 Dellinger EP, Tellado JM, Soto NE, et al: Early antibiotic treatment for severe acute necrotizing pancreatitis: a randomized, double-blind, placebo-controlled study. *Ann Surg* 2007;245:674–683.
- 8 Sand J, Nordback I: Probiotics in severe acute pancreatitis. *Lancet* 2008;371:634–635.
- 9 Bradley EL 3rd: Management of infected pancreatic necrosis by open drainage. *Ann Surg* 1987;206:542–550.
- 10 Beger HG, Buchler M, Bittner R, et al: Necrosectomy and postoperative local lavage in patients with necrotizing pancreatitis: results of a prospective clinical trial. *World J Surg* 1988;12:255–262.
- 11 Sarr MG, Nagorney DM, Mucha P Jr, et al: Acute necrotizing pancreatitis: management by planned, staged pancreatic necrosectomy/debridement and delayed primary wound closure over drains. *Br J Surg* 1991;78:576–581.
- 12 Tsiotos GG, Luque-de Leon E, Soreide JA, et al: Management of necrotizing pancreatitis by repeated operative necrosectomy using a zipper technique. *Am J Surg* 1998;175:91–98.
- 13 Tzovaras G, Parks R, Diamond T, Rowlands B: Early and long-term results of surgery for severe necrotizing pancreatitis. *Dig Surg* 2004;21:41–46.

- 14 Connor S, Alexakis N, Raraty M, Ghaneh P, Evans J, Hughes M, Garvey CJ, Sutton R, Neoptolemos JP: Early and late complications following pancreatic necrosectomy. *Surgery* 2005;137:499–505.
- 15 Fernandez-del Castillo C, Rattner DW, Makary MA, et al: Debridement and closed packing for the treatment of necrotizing pancreatitis. *Ann Surg* 1998;228:676–684.
- 16 Hartwig W, Werner J, Muller CA, et al: Surgical management of severe pancreatitis including sterile necrosis. *J Hepatobiliary Pancreat Surg* 2002;9:429–435.
- 17 Werner J, Hartwig W, Hackert T, et al: Surgery in the treatment of acute pancreatitis-open pancreatic necrosectomy. *Scand J Surg* 2005;94:130–134.
- 18 Branum G, Galloway J, Hirchowitz W, et al: Pancreatic necrosis: results of necrosectomy, packing, and ultimate closure over drains. *Ann Surg* 1998;227:870–877.
- 19 Baron TH, Thaggard WG, Morgan DE, et al: Endoscopic therapy for organized pancreatic necrosis. *Gastroenterology* 1996;111:755–764.
- 20 Seifert H, Webrmann T, Schmitt T, et al: Retroperitoneal endoscopic debridement for infected peripancreatic necrosis. *Lancet* 2000;356:653–655.
- 21 Seewald S, Groth S, Omar S, et al: Aggressive endoscopic therapy for pancreatic necrosis and pancreatic abscess: a new safe and effective treatment algorithm. *Gastrointest Endosc* 2005;62:92–100.
- 22 Connor S, Raraty GT, Howes N: Surgery in the treatment of acute pancreatitis – minimal access pancreatic necrosectomy. *Scand J Surg* 2005;94:135–142.
- 23 Seifert H, Dietrich C, Schmitt T, et al: Endoscopic ultrasound-guided one-step transmural drainage of cystic abdominal lesions with a large-channel echo endoscope. *Endoscopy* 2000;32:255–259.