

# Silver-Coated Textiles Reduce *Staphylococcus aureus* Colonization in Patients with Atopic Eczema

Anke Gauger<sup>a</sup> Martin Mempel<sup>a</sup> Annika Schekatz<sup>a</sup> Torsten Schäfer<sup>b</sup>  
Johannes Ring<sup>a</sup> Dietrich Abeck<sup>a</sup>

<sup>a</sup>Department of Dermatology and Allergy, Biederstein, Technical University, Munich, and

<sup>b</sup>Department of Social Medicine, University of Lübeck, Germany

## Key Words

*Staphylococcus aureus* · Silver ions · Antibacterial effect · Atopic eczema · Skin barrier · Textiles

## Abstract

**Background:** In atopic eczema (AE), skin colonization with *Staphylococcus aureus* is known to play a major triggering and possibly pathophysiological role. **Methods:** In this open-labeled controlled side-to-side comparative trial, affected sites (flexures of both elbows) in 15 patients diagnosed as having generalized or localized AE were evaluated regarding *S. aureus* colonization and clinical severity of AE over a 2-week period. Flexures of the elbows were covered with silver-coated textiles on one arm and cotton on the other for 7 days followed by a 7-day control period. **Results:** A highly significant decrease in *S. aureus* colonization could be seen on the site covered by the silver-coated textile already 2 days after initiation lasting until the end of the treatment. Seven days after cessation, *S. aureus* density remained significantly lower compared to baseline. In addition, significantly lower numbers of *S. aureus* were observed on the silver-coated textile site in comparison to cotton at the end of treatment as well as at the time point of control. Clinical improvement correlated with the reduction of

*S. aureus* colonization. **Conclusion:** A superior improvement achieved by silver-coated compared to cotton textiles paralleled a potent anti-*S. aureus* effect.

Copyright © 2003 S. Karger AG, Basel

## Introduction

*Staphylococcus aureus* is recognized as an important triggering factor for maintenance of skin inflammation and acute exacerbations of the genetically determined skin disease atopic eczema (AE) [1, 2]. The degree of colonization is associated with disease severity [3–5]. The knowledge of the pathophysiological role of *S. aureus* in AE has increased during the recent years. The organism produces a variety of immunomodulatory toxins with superantigenic properties like the well-characterized staphylococcal enterotoxins A–E as well as the toxic shock syndrome toxin 1 [6]. In addition, *S. aureus* produces a variety of enzymes with direct cell-damaging properties, several hazardous toxins (including hemolysins and exfoliative toxins) as well as elaborate defense mechanisms against the majority of currently used antimicrobial drugs [7–9]. Although there is a controversial discussion about topical glucocorticoid and antibiotic combination, antibiotic as well as antiseptic substances of good antistaphylo-

## KARGER

Fax +41 61 306 12 34  
E-Mail karger@karger.ch  
www.karger.com

© 2003 S. Karger AG, Basel  
1018–8665/03/2071–0015\$19.50/0

Accessible online at:  
www.karger.com/drm

Anke Gauger, MD  
Klinik und Poliklinik für Dermatologie und Allergologie am Biederstein der TU München  
Biedersteiner Strasse 29  
D–80802 Munich (Germany)  
Tel. +49 89 4140 3186, Fax +49 89 4140 3540, E-Mail agauger@gmx.de

coccal activity have been well established and are successfully used for the treatment of AE. By reduction of *S. aureus* density they are able to contribute to the anti-inflammatory effect of topical corticosteroids and emollients [10–13]. Silver products have been under investigation during recent years with special regard to wound-healing processes. They demonstrate two key advantages: they are broad-spectrum antibiotics and are not yet associated with drug resistance [14]. Silver-coated materials are already frequently used, e.g. in surgery (external fixation), urology (catheter) or odontology [15–17]. Podycare® textiles (used in this trial) consist of micromesh material containing woven silver filaments with a silver content of 20% in total. In vitro studies of these silver-coated textiles demonstrated a significant decrease in bacteria (*Staphylococcus aureus* and *Pseudomonas aeruginosa*) as well as *Candida albicans* [18]. The aim of our study was to investigate the influence of silver-coated textiles in patients with AE with special consideration of *S. aureus* colonization.

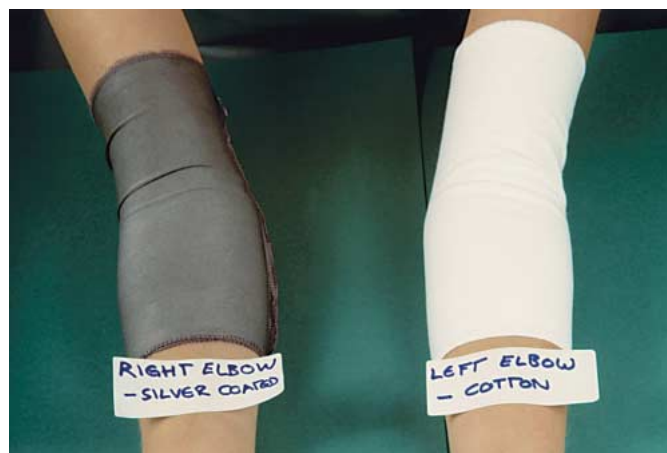## Materials and Methods

### Patients and Clinical Evaluation

Fifteen consecutive outpatients clinically diagnosed as having generalized or localized AE [19] presenting eczematous lesions on the flexures of both elbows were included in the study. All fulfilled the inclusion criteria, i.e. a steroid-free interval of at least 2 weeks and no systemic or topical antibiotic treatment within 4 weeks. The study was performed during the months February and March with low temperatures simplifying compliance during day and night. Local disease severity was assessed using the local SCORAD protocol [20] comprising the following 6 intensity items: erythema (1); edema/papulation (2); oozing/crusts (3); excoriations (4); lichenification (5), and local pruritus (6). Each item was graded on a 4-point scale: 0 = absent, 1 = mild, 2 = moderate, 3 = severe. A total severity score was calculated as the sum of the grading resulting in a highest possible score of 18. Patients were instructed to wear specially designed elbow covers for 7 days and nights in total: the left elbow was covered with pure cotton material, the right elbow with silver-coated material (Podycare; fig. 1). Due to the diversity of the patients, different sizes of elbow covers were used: European size 92–104–128–164 for children, size S(mall), M(edium) and L(arge) for adults. During the 7-day wearing period the same elbow covers – without cleaning – were applied during night and day and removed only while taking a shower. Basic skin care with emollients was allowed, the patients' washing and cleaning behavior was continued as usual. After cessation of the wearing period, a control period of 7 days followed, where no elbow covers were applied. Clinical evaluation using the local SCORAD was performed at baseline (day 0), days 2 and 7 after the onset of wearing elbow covers as well as 7 days thereafter (day 14) for control. The mean age of our patients was 24.6 years (range 3–55 years).

### Microbiological Examinations

Bacterial solutions were collected from the affected sites of both arms at baseline (day 0), days 2 and 7 as well as 7 days thereafter (day



**Fig. 1.** Example of the elbow covers used: silver-coated textile (right elbow flexure) and cotton (left elbow flexure) in a patient with AE.

14) – in accordance with clinical evaluation. A standardized scrub method developed by Williamson and Kligman [3, 21] was used: a Perspex-lined cylinder (contact area of 6,158 cm<sup>2</sup>) was put on the eczematous lesion followed by continuous scrubbing of the surface with 1,000 µl of a standardized washing solution (0.15% Twen/PBS Dulbecco's) for 1 min. The solution was immediately diluted up to level 10<sup>-6</sup> using PBS buffer, and an aliquot of 100 µl was inoculated onto Columbia agar plates containing 5% sheep blood (BioMérieux, Nürtingen, Germany) at 37 °C for 24 h. Identification of *S. aureus* was performed using the Slidex Staph-Kit test (BioMérieux). Positive cultures were further characterized using the api-Staph system (BioMérieux). Colonization of *S. aureus* was quantified by counting the numbers of colony-forming units per agar plate and subsequent calculation of colonies per square centimeter.

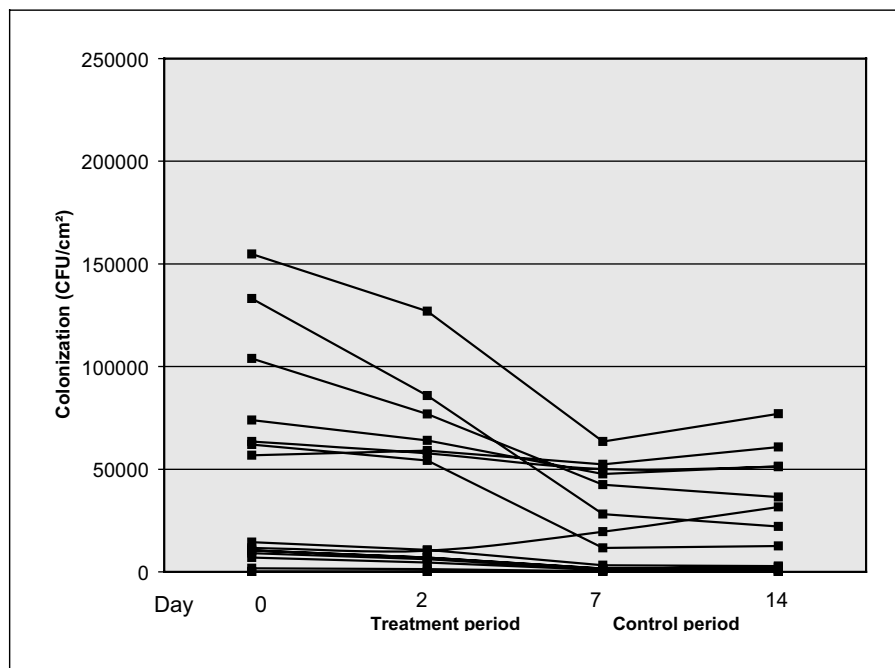
### Statistical Analysis

The Wilcoxon ranked pair test was applied for comparisons of the *S. aureus* colonization (a) on silver-coated sites (right elbow flexure) against cotton sites (left elbow flexure) as well as (b) on one affected site in comparison to baseline at different time points of evaluation. A significance level of  $p = 0.05$  was chosen. Spearman's correlation coefficient was chosen for the overall correlation of the density of *S. aureus* and the clinical severity.

## Results

*S. aureus* was isolated in all of the 15 patients from both sites with density numbers between 10<sup>2.2</sup> and 10<sup>5.2</sup> CFU/cm<sup>2</sup> on the right flexure site and between 10<sup>2.1</sup> and 10<sup>5.1</sup> CFU/cm<sup>2</sup> on the left flexure site of the elbow at initiation. During the treatment period with elbow covers, density numbers ranged between 0 and 10<sup>4.1</sup> CFU/cm<sup>2</sup> on the silver-coated textile site/right flexure site and 10<sup>2.3</sup> and 10<sup>5.3</sup> CFU/cm<sup>2</sup> on the cotton/left flexure site. At the

**Fig. 2.** Bacterial colonization by *S. aureus* of affected sites covered by silver-coated textiles (right elbow flexure) at different time points of evaluation: days 0, 2, 7 and 14. Results of *S. aureus* colonization in all 15 patients are expressed as CFU/cm<sup>2</sup>.



time point of control (day 14), density numbers were between 0 and  $10^{4.9}$  and between  $10^2$  and  $10^{5.1}$  CFU/cm<sup>2</sup>, respectively.

At initiation, the clinical severity of right and left flexure sites of the elbows was comparable: it was assessed between 6 and 15 on the right and 5 and 15 on the left flexure site. During the treatment period, the local severity of eczema ranged between 2 and 13 on the silver-coated textile site/right flexure site and 4 and 14 on the cotton/left flexure site. At control, severity scores were between 2 and 11 and between 4 and 12, respectively.

#### *S. aureus* Colonization

At baseline, no significant difference regarding the density of *S. aureus* colonization could be observed.

After initiation of the trial, a constant decrease in *S. aureus* colonization could be seen on the silver-coated textile site (right elbow flexure). The steepest decline was noted between day 2 and day 7. After termination the density numbers of *S. aureus* remained constant or rose again (a general view of *S. aureus* colonization density numbers in all patients is demonstrated in fig. 2). In contrast, density numbers in *S. aureus* colonization on the cotton site (left elbow flexure) remained nearly constant during the course of time in all 15 patients, 1 patient being an exception with an unsteady course of bacterial colonization (fig. 3).

In the statistical analysis, a highly significant decrease in *S. aureus* colonization could be observed already on day 2 on the silver-coated textile site ( $p = 0.002$ ). Also on day 7 and even at the time point of control (7 days after termination), *S. aureus* density numbers remained highly significantly ( $p = 0.002$  and  $p = 0.008$ , respectively) reduced compared to baseline (fig. 4). On the other hand, cotton treatment did not significantly reduce the density of *S. aureus* during the whole treatment period; there was even an increase in bacterial density. Numbers of *S. aureus* remained high on day 14, 7 days after termination of treatment (fig. 4).

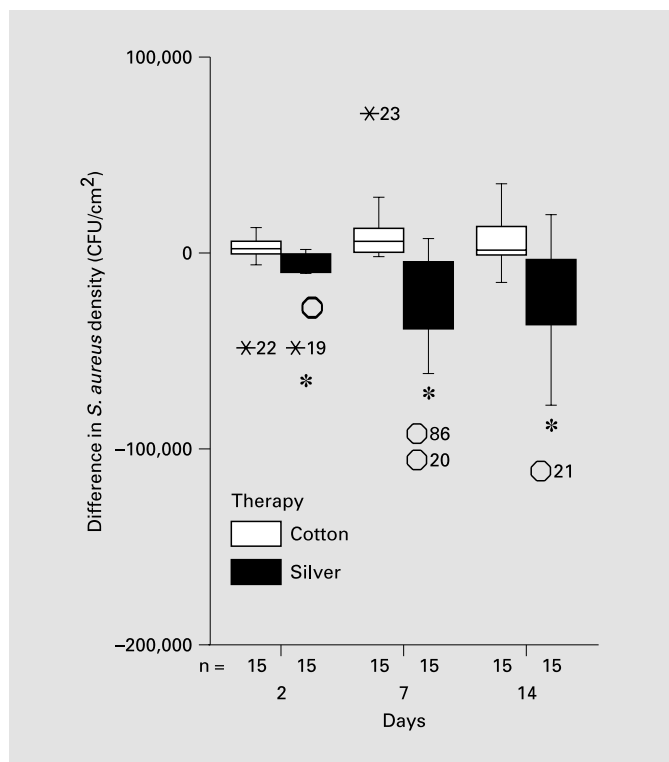
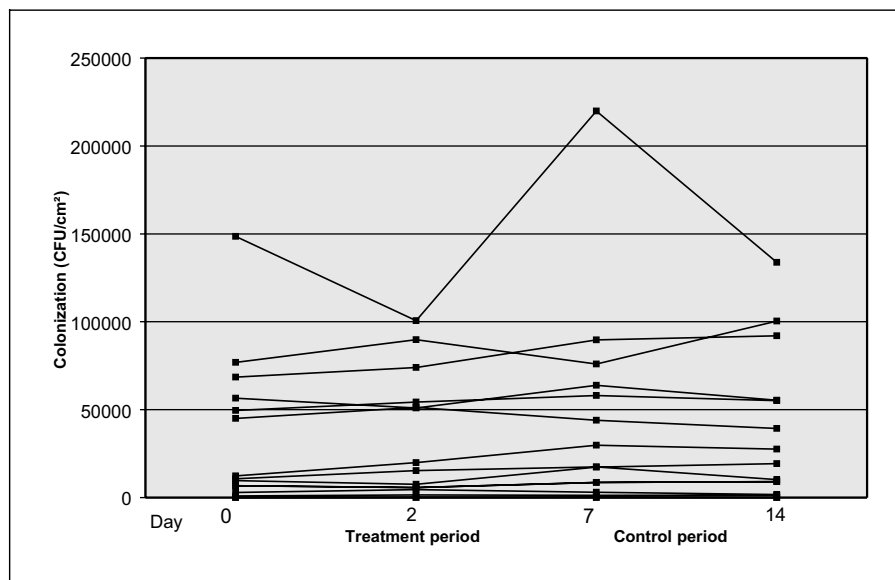
Comparison between silver-coated textile site and cotton treatment revealed a significantly lower *S. aureus* colonization on day 7 ( $p = 0.002$ ) and at the time point of control (day 14;  $p < 0.05$ ) on the silver-coated textile site (data not shown). At baseline as well as on day 2, no significant difference between the two treatment modalities could be seen.

#### Clinical Evaluation – Local SCORAD

Clinical severity, expressed by local SCORAD, was comparable between the two treatment arms at baseline, a significant difference could not be assessed.

After already 2 days, a constant decrease in local SCORAD could be seen on the silver-coated textile site (right elbow flexure) in nearly all patients and continued

**Fig. 3.** Bacterial colonization by *S. aureus* of affected sites covered by cotton (left elbow flexure) at different time points of evaluation: days 0, 2, 7 and 14. Results of *S. aureus* colonization in all 15 patients are expressed as CFU/cm<sup>2</sup>.



**Fig. 4.** Difference in *S. aureus* density within affected silver-coated textile sites (right elbow flexure) and cotton-covered sites (left elbow flexure) in patients with AE during the study period (day 0 vs. days 2, 7 and 14), expressed as CFU/cm<sup>2</sup>. The reduction of *S. aureus* was highly significant on days 2, 7 and 14 on the silver-coated textile site (right elbow flexure; \*  $p < 0.01$ ) compared to baseline (day 0). On the cotton site, no significant reduction could be seen. O, x = Extreme values beyond statistical analysis.

to fall until termination of treatment (day 7). Thereafter, the severity of eczema was assessed constant in 5 and declined in 6 of 15 patients (fig. 5). In contrast, the course of clinically evaluated eczema severity remained fairly unchanged on the cotton site (left elbow flexure) during and after treatment in all 15 patients (fig. 6).

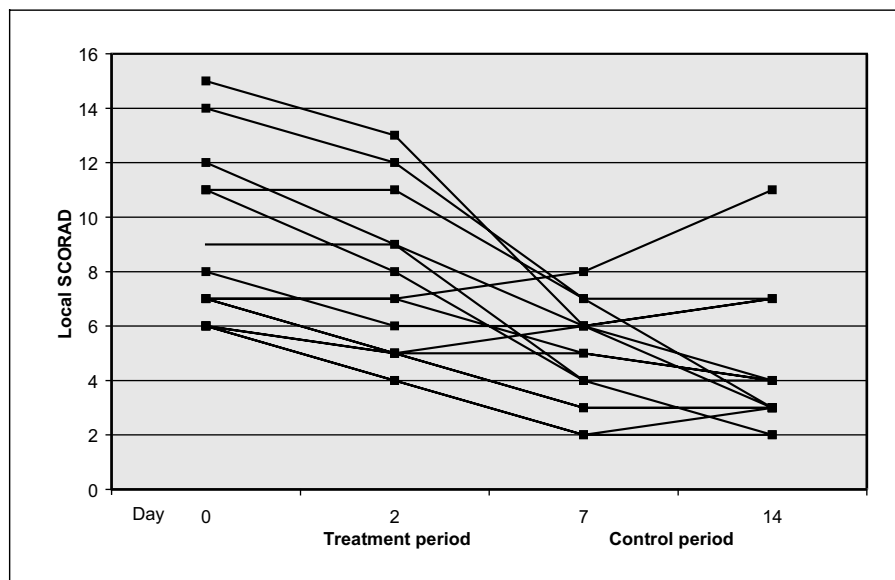
An excellent clinical response was seen on the silver-coated textile site: the reduction of the local SCORAD was highly significant at all time points of evaluation (days 2, 7 and 14) in comparison with baseline ( $p = 0.003$ ,  $p = 0.001$  and  $p = 0.004$ , respectively; fig. 7). On the cotton site, a slight clinical improvement could be seen on day 2 of evaluation without statistical significance; however, on days 7 and 14, the local SCORAD values were even higher than at baseline (fig. 7).

Comparing the two treatment arms, the local SCORAD was constantly lower at all time points of clinical evaluation on the silver-coated textile site (right elbow flexure), reaching high statistical significance on day 7 and even 7 days after termination of treatment (day 14; data not shown).

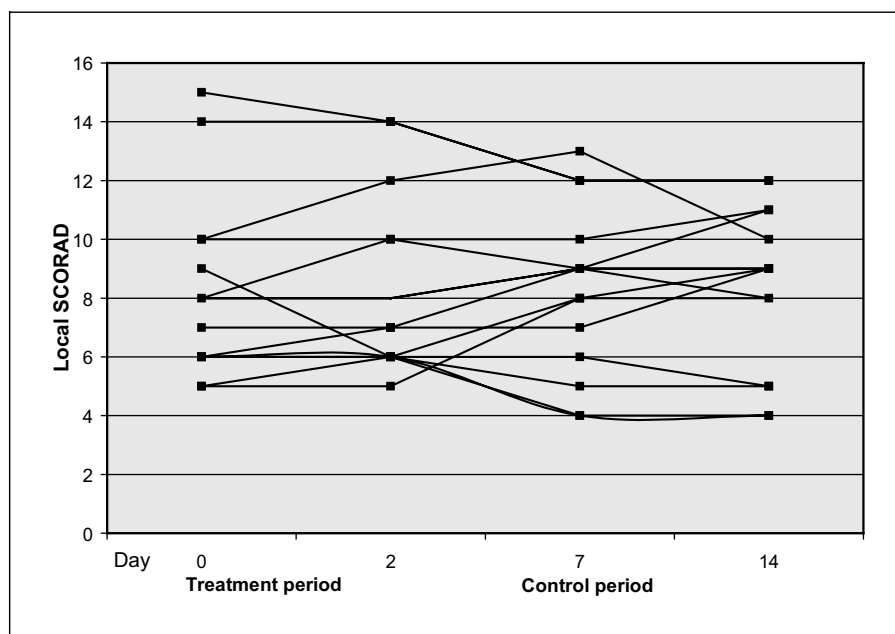
#### *Correlation of S. aureus Density and Local SCORAD*

The reduction of *S. aureus* colonization paralleled the clinical improvement on the silver-coated textile site. A significant correlation between local SCORAD and bacterial density was seen only on day 14 ( $p = 0.01$ ).

**Fig. 5.** Clinical severity in affected sites covered by silver-coated textile (right elbow flexure) at different time points of evaluation: days 0, 2, 7 and 14. Results in all 15 patients are expressed as local SCORAD values (0–18).



**Fig. 6.** Clinical severity in affected sites covered by cotton (left elbow flexure) at different time points of evaluation: days 0, 2, 7 and 14. Results in all 15 patients are expressed as local SCORAD values (0–18).



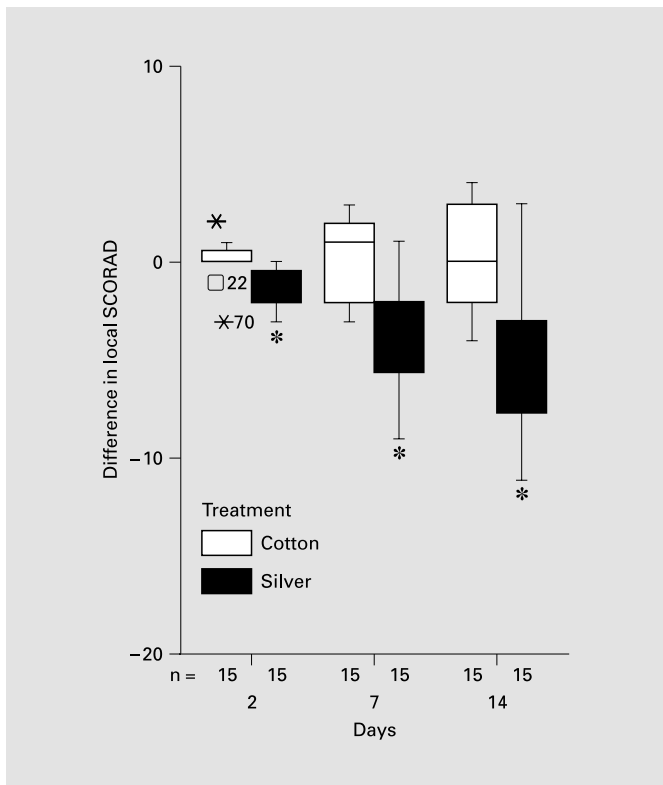
## Discussion

In the present study, a superior clinical improvement by the use of silver-coated compared to cotton textiles paralleled by a potent anti-*S. aureus* efficacy was demonstrated.

Silver-coated textiles induced a highly significant reduction of *S. aureus* already 2 days after initiation of textile treatment and lasted throughout the whole therapy phase. Even 7 days after cessation, *S. aureus* density was

significantly lower compared to baseline. The reduction of *S. aureus* was paralleled by a reduction of clinical severity.

The mechanisms of the antibacterial activity of silver ions are not yet fully understood. Silver ions seem to cause a detachment of the cytoplasm membrane from the bacterial cell wall. The existence of elements of silver and sulfur in the electron-dense granules and cytoplasm suggest the antibacterial mechanism of silver by loss of the ability of DNA replication and protein inactivation after Ag(+)



**Fig. 7.** Clinical eczema severity differences within affected silver-coated textile sites (right elbow flexure) and cotton-covered sites (left elbow flexure) in patients with AE at different time points of evaluation: days 2, 7 and 14 compared to baseline (day 0). A highly significant reduction of the local SCORAD could be seen on days 2, 7 and 14 (\*  $p < 0.01$ ) on the silver-coated site compared to baseline. No significant reduction could be noted on the cotton-covered site. Clinical eczema severity is expressed in local SCORAD (0–18) in all 15 patients. O, X = Extreme values beyond statistical analysis.

treatment [22]. To our knowledge, the antibacterial effect of silver ions in *S.-aureus*-colonized skin in patients with AE has not yet been investigated in vivo.

The disruption of the skin barrier function in patients with AE is known to be one of the major pathophysiological aspects of the disease [23]. Quantitative and qualitative changes in lipid composition [24–26] result not only in an increased transepidermal water loss [27], but also in a higher susceptibility to external irritants in affected and nonaffected skin [23, 28]. By textile protection, external provocation factors of the AE can be diminished, e.g. aeroallergens or UV irradiation as well as contact with irritating material. In addition, due to textile protection the itch-and-scratch cycle can be disrupted. In this context, the clinical improvement on the cotton-treated site

on day 2 was probably due to the textile protecting effect, since no anti-inflammatory therapy had been used. Our results showing a clinical improvement paralleled by a reduction of *S. aureus* counts indicate that antiseptic therapy is essential for an efficient therapy of affected lesions in AE. These findings are in accordance with earlier studies implicating that antibiotic or antiseptic therapy contributes to a faster clearance of AE [11, 29]. Of interest was the observed prolonged effect on staphylococcal reduction exhibited during the period of active wear. This is in contrast to the effects seen by the antistaphylococcal dye gentian violet where cessation of therapy resulted in immediate subsequent recolonization [11]. These findings could indicate that overnight wearing of silver-coated textiles might be able to sustain a constant *S. aureus* reduction.

Since the effectiveness of combining topical antibiotic or anti-infective agents with glucocorticosteroids is still controversially discussed [30], textiles with antibacterial qualities may offer the advantage of enhancing the clinical efficacy of glucocorticosteroid or other anti-inflammatory therapy. In addition, an identical clinical efficacy might be achieved by combining textile antistaphylococcal treatment and steroids of less potency and in this way reducing possible side effects of glucocorticosteroids. Concerning possible toxicological side effects of silver-coated textiles, toxicity is related to absorption through dermal wounds into the systemic circulation [31]. In further studies, silver absorption in patients wearing silver-coated textiles needs to be investigated.

## References

- 1 Leung DY: Atopic dermatitis: The skin as a window into the pathogenesis of chronic allergic diseases. *J Allergy Clin Immunol* 1995;96:302–318.
- 2 Yarwood JM, Leung DY, Schlievert PM: Evidence for the involvement of bacterial superantigens in psoriasis, atopic dermatitis, and Kawasaki syndrome. *FEMS Microbiol Lett* 2000;192:1–7.
- 3 Williams REA, Gibson AG, Aitchinson TC, Lever R, Mackie RM: Assessment of a contact-plate sampling technique and subsequent quantitative bacterial studies in atopic dermatitis. *Br J Dermatol* 1990;123:493–501.
- 4 Nomura I, Tanaka K, Tomita H, Katsunuma T, Ohya Y, Ikeda N, Takeda T, Saito H, Akasawa A: Evaluation of the staphylococcal exotoxins and their specific IgE in childhood atopic dermatitis. *J Allergy Clin Immunol* 1999;104:441–446.
- 5 Bunikowski R, Mielke ME, Skarabis H, Worm M, Anagnostopoulos I, Kolde G, Wahn U, Renz T: Evidence for a disease-promoting effect of *Staphylococcus aureus*-derived exotoxins in atopic dermatitis. *J Allergy Clin Immunol* 2000;105:814–819.
- 6 Tokura Y, Yagi J, O'Malley M, Lewis JM, Takigawa M, Edelson RL, Tigelaar RE: Superantigenic staphylococcal exotoxins induce T cell proliferation in the presence of Langerhans cells or class II-bearing keratinocytes and stimulate keratinocytes to produce T cell-activating cytokines. *J Invest Dermatol* 1994;102:31–38.
- 7 Mempel M, Schnopp C, Hojka M, Fesq H, Weidinger S, Schaller M, Korting HC, Ring J, Abeck D: Invasion of human keratinocytes by *Staphylococcus aureus* and intracellular bacterial persistence represent haemolysin-independent virulence mechanisms that are followed by features of necrotic and apoptotic keratinocyte cell death. *Br J Dermatol* 2002;146:943–951.
- 8 Mempel M, Schmidt T, Heeg K, Abeck D, Ring J: Role of *Staphylococcus aureus* surface-associated proteins in the attachment to cultural HaCaT keratinocytes in a new adhesion assay. *J Invest Dermatol* 1998;109:427.
- 9 Chambers HF, Hackbarth CJ: Methicillin-resistant staphylococci: Genetics and mechanisms of resistance. *Antimicrob Agents Chemother* 1989;33:991–994.
- 10 Ring J, Brockow K, Abeck D: The therapeutic concept of 'patient management' in atopic eczema. *Allergy* 1996;51:206–215.
- 11 Brockow K, Grabenhorst P, Abeck D, Traupe B, Ring J, Hoppe U, Wolf F: Effect of gentian violet, corticosteroid and tar preparations in *Staphylococcus-aureus*-colonized atopic eczema. *Dermatology* 1999;199:231–236.
- 12 Verbist L: The antimicrobial activity of fusidic acid. *J Antimicrob Chemother* 1990;25 (suppl):1–5.
- 13 Stalder JF, Fleury M, Sourisse M, Allavoine T, Chalamet C, Brosset P, Litoux P: Comparative effect of two topical antiseptics (chlorhexidine vs KMnO<sub>4</sub>) on bacterial skin flora in atopic dermatitis. *Acta Derm Venereol (Stockh)* 1992; suppl 176:132–134.
- 14 Lansdown AB: Silver I: Its antibacterial properties and mechanism. *J Wound Care* 2002;11:125–130.
- 15 Bosetti M, Masse A, Tobin E, Cannas M: Silver coated materials for external fixation devices: In vitro biocompatibility and genotoxicity. *Biomaterials* 2002;23:887–892.
- 16 Schaeffer AJ, Story KO, Johnson SM: Effect of silver oxide/trichloroisocyanuric acid antimicrobial urinary drainage system on catheter-associated bacteriuria. *J Urol* 1988;139:69–73.
- 17 Matura T, Abe Y, Sato Y, Okamoto K, Ueshige M, Akagawa Y: Prolonged antimicrobial effect of tissue conditioners containing silver zeolite. *J Dent* 1997;25:373–377.
- 18 BioService: Test 001118. 2001.
- 19 Hanifin JM, Rajka G: Diagnostic features of atopic dermatitis. *Acta Derm Venereol (Stockh)* 1980;92(suppl):44–47.
- 20 European Task Force on Atopic Dermatitis: Severity scoring of atopic dermatitis: The SCORAD index. Consensus report of the European Task Force on Atopic Dermatitis. *Dermatology* 1993;186:23–31.
- 21 Williamson P, Kligman AM: A new method for quantitative investigation of cutaneous bacteria. *J Invest Dermatol* 1965;45:498–503.
- 22 Feng QL, Wu J, Chen GQ, Cui FZ, Kim TN, Kim JO: A mechanistic study of the antibacterial effect of silver ions on *Escherichia coli* and *Staphylococcus aureus*. *J Biomed Mater Res* 2000;52:662–668.
- 23 Abeck D, Bleck O, Ring J: Skin barrier and eczema; in Ring J, Behrendt H, Vieluf D (eds): *New Trends in Allergy IV*. Berlin, Springer, 1996, pp 213–220.
- 24 Imokawa G, Abe A, Jin K, Higaki Y, Kawashima M, Hidano A: Decreased level of ceramides in stratum corneum of atopic dermatitis: An etiologic factor in atopic dry skin? *J Invest Dermatol* 1991;96:523–526.
- 25 Murata Y, Ogata J, Higaki Y, Kawashima M, Yada Y, Higuchi K, Tsuchiya T, Kawainami S, Imokawa G: Abnormal expression of sphingomyelin acylase in atopic dermatitis: An etiologic factor for ceramide deficiency? *J Invest Dermatol* 1996;106:1242–1249.
- 26 Bleck O, Abeck D, Ring J, Hoppe U, Vietzke JP, Wolber R, Brandt O, Schreiner V: Two ceramide subfractions detectable in Cer(AS) position by HPTLC in skin surface lipids of non-lesional skin of atopic eczema. *J Invest Dermatol* 1999;113:894–900.
- 27 Werner Y, Lindberg M: Transepidermal water loss in dry and clinically normal skin in patients with atopic dermatitis. *Acta Derm Venereol* 1985;65:102–105.
- 28 Abeck D, Strom K: Optimal management for atopic dermatitis. *Am J Clin Dermatol* 2000;1:41–46.
- 29 Lever R, Hadley K, Downey D, Mackie R: Staphylococcal colonization in atopic dermatitis and the effect of topical mupirocin therapy. *Br J Dermatol* 1988;119:189–198.
- 30 Korting HC, Zienicke H, Braun-Falco O, Bork K, Milbradt R, Nolting S, Schöpf E, Tronnier H: Modern topical glucocorticoids and anti-infectives for superinfected atopic eczema: Do prednicarbate and didecylidimethylammoniumchloride form a rational combination? *Infection* 1994;22:390–393.
- 31 Hollinger MA: Toxicological aspects of topical silver pharmaceuticals. *Crit Rev Toxicol* 1996;26:255–260.