

## CASE REPORT

### Right ventricular thrombus formation in a patient with arrhythmogenic right ventricular dysplasia following radiofrequency ablation

Stephan Kemmner<sup>1,2</sup>, Hasema Lesevic<sup>1</sup>, Tilko Reents<sup>1</sup>, Heribert Schunkert<sup>1,3</sup> & Christof Burgdorf<sup>1</sup>

<sup>1</sup>Klinik für Herz- und Kreislauferkrankungen, Deutsches Herzzentrum München, Technische Universität München, Munich, Germany

<sup>2</sup>Department of Nephrology, Klinikum rechts der Isar, Technische Universität München, Munich, Germany

<sup>3</sup>Deutsches Zentrum für Herz-Kreislauf-Forschung (DZHK) e.V., Partner Site Munich Heart Alliance (MHA), Munich, Germany

#### Correspondence

Stephan Kemmner, Klinikum rechts der Isar, Ismaninger Str. 22, 81675 München, Germany. Tel: +49 (0)89 4140 6704; Fax: +49 (0)89 4140 7734; E-mail: stephan.kemmner@tum.de

#### Funding Information

This work was supported by the German Research Foundation (DFG) and the Technische Universität München within the funding programme Open Access Publishing.

Received: 12 November 2015; Revised: 19 February 2016; Accepted: 24 February 2016

*Clinical Case Reports* 2016; 4(6): 554–557

doi: 10.1002/ccr3.537

#### Introduction

Arrhythmogenic right ventricular dysplasia (ARVD) is a rare hereditary progressive cardiomyopathy characterized by right ventricular dysfunction, ventricular arrhythmia, and increased risk of sudden cardiac death [1]. Thromboembolic events with an annual incidence of 0.5/100 patients are possible complications, but significantly lower than described for left ventricular heart failure [2]. Possible risk factors for thromboembolic events in ARVD are right ventricle dilatation, aneurysms, and wall motion abnormalities. So far atrial and ventricular thrombi are described due to right ventricular dysfunction, dilated akinetic right ventricle, or a single apical aneurysm [3–5]. Studies did not look on patients following radiofrequency ablation due to ventricular arrhythmia. Here, we report a case of recurrent RV thrombus formation in the scar area of right ventricular radiofrequency ablation of recurring ventricular tachycardia in a patient suffering from ARVD. This case should rouse attention for thromboembolic events as possible complication after radiofrequency abla-

#### Key Clinical Message

A middle-aged female suffering from ARVD presented for routine follow-up 8 weeks after right ventricular radiofrequency ablation of recurring ventricular tachycardia. Echocardiography revealed two right ventricular thrombi in the scar area of right ventricular radiofrequency ablation. Ablation-related thromboembolic events should be considered as possible complication in patients suffering from ARVD.

#### Keywords

Anticoagulation, arrhythmogenic right ventricular dysplasia, radiofrequency ablation, thrombus formation, ventricular tachycardia.

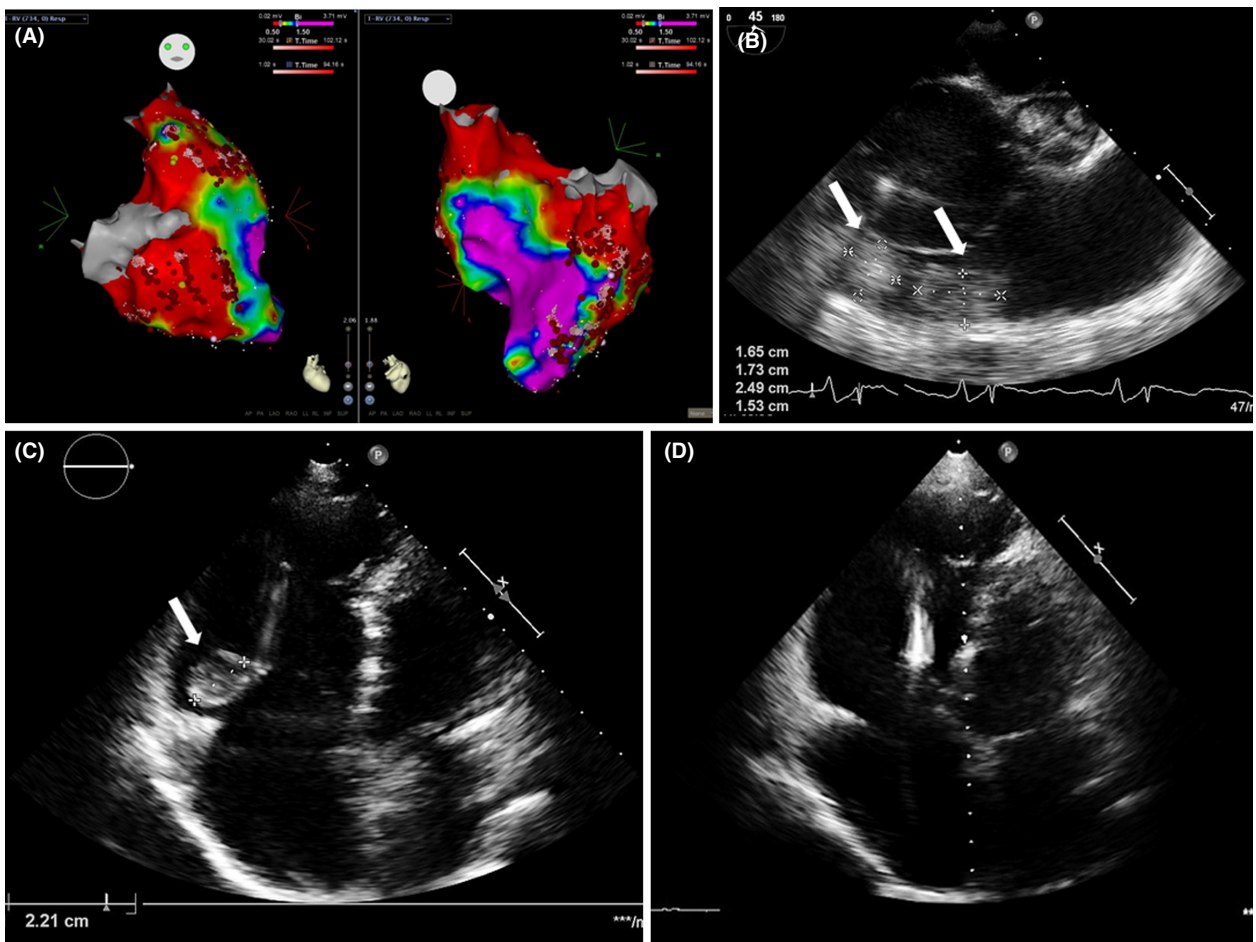
tion in patients suffering from ARVD and for a treatment option in this complication with apixaban as an easily applicable new oral anticoagulant.

#### Case Report

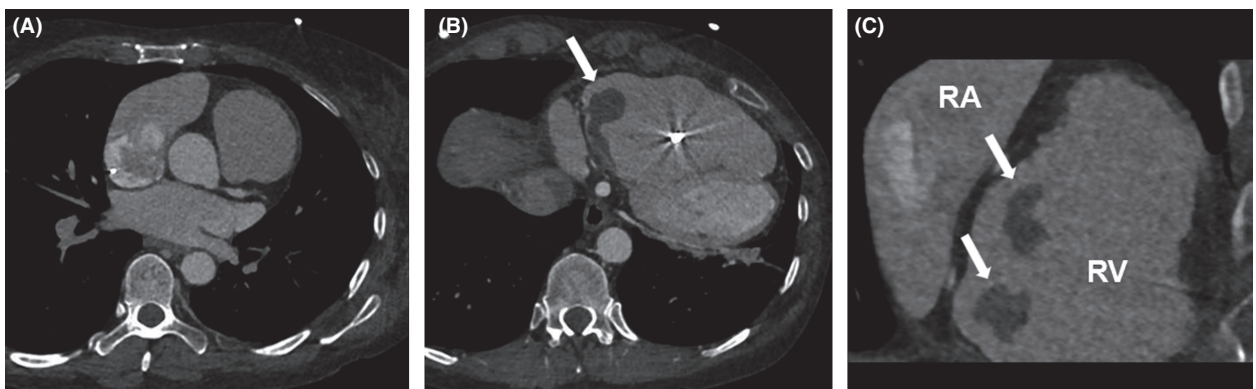
A 50-year-old woman with arrhythmogenic right ventricular dysplasia (ARVD) and previous implantation of a cardioverter–defibrillator (ICD) presented in our outpatient department for routine follow-up 8 weeks after right ventricular (RV) radiofrequency ablation of recurring ventricular tachycardia (Fig. 1A).

Transthoracic and subsequent transesophageal echocardiography revealed a severely reduced systolic RV function and two 2.5 × 1.5 cm and 1.7 × 1.7 cm round structures, appearing on the lateral annulus of the tricuspid valve not associated with the ICD lead (Fig. 1B).

Both structures were not documented in previous examinations, that is, before radiofrequency ablation. Pulmonary embolism was excluded by contrast-enhanced CT scan, which confirmed the two structures (Fig. 2).



**Figure 1.** (A) Three-dimensional voltage map of the right ventricle in A.P. (left) and P.A. projection (right). Purple indicates normal bipolar electrogram amplitude (>1.5 mV); red represents scar area with bipolar electrogram amplitude (<0.5 mV). Brown dots represent ablation lesions including the area of the posterior and anterior tricuspid valve. (B–D) Echocardiographic presence and resolution of right ventricular thrombi. (B) Hospital admission, mid esophageal short-axis view. (C) 3 days after apixaban therapy, only one thrombus remains in the right ventricle, transthoracic apical 4-chamber view. (D) 30 days of apixaban treatment, no thrombi were detectable in the right ventricle, transthoracic apical 4-chamber view.



**Figure 2.** (A) CT scans at hospital admission ruled out pulmonary embolism and (B, C) confirmed right ventricular thrombi. RA, right atrium; RV, right ventricle.

Bearing in mind the history of recently performed RV radiofrequency ablation, both structures were supposed to be new thrombi in the right ventricle.

Antithrombotic therapy with intravenous unfractionated heparin in therapeutic dosage (700 IU per hour adapted to body weight) was started for 2 days with bed rest and hemodynamic monitoring on intensive care unit. Subsequently, we treated the patient with the direct factor Xa inhibitor apixaban (10 mg orally BID) for 7 days. Afterward, 5 mg BID of apixaban was given as recommended for the treatment of acute venous thromboembolism with this novel drug [6]. Three days after starting of apixaban therapy, echocardiography displayed resolution of one thrombus with one remaining in the right ventricle (Fig. 1C). The patient was discharged from the hospital on day 5 with the recommended anticoagulation regimen.

At follow-up examination after 30 days of apixaban therapy, neither thrombi nor signs pointing to pulmonary embolism were detected by transthoracic echocardiography (Fig. 1D). The patient kept on feeling well without any discomfort like dyspnea or bleeding. No further episodes of ventricular tachycardia were documented since radiofrequency ablation. We recommended continuation of apixaban (5 mg BID) for three further months with regular echocardiographic follow-up.

The patient presented again in our outpatient department for routine follow-up 5 months later (2 months after regular ending of apixaban). Transthoracic echocardiography revealed a new 3.2 cm × 1.9 cm round structure appearing on the RV wall close to the area of earlier thrombus formation, supposed to be a recurrent RV thrombus. There were further no signs pointing to pulmonary embolism in echocardiography and the patient kept on feeling well without dyspnoea in the last month. Anticoagulation with apixaban (5 mg BID) was started again. Bearing in mind of recurrent thrombus formation 2 months after ending of initial apixaban therapy, the need of lifelong anticoagulation in our case was recommended.

## Discussion

Formation of RV thrombi is a rare event even in ARVD. Wlodarska *et al.* [2] investigated thromboembolic complications in 126 patients with ARVD over a mean follow-up of 99 months. The reported annual incidence of 0.5 thromboembolic events per 100 patients included pulmonary embolism, RV outflow tract thrombosis, and cerebrovascular events associated with atrial fibrillation. However, this study did not look on patients who underwent radiofrequency ablation for ventricular tachycardia. Whether thrombus formation in our patient occurred spontaneously or was related to ablation of ventricular tachycardia remains elusive, but the recurrent thrombus formation

gives us a hint that there is an increased risk in these patients. Thrombus formation in ARVD patients can occur without obvious triggers [4]. Scar formation after radiofrequency ablation may increase the risk. While prospective studies investigating this issue may not be performed due to low incidence, we want to rouse attention for thromboembolic events after radiofrequency ablation in patients not suffering from atrial flutter or atrial fibrillation, where procedure-related thromboembolic events are successfully reduced by continuation of warfarin therapy [7].

Apixaban is a direct factor Xa inhibitor and a well-investigated member of the class of new oral anticoagulants (NOACs). Advantages of NOACs include no need for laboratory coagulation management, fixed dosing, reduced rates of bleeding, as well as fewer drug interactions by induction of cytochrome P-dependent enzymes in the liver [8]. Apixaban can be administered without overlapping therapy with unfractionated or low-molecular-weight heparin formulations. In a major phase III trial, the ARISTOTLE trial, it was shown that apixaban is effective in prevention of stroke and embolism in atrial fibrillation compared to warfarin [9]. Apixaban was also studied in the treatment of acute deep vein thrombosis and acute pulmonary embolism in the AMPLIFY trial. In this randomized, controlled, double-blinded study, apixaban was not inferior to conventional anticoagulant treatment regimens regarding death as primary endpoint. Furthermore, significantly less bleeding events were reported in the apixaban group [6]. So far, two case reports showed that apixaban is able to resolve thrombi in the left atrium and left ventricle in a patient with persistent atrial fibrillation and in a patient following acute myocardial infarction, respectively [10, 11]. The approval for pulmonary embolism guided the decision to use apixaban in this patient. Because of regulatory issues apixaban can not be reimbursed in several European countries in this special case, because the patient does not suffer from pulmonary embolism or non-valvular atrial fibrillation. Therefore, the use of apixaban instead of vitamin-K-antagonists has to be considered carefully.

## Conclusion

In addition, our case demonstrates that radiofrequency ablation-related RV thrombus formation is a possible complication in patients suffering from ARVD and that apixaban as an easily applicable NOAC may be a treatment option for these patients.

## Conflict of Interest

On behalf of all authors, the corresponding author states that there is no conflict of interest.

## References

1. Calkins, H. 2015. Arrhythmogenic right ventricular dysplasia/cardiomyopathy—three decades of progress. *Circ. J.* 79:901–913.
2. Wlodarska, E. K., O. Wozniak, M. Konka, W. Rydlewska-Sadowska, A. Biederman, and P. Hoffman. 2006. Thromboembolic complications in patients with arrhythmogenic right ventricular dysplasia/cardiomyopathy. *Europace* 8:596–600.
3. Attenhofer Jost, C. H., T. Bombeli, C. Schrimpf, E. Oechslin, W. Kiowski, and R. Jenni. 2000. Extensive thrombus formation in the right ventricle due to a rare combination of arrhythmogenic right ventricular cardiomyopathy and heterozygous prothrombin gene mutation g20210 a. *Cardiology* 93:127–130.
4. Bilge, M., B. Eryonucu, and N. Guler. 2000. A case of arrhythmogenic right ventricular cardiomyopathy in sinus rhythm associated with thrombus in the right atrium. *J. Am. Soc. Echocardiogr.* 13:154–156.
5. Antonini-Canterin, F., R. Sandrini, D. Pavan, F. Zardo, and G. L. Nicolosi. 2000. Right ventricular thrombosis in arrhythmogenic cardiomyopathy. A case report. *Ital. Heart J. Suppl.* 1:415–418.
6. Agnelli, G., H. R. Buller, A. Cohen, M. Curto, A. S. Gallus, M. Johnson, et al. 2013. Oral apixaban for the treatment of acute venous thromboembolism. *N. Engl. J. Med.* 369:799–808.
7. Di Biase, L., J. D. Burkhardt, P. Santangeli, P. Mohanty, J. E. Sanchez, R. Horton, et al. 2014. Periprocedural stroke and bleeding complications in patients undergoing catheter ablation of atrial fibrillation with different anticoagulation management: results from the role of coumadin in preventing thromboembolism in atrial fibrillation (af) patients undergoing catheter ablation (compare) randomized trial. *Circulation* 129:2638–2644.
8. Fontana, P., S. Z. Goldhaber, and H. Bounameaux. 2014. Direct oral anticoagulants in the treatment and long-term prevention of venous thrombo-embolism. *Eur. Heart J.* 35:1836–1843.
9. Lopes, R. D., S. M. Al-Khatib, L. Wallentin, H. Yang, J. Ansell, M. C. Bahit, et al. 2012. Efficacy and safety of apixaban compared with warfarin according to patient risk of stroke and of bleeding in atrial fibrillation: a secondary analysis of a randomised controlled trial. *Lancet* 380:1749–1758.
10. Dobashi, S., T. Fujino, and T. Ikeda. 2014. Use of apixaban for an elderly patient with left atrial thrombus. *BMJ Case Rep.* doi: 10.1136/bcr-2014-203870.
11. Mano, Y., K. Koide, H. Sukegawa, M. Kodaira, and T. Ohki. 2016. Successful resolution of a left ventricular thrombus with apixaban treatment following acute myocardial infarction. *Heart Vessels* 31:118–123.