

BRIEF COMMUNICATION

Biallelic mutations in *PIGP* cause developmental and epileptic encephalopathy

Martin Krenn^{1,2}, Alexej Knaus³, Dominik S. Westphal^{2,4}, Saskia B. Wortmann^{2,4,5}, Tilman Polster⁶, Friedrich G. Woermann⁶, Michael Karenfort⁷, Ertan Mayatepek⁷, Thomas Meitinger^{2,4}, Matias Wagner^{2,4,8} & Felix Distelmaier⁷

¹Department of Neurology, Medical University of Vienna, Vienna, Austria

²Institute of Human Genetics, Technical University Munich, Munich, Germany

³Institute for Genomic Statistics and Bioinformatics, Rheinische Friedrich-Wilhelms Universität, Bonn, Germany

⁴Institute of Human Genetics, Helmholtz Zentrum München, Neuherberg, Germany

⁵University Children's Hospital, Paracelsus Medical University, Salzburg, Austria

⁶Krankenhaus Mara, Bethel Epilepsy Centre, Bielefeld, Germany

⁷Department of General Pediatrics, Neonatology and Pediatric Cardiology, University Children's Hospital, Medical Faculty, Heinrich-Heine-University Düsseldorf, Düsseldorf, Germany

⁸Institute of Neurogenomics, Helmholtz Zentrum München, Neuherberg, Germany

Correspondence

Felix Distelmaier, Department of General Pediatrics, Neonatology and Paediatric Cardiology, University Children's Hospital, Medical Faculty, Heinrich-Heine-University Düsseldorf, Moorenstraße 5, 40225 Düsseldorf, Germany. Tel.: +49-211-811-7696; Fax: 49-211-811-9276; E-mail: felix.distelmaier@med.uni-duesseldorf.de

Funding Information

This study was supported by a grant of the German Research Foundation/Deutsche Forschungsgemeinschaft (DI 1731/2-1 to FD) and by a grant of the "Elterninitiative Kinderkrebsklinik e.V." (Düsseldorf; #701900167).

Received: 21 January 2019; Revised: 5 March 2019; Accepted: 7 March 2019

Annals of Clinical and Translational Neurology 2019; 6(5): 968–973

doi: 10.1002/acn3.768

Introduction

The developmental and epileptic encephalopathies (DEE) represent a clinically and genetically heterogeneous group of disorders characterized by infantile-onset seizures and subsequent psychomotor delay. In the era of next-generation sequencing technology, the underlying genetic defects are now being identified at a constantly growing rate.^{1–3} While most cases are caused by heterozygous de novo

Abstract

Developmental and epileptic encephalopathies are characterized by infantile seizures and psychomotor delay. Glycosylphosphatidylinositol biosynthesis defects, resulting in impaired tethering of various proteins to the cell surface, represent the underlying pathology in some patients. One of the genes involved, *PIGP*, has recently been associated with infantile seizures and developmental delay in two siblings. Here, we report the second family with a markedly overlapping phenotype due to a homozygous frameshift mutation (c.456delA; p.Glu153Asnfs*34) in *PIGP*. Flow cytometry of patient granulocytes confirmed reduced expression of glycosylphosphatidylinositol-anchored proteins as functional consequence. Our findings corroborate *PIGP* as a monogenic disease gene for developmental and epileptic encephalopathy.

mutations, the recessively inherited glycosylphosphatidylinositol (GPI) biosynthesis defects (GPIBDs) constitute a subgroup that may present as DEE. The responsible genes encode various proteins involved in the biosynthesis of GPI anchors that tether about 150 different proteins to the plasma membrane. Thus, GPI anchors have secondary structural and catalytical functions with a crucial role in brain development.⁴ To date, 18 of the 30 genes involved in GPI anchor biosynthesis have been associated with human

diseases. The phenotypic spectrum of GPIBDs usually comprises seizures, developmental delay, facial dysmorphism and brain malformations, to name but a few.^{5–9} Most recently, two siblings with DEE carrying biallelic variants (c.74T>C;p.Met25Thr and c.456delA;p.Glu153Asnfs*34) in *PIGP* (MIM *605938), which is involved in the first step of GPI anchor synthesis, were described. The two affected siblings presented with early-infantile epilepsy, global developmental delay, and marked hypotonia. Functional studies using patient cells showed reduced mRNA levels and a defective protein supporting the pathogenicity of the variants.¹⁰ These findings suggested *PIGP* as a candidate gene for DEE.

Herein, we provide a clinical, genetic, and functional characterization of the second family with the index patient being affected by *PIGP*-related DEE, hence establishing *PIGP* as a monogenic human disease gene. Our report also illustrates the major therapeutic challenges of this disease.

Patients and Methods

Probands and samples

The parents of the patient gave written informed consent for the collection and storage of clinical data, blood samples, experimental analyses, and publication. The study was conducted in agreement with the Declaration of Helsinki and approved by the local ethics committee (approval number: #4957).

Exome sequencing

After DNA was isolated from leukocytes, whole exome sequencing (WES) was done using *SureSelect Human All Exon Kit* 60 Mb, V6 (Agilent, Santa Clara, California, USA) for exome enrichment. Libraries were sequenced on an *Illumina HiSeq4000* system (Illumina, San Diego, CA).¹¹ Reads were aligned to the UCSC human reference assembly (hg19). More than 98% of the exome were covered at least 20-fold. Average coverage was more than 143-fold. Variant prioritization was performed based on autosomal recessive (MAF <0.1%) and autosomal dominant (MAF <0.01%) filters. Pathogenic variants were confirmed using Sanger sequencing.

Flow cytometry

Flow cytometry of granulocytes (collected in BCT CytoChex tubes) was performed for the patient, both parents and one unrelated control to assess the functional consequences of the mutation. Erythrocytes were removed using hypoosmotic lysing buffer. The cells were washed and stained with fluorescently labeled antibodies against

CD157, CD59 and with fluorescein-labeled proaerolysin (FLAER), which binds to the GPI anchor itself.

Results

Clinical findings

The female index patient was born as the first child of nonconsanguineous, healthy Polish parents. During pregnancy, reduced fetal movements were noted by the mother. The patient was born at term with a birth weight of 3010 g (25th percentile). Her body length was 50 cm (31st percentile) and her head circumference 35 cm (78th percentile). The Apgar score was 9/10/10. During the early postnatal period, the patient was asleep most of the time and markedly lethargic if awake. She did not eat at all during her first 2 days of life. Afterwards, breastfeeding was still not possible necessitating bottle feeding. The first apparent focal epileptic seizure was noted at the age of 7 months (gaze deviation to the left side), followed by status epilepticus shortly thereafter. EEG recordings showed frontal rhythmic delta activity with intermittent left temporal and parieto-occipital sharp waves (an example of an ictal EEG is depicted in Fig. 1). Brain MRI at age 3 months revealed symmetrical tract-like DWI (diffusion-weighted imaging) abnormalities within the brainstem and optic tract and laminar abnormalities in the left hippocampal head. Follow-up MRI at the age of 13 months demonstrated hippocampal volume asymmetry. Of note, the symmetrical alterations within the brainstem and optic tract were not visible anymore (Fig. 1A–D). Further diagnostic work-up including a screening for inborn errors of metabolism (e.g., amino acids in plasma, acylcarnitines, purines, and pyrimidines as well as organic acids in urine) was unremarkable. Serum and CSF (cerebrospinal fluid) lactate were within the normal ranges.

In spite of antiepileptic drug (AED) treatment with levetiracetam, focal seizures recurred at a frequency of ten to 20 episodes per day, partly evolving into focal status epilepticus. Various AED trials including valproic acid, clobazam, levetiracetam, brivaracetam, lacosamide, sulthiame, phenobarbital (used as monotherapy or in combination) as well as a ketogenic diet and steroid treatment did not result in a significant reduction in seizures. Ketosis was induced without complications (no hypoglycemia, no excessive ketosis) with beta-hydroxybutyrate levels between 2 and 3.5 mmol/L.

At present, the child receives a combination therapy with phenobarbital, levetiracetam, and cannabidiol that stabilized the condition with three to five short-lasting seizures per day.

Aside from treatment-refractory epilepsy, the patient also suffers from global developmental delay and pronounced hypotonia, but no other systemic health issues

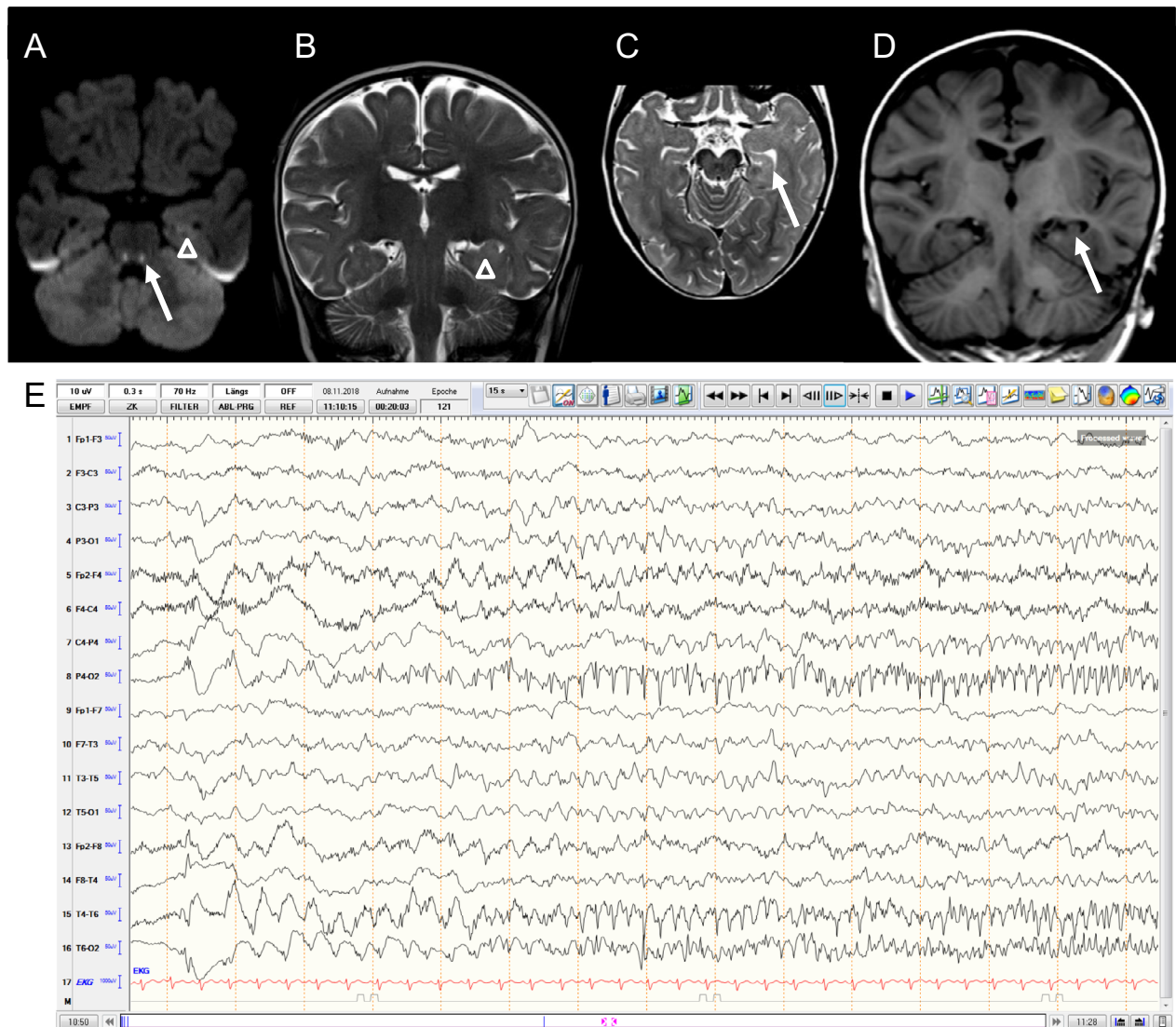


Figure 1. Diagnostic findings of the index patient. Brain MRI studies: (A–B) Left-sided hippocampal edema at age 3 months (open arrow head, axial DWI [diffusion-weighted imaging], coronal T2). (A) Bilateral tract-like DWI abnormalities (arrow - brainstem, optic tract) without evidence for a shine through phenomenon (indicated by low ADC [apparent diffusion coefficient] signal). Of note, the tract-like DWI-abnormalities appeared to be a transient phenomenon and were not visible on follow-up MRI at the age of 13 months (data not shown). (C–D) Hippocampal volume asymmetry left<right at the age of 13 months (axial T2, coronal T1). (E) Example of an ictal EEG pattern of the index patient at the age of 2 years. Bipolar EEG recording shows rhythmic epileptiform discharges localized to the right-temporal region, evolving from delta to theta to alpha frequencies.

were noted. Currently, at the age of 2 years and 4 months, she is still unable to speak and motor milestones such as sitting, crawling and conscious grasping have not been reached.

Molecular findings

An initially performed gene panel for epileptic encephalopathies (100 genes including *PIGA*, *PIGG*, *PIGN*, and *PIGT*) did not reveal an underlying pathogenic mutation.

Using WES, the frameshift variant c.456delA; p.Glu153Asnfs*34 (NM_153681.2) in *PIGG* was detected in a homozygous state in the affected individual and interpreted as potentially pathogenic due to its predicted loss-of-function character. The mutation was found six times in a heterozygous, but not in a homozygous state in the more than 16,000 exome datasets in our in-house database. The Genome Aggregation Database (gnomAD) lists nine heterozygous and also no homozygous carriers. In order to replicate our findings, we sought to identify

further families with biallelic variants in *PIGP* using the web-based collaboration platform *GeneMatcher*.¹² However, our query did not identify additional cases.

Sanger sequencing confirmed the variant as well as a heterozygous carriership for both unaffected parents (Fig. 2A+B). Exome data of the patient revealed only less than 7 Mb of homozygous regions, which confirms that the parents were not consanguineous suggesting a founder mutation.

Using flow cytometry of patient granulocytes, the expression of GPI-anchored proteins was markedly reduced, that is, by 39.5% for CD157, by 45.7% for CD59 and by 52.3% measured by FLAER when compared to the parents and one healthy control (Fig. 2C).

Discussion

In this report, we describe the second independent family with the index patient being affected by early-onset epilepsy, developmental delay and hypotonia caused by a homozygous mutation in the gene *PIGP*. Using flow cytometry, we confirmed a functional effect of the predicted frameshift variant resulting in a reduced expression of GPI-anchored proteins, in keeping with a diagnosis of inherited GPIBD.

Functionally, *PIGP* is involved in the catalyzation of the first step of GPI anchor biosynthesis.¹³ Although the mutation found in our patient is located at the very C-terminal part (in the final exon of all transcripts) of the

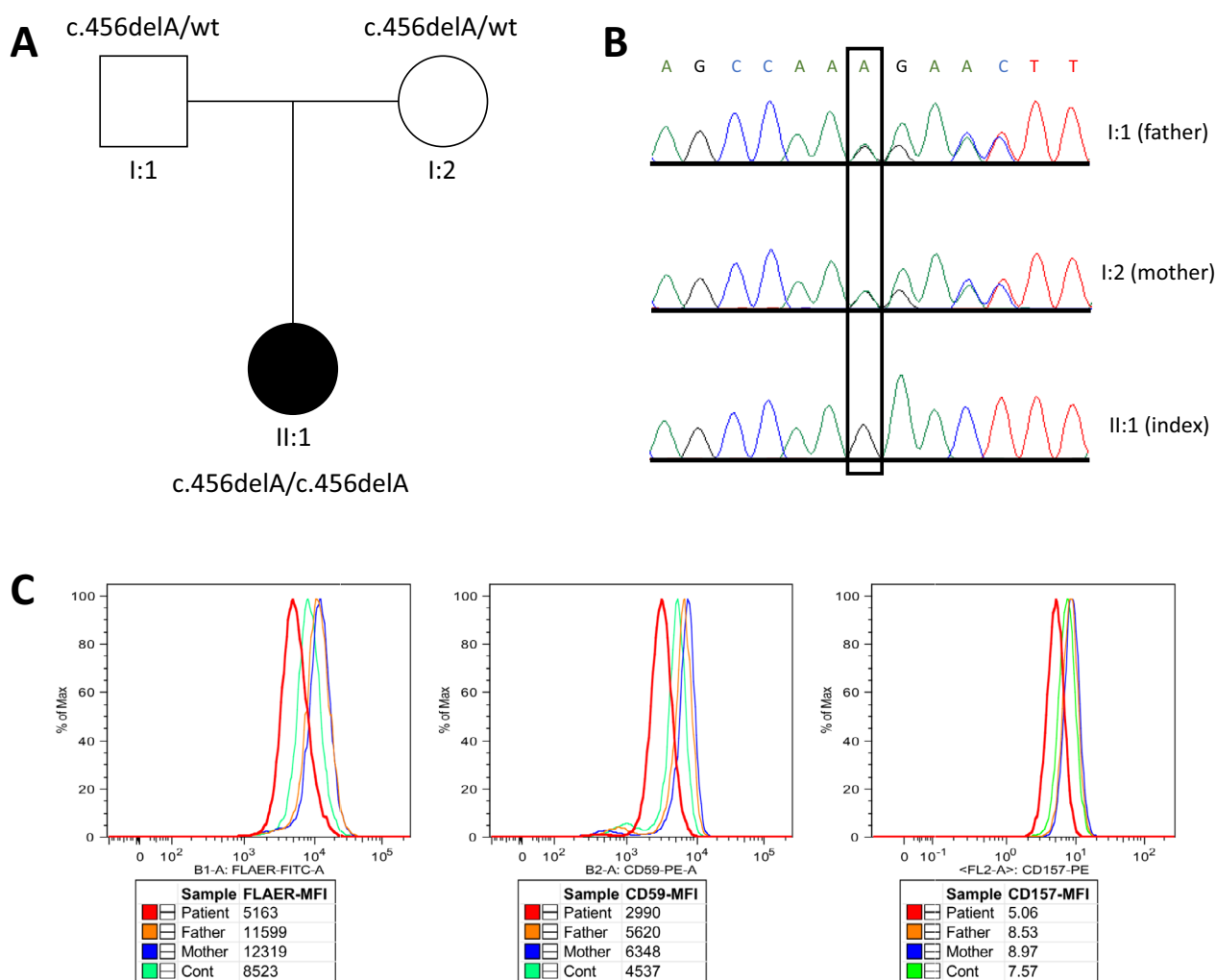


Figure 2. Pedigree and functional data of the reported family. Family tree illustration (A) and electropherograms (B) for the *PIGP* c.456delA; p.Glu153Asnfs*34 (deleted position framed) mutation status of all three family members confirming a heterozygous mutation carrier state in each unaffected parent (I:1 and I:2), and a homozygous state in the affected child (II:1); Flow cytometry (C) of patient granulocytes demonstrating the relative reduction of GPI-anchored proteins (red curves) compared to mean values of healthy father (orange), healthy mother (blue), and one unrelated healthy control (cont) individual (green) by 52.3% (FLAER-MFI), 45.7% (CD59-MFI), and 39.5% (CD157-MFI), respectively.

gene, a compromised protein function had already been shown.¹⁰

From a clinical point of view, the phenotype of our proband markedly overlaps with the two previously reported patients with intractable infantile epilepsy, developmental delay, and hypotonia being the leading features. In addition, the key clinical picture is widely reminiscent of related conditions caused by mutations in genes that act in complex with *PIGP*, that is, *PIGA*, *PIGC*, *PIGH*, *PIGQ*, and *PIGY*.^{5–7,14–16} However, there appears to be a certain phenotypic range for *PIGP*-related disease, even with intrafamilial variability (Table 1).¹⁰ This suggests additional (genetic and environmental) modifying factors that influence the exact clinical presentation.

In view of the clinical data so far available for *PIGP*-related disease, treatment-refractory epilepsy apparently constitutes a major clinical challenge. However, the exact pathophysiological mechanism underlying seizures in GPIBDs is complex and still poorly understood. GPI-anchored proteins are functionally involved in neuron maturation, vesicle trafficking and signal transduction.⁴

Presumably, a combination of the functional consequences eventually leads to an increased seizure susceptibility. Some reports on GPIBDs specifically indicate a variety of structural abnormalities (e.g., dysplasia of the corpus callosum, cerebellar hypoplasia).⁹ In other articles, abnormalities such as generalized brain or cerebellar atrophy only developed during the course of the disease.^{17,18} This is in line with the rather nonspecific abnormalities observed in our patient.

Besides the aforementioned therapeutic challenges, *PIGP*-related disease is also extremely difficult to diagnose given the current diagnostic standards. When reviewing constantly updated offers of commercial gene panel providers, *PIGP* is still absent from comprehensive epilepsy panels (genedx.com – 127 genes, blueprintgenetics.com – 283 genes, fulgentgenetics.com – 397 genes). Furthermore, the Online Mendelian Inheritance in Man (OMIM) database currently lists *PIGP* only as a provisional disease gene (?Epileptic encephalopathy, early infantile, 55, MIM#617599). As exemplified by the child reported here, disease-causing mutations might therefore only be detected by an unbiased genomic approach thus far.

Table 1. Comparison of clinical and genetic characteristics of the three patients with *PIGP*-related developmental and epileptic encephalopathy reported to date., that is, the two affected siblings (Patients 1 and 2) described by Johnstone et al. in 2017 and the patient reported in this study (Patient 3).

	Patient 1 (Johnstone et al. 2017)	Patient 2 (Johnstone et al. 2017)	Patient 3 (this study)
Gender	Male	Female	Female
Birth weight	4360 g	3997 g	3010 g
Current age	10 years (2017)	Died at age 26 months	2 years 4 months (01/2019)
Age of seizure onset	2 weeks	7 weeks	7 months
Seizure semiology	Right-sided facial twitching	Eye twitching, apnea, infantile spasms	Gaze deviation, secondary generalization, recurrent status epilepticus
EEG	Bitemporal sharp waves, right central seizure onset	Multifocal epileptiform discharges, hypsarrhythmia	Frontal rhythmic delta activity, intermittent left temporal/parieto-occipital sharp waves
Treatments and outcome	PB, CZP, TPM, VGB: no seizure freedom, LEV: seizure-free	GBP, VPA, LEV, pyridoxine, folic acid, steroids: no seizure freedom	LEV, STM, VPA, CLB, BRV, LCM, PB, CBD, steroids, ketogenic diet: no seizure freedom
Additional clinical features	DD, central hypotonia, peripheral hypertonia, cortical visual impairment, joint hyperlaxity, recurrent aspiration, feeding difficulties	DD, hypotonia, cortical visual impairment, recurrent aspiration, feeding difficulties, oculogyric crises	DD, hypotonia, feeding difficulties
MRI brain	Thin corpus callosum (age 5 years)	Normal (age 1.5 months)	Transient tract-like DWI-abnormalities (brainstem, optic tract). Hippocampal volume asymmetry.
<i>PIGP</i> mutation(s)	c.456delA;p.Glu153Asnfs*34 c.74T>C;p.Met25Thr (compound heterozygous)	c.456delA;p.Glu153Asnfs*34 c.74T>C;p.Met25Thr (compound heterozygous)	c.456delA;p.Glu153Asnfs*34 (homozygous)

BRV, brivaracetam; CBD, cannabidiol; CLB, clobazam; CZP, clonazepam; DD, developmental delay; EEG, electroencephalography; GBP, gabapentin; LEV, levetiracetam; LCM, lacosamide; MRI, magnetic resonance imaging; PB, phenobarbital; STM, sulthiame; TPM, topiramate; VGB, vigabatrin; VPA, valproic acid.

Taken all this together, our report confirms *PIGP* as a monogenic human disease gene. In view of the findings above, we propose that *PIGP* should be included in the routine genetic testing of individuals with infantile-onset epilepsy and developmental delay.

Acknowledgments

First and foremost, all authors thank the family for participating in the study. MK also wants to thank the “Austrian Society of Neurology” (ÖGN) and the “Austrian Society of Epileptology” (ÖGfE) that each supported him with a 6-months research fellowship. This study was supported by a grant of the German Research Foundation/Deutsche Forschungsgemeinschaft (DI 1731/2-1 to FD) and by a grant of the “Elterninitiative Kinderkrebsklinik e.V.” (Düsseldorf; #701900167).

Conflict of Interest

The authors declare that they have no conflict of interest related to the content of this article.

Author Contribution

MK drafted the manuscript and was involved in genetic data analysis. FD proposed and supervised the case study and was involved in the clinical management. AK performed and interpreted flow cytometry analysis. DS, MW, and TM contributed to the interpretation of genetic data. SBW, TP, FW, MiKa, and EM contributed to clinical data acquisition. All authors read and approved the manuscript before submission.

References

1. pi4K Consortium, Epilepsy Phenome/Genome Project, Allen AS, Berkovic SF, Cossette P, et al. De novo mutations in epileptic encephalopathies. *Nature* 2013;501:217–221.
2. Hamdan FF, Myers CT, Cossette P, et al. High rate of recurrent de novo mutations in developmental and epileptic encephalopathies. *Am J Hum Genet* 2017;101:664–685.
3. Heyne HO, Singh T, Stamberger H, et al. De novo variants in neurodevelopmental disorders with epilepsy. *Nat Genet* 2018;50:1–11.
4. Kinoshita T. Biosynthesis and deficiencies of glycosylphosphatidylinositol. *Proc Jpn Acad Ser B, Phys Biol Sci* 2014;90:130–143.
5. Kato M, Saito H, Murakami Y, et al. PIGA mutations cause early-onset epileptic encephalopathies and distinctive features. *Neurology* 2014;82:1587–1596.
6. Edvardson S, Murakami Y, Nguyen TTM, et al. Mutations in the phosphatidylinositol glycan C (*PIGC*) gene are associated with epilepsy and intellectual disability. *J Med Genet* 2017;54:196–201.
7. Ilkovski B, Pagnamenta AT, O’Grady GL, et al. Mutations in *PIGY*: expanding the phenotype of inherited glycosylphosphatidylinositol deficiencies. *Hum Mol Genet* 2015;24:6146–6159.
8. Fujiwara I, Murakami Y, Niihori T, et al. Mutations in *PIGL* in a patient with Mabry syndrome. *Am J Med Genet A* 2015;167A:777–785.
9. Makrythanasis P, Kato M, Zaki MS, et al. Pathogenic variants in *PIGG* cause intellectual disability with seizures and hypotonia. *Am J Hum Genet* 2016;98:615–626.
10. Johnstone DL, Nguyen TTM, Murakami Y, et al. Compound heterozygous mutations in the gene *PIGP* are associated with early infantile epileptic encephalopathy. *Hum Mol Genet* 2017;26:1706–1715.
11. Kremer LS, Bader DM, Mertes C, et al. Genetic diagnosis of Mendelian disorders via RNA sequencing. *Nat Commun* 2017;8:15824.
12. Sobreira N, Schiettecatte F, Valle D, Hamosh A. GeneMatcher: a matching tool for connecting investigators with an interest in the same gene. *Hum Mutat* 2015;36:928–930.
13. Kinoshita T, Fujita M, Maeda Y. Biosynthesis, remodelling and functions of mammalian GPI-anchored proteins: recent progress. *J Biochem* 2008;144:287–294.
14. van der Crabben SN, Harakalova M, Brilstra EH, et al. Expanding the spectrum of phenotypes associated with germline *PIGA* mutations: a child with developmental delay, accelerated linear growth, facial dysmorphisms, elevated alkaline phosphatase, and progressive CNS abnormalities. *Am J Med Genet A* 2014;164A:29–35.
15. Swoboda KJ, Margraf RL, Carey JC, et al. A novel germline *PIGA* mutation in Ferro-Cerebro-Cutaneous syndrome: a neurodegenerative X-linked epileptic encephalopathy with systemic iron-overload. *Am J Med Genet A* 2014;164A:17–28.
16. Martin HC, Kim GE, Pagnamenta AT, et al. Clinical whole-genome sequencing in severe early-onset epilepsy reveals new genes and improves molecular diagnosis. *Hum Mol Genet* 2014;23:3200–3211.
17. Nakamura K, Osaka H, Murakami Y, et al. *PIGO* mutations in intractable epilepsy and severe developmental delay with mild elevation of alkaline phosphatase levels. *Epilepsia* 2014;55:e13–e17.
18. Nguyen TTM, Murakami Y, Sheridan E, et al. Mutations in *GPAA1*, encoding a GPI transamidase complex protein, cause developmental delay, epilepsy, cerebellar atrophy, and osteopenia. *Am J Hum Genet* 2017;101:856–865.