



Arthroscopic Coracoclavicular and Acromioclavicular Stabilization of Acute Acromioclavicular Joint Dislocation By Suspensory Fixation System

Frank Martetschläger, M.D., Mark Tauber, M.D., Peter Habermeyer, M.D., and Hisham Anis Selim, M.Sc.

Abstract: Arthroscopic stabilization of acute acromioclavicular joint dislocations using coracoclavicular suspension techniques has become more popular, but lack of horizontal stability is a major concern that furthermore affects the final outcome. We present an arthroscopic technique to stabilize acute acromioclavicular joint dislocations in both the vertical and horizontal planes, with better results than conventional coracoclavicular suspension techniques.

Acromioclavicular (AC) joint injuries are common injuries, especially in the young and active male population. AC joint injuries account for 12% of all injuries to the shoulder girdle in the overall population. Particularly, soccer, hockey, football, rugby, biking, and skiing are the most common sports, with the highest prevalence in 20- to 30-year-old patients.¹

There is a wide consensus that Rockwood type I and II AC joint injuries should be treated nonoperatively. The treatment option of Rockwood type III AC joint injuries is still discussed controversially in the literature because clinical studies could not show significant advantages of treatment.^{1,2}

None of the numerous currently existing procedures for the treatment of AC joint dislocations have been proved the overall gold standard. However, modern

arthroscopic techniques have shown reliable results and allow perfect visualization of the coracoid base and management of intra-articular pathology with favorable midterm and long-term follow-up findings.³

However, there is evidence that coracoclavicular (CC) stabilization alone might lead to persistent horizontal instability of the AC joint in a high percentage of patients.⁴⁻⁶ Furthermore, a biomechanical study has shown that native horizontal stability can only be restored by using an additional AC cerclage technique.⁷ Therefore, not only the vertical component but also the horizontal component of AC joint instability has gained more attention over the past few years. To address both components, we present our arthroscopically assisted technique to stabilize the AC joint in both the vertical and horizontal planes with a titanium button–tape construct (Table 1).

Surgical Technique

The surgical technique is shown in Video 1.

Anesthesia and Patient Positioning

We use general anesthesia with an interscalene block for improved postoperative analgesia. The patient is positioned in the beach-chair position with a special emphasis on sufficient access to the clavicle for placement of the clavicular bone tunnel. The head is turned slightly to the opposite direction. The access of the C-arm should be checked. The anatomic landmarks are identified and marked on the skin.

General Arthroscopic Examination and Portals

General arthroscopic examination is performed using a 30° scope from the posterior portal to detect any

From the Department of Shoulder and Elbow Surgery, ATOS Clinic Munich (F.M., M.T., P.H.), Munich, Germany; Department of Orthopedics Sports Medicine, Klinikum Rechts der Isar, Technical University Munich (F.M.), Munich, Germany; Department of Traumatology and Sports Injuries, Paracelsus Medical University (M.T.), Salzburg, Austria; and Shoulder Arthroscopy and Sports Medicine Unit, Orthopedics Department, Zagazig University Hospital (H.A.S.), Zagazig, Egypt.

The authors report the following potential conflicts of interest or sources of funding: F.M. receives support from Arthrex. M.T. receives support from Arthrex. P.H. receives support from Arthrex. Full ICMJE author disclosure forms are available for this article online, as supplementary material.

Received December 19, 2018; accepted February 3, 2019.

Address correspondence to Frank Martetschläger, M.D., Department of Shoulder and Elbow Surgery, ATOS Clinic, Effnerstraße 38, 81925 München, Germany. E-mail: fmartetschlaeger@gmail.com

© 2019 by the Arthroscopy Association of North America. Published by Elsevier. This is an open access article under the CC BY-NC-ND license (<http://creativecommons.org/licenses/by-nc-nd/4.0/>).

2212-6287/181538

<https://doi.org/10.1016/j.eats.2019.02.002>

Table 1. Advantages and Disadvantages

Advantages	Disadvantages
<ul style="list-style-type: none"> • Restoration of both vertical instability and horizontal instability of AC joint • Arthroscopically assisted technique with less soft-tissue dissection • No need for anchors, so less cost of implants • Diagnosis and treatment of associated pathology • No need for implant removal • Use of small 2.4-mm tunnels for less risk of fracture 	<ul style="list-style-type: none"> • Only for experienced arthroscopists • Requirement for learning curve and more surgical time

AC, acromioclavicular.

associated intra-articular pathology (e.g., SLAP lesions). A deep anterolateral portal is established by an outside-in technique through the rotator interval and parallel to the subscapularis tendon and is secured with a silicone cannula (e.g., 10-mm PassPort Cannula; Arthrex) (Fig 1A).

Coracoid Base Visualization and Exposure

For optimal visualization of the medial part of the coracoid base, the surgeon switches the arthroscope to a trans-supraspinatus portal directly posterior to the long head of the biceps tendon and lateral to the rotator cable (Fig 1B) while working through the deep antero-inferior portal for coracoid base skeletonization using a radiofrequency ablation device.

CC Drilling and Fixation

With a 2-cm skin incision over the clavicle about 3.5 to 4.5 cm from the AC joint line and approximately centered over the middle of the coracoid process, the surgeon should position the AC guide under the middle of the posterior part of the coracoid base (Fig 2A) and on the superior surface of the clavicle but should avoid

being eccentric to avoid cortical breakage and tunnel blowout (Table 2). A 2.4-mm cannulated drill is used (Fig 2B), and then a nitinol wire (SutureLasso; Arthrex) is used to pull the 2 tapes (1 blue and 1 white) out through the supraclavicular approach, thus placing the titanium button (Dog Bone; Arthrex) underneath the coracoid process (Fig 2C and D).

The AC joint is thoroughly reduced beforehand in the vertical and horizontal planes by lifting the arm with the help of an automatic arm holder, pushing from upward on the clavicle, and manipulating the scapula. Correct reduction is checked radiographically. After final control of reduction, both tapes are tied over the clavicular titanium button and left in place to use them for additional AC cerclage.

Arthroscopic AC Cerclage (Subacromial Debridement, Acromial Tunnel Drilling, Passage of Tape)

Through the anterolateral portal, a radiofrequency device is used for exposure of the undersurface of the acromion, and 2 vertically oriented drill holes through the acromion are made about 1.5 cm from the AC joint line with the 2.4-mm drill (Fig 3A and B). Again, a shuttle wire is inserted, and an artery forceps is passed subcutaneously to grasp the 2 strands of the blue tape and shuttle them through the acromion by pulling the shuttle wire through the anterolateral portal (Fig 4A).

A second drill hole is made posterior to the previous one and in line with the posterior edge of the lateral clavicle (Fig 3C and D). The tapes are then passed back subcutaneously and pulled out through the supraclavicular approach (Fig 4B). Finally, both strands of the tapes are tied and secured to the remaining strands of the white tape (Fig 4C). Closure of wounds is meticulously performed in layers. An abduction sling at 45° is used with passive range of motion for 6 weeks.

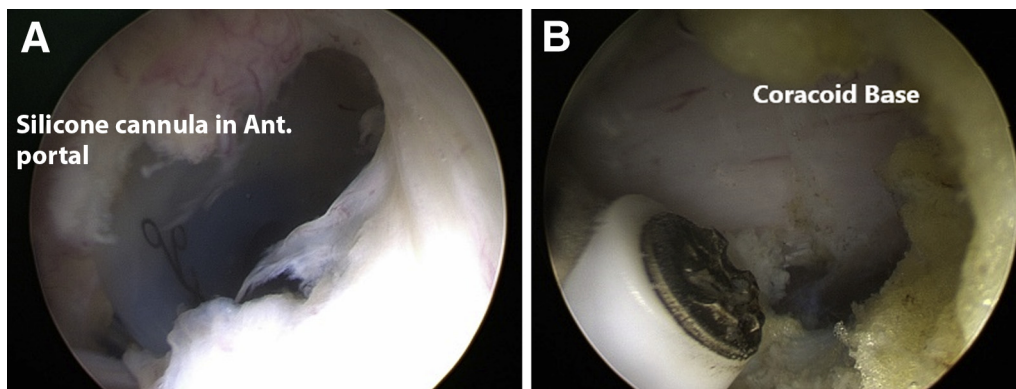


Fig 1. (A) Arthroscopic view of left shoulder in beach-chair position showing establishment of anterolateral (Ant) portal secured with silicone cannula. (B) Switch to lateral trans-supraspinatus portal for better visualization of coracoid and preparation of coracoid base using radiofrequency ablation device.

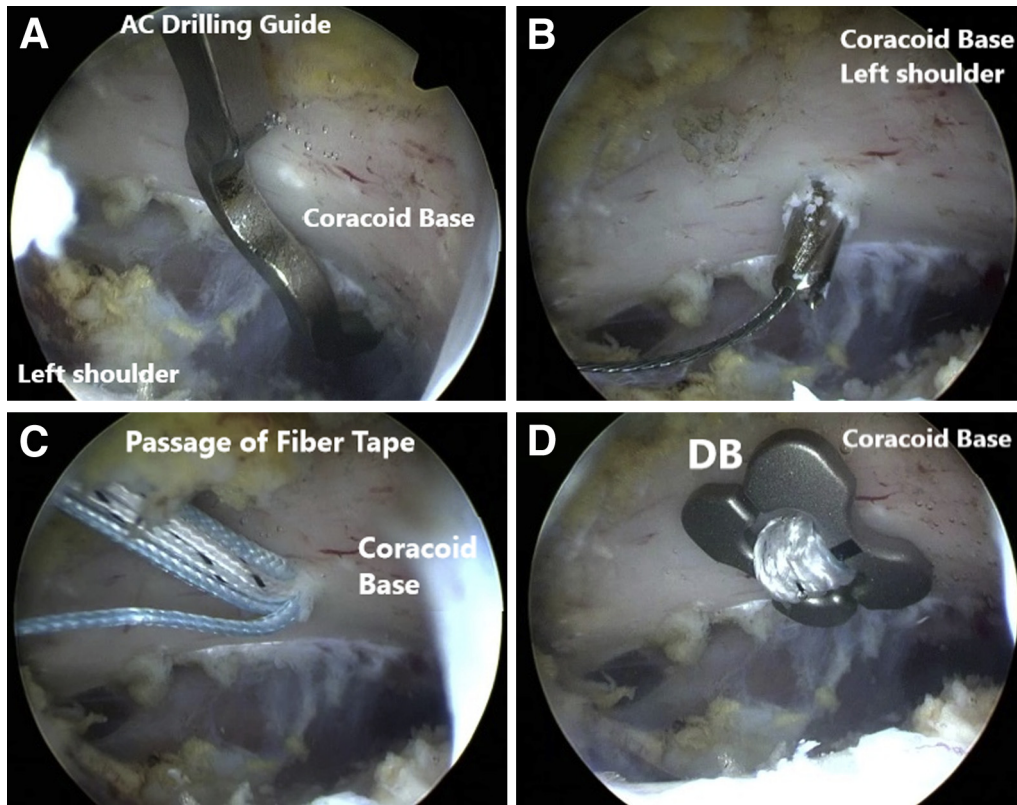


Fig 2. Arthroscopic coracoclavicular stabilization with Dog Bone fiber tape for left-sided, acute acromioclavicular (AC) joint dislocation while viewing through lateral trans-supraspinatus portal. (A) Preparation of coracoid base using radiofrequency ablation device. (B) Proper positioning of drill guide under coracoid base. (C) Drilling of coracoclavicular tunnel with 2.4-mm drill and passage of shuttle wire. (D) Passage of fiber tapes through tunnel and placement of Dog Bone (DB) beneath coracoid base.

Discussion

Many surgical techniques have been described for the treatment of AC joint dislocations. Still, there is no gold-standard method. The arthroscopically assisted stabilization technique represents a minimally invasive method to augment the torn conoid and trapezoid ligaments in acute AC joint separations with no need for implant removal and with better visualization of the coracoid base.¹

Patzer et al.⁸ showed that only 1 bone tunnel for CC reconstruction can provide comparable clinical results. Beitzel et al.⁹ reported that there was no significant difference between single- and double-clavicular tunnel techniques regarding stability imparted to the AC joint. In addition, in a recent biomechanical study, Banffy et al.¹⁰ reported that single-tunnel CC ligament reconstruction showed biomechanical properties comparable to the intact state and similar to the double-tunnel ligament reconstruction technique while theoretically posing less risk of clavicle fracture.

The Dog Bone offers a larger contact area than the TightRope (Arthrex) and smaller CC tunnels, less risk of fracture, and a lower incidence of cortical osteolysis, as well as implant migration, and therefore might lead to a lower

incidence of postoperative loss of reduction. In addition, the tape (braided composite polyethylene and polyester sutures) provides a larger cross-sectional area than FiberWire (Arthrex) and greater ultimate load to failure.¹¹

Regarding the additional horizontal stabilization, Scheibel et al.⁴ described persistent horizontal instability in 41% of cases after isolated CC double-ligament stabilization. Saier et al.⁷ showed biomechanically that only combined AC and CC reconstruction could adequately restore physiological horizontal AC joint stability. Therefore, when surgeons are performing AC

Table 2. Pearls and Pitfalls

The lateral portal should be used for better visualization of the coracoid base.
The surgeon should avoid dissection medial to the coracoid to avoid injury to the brachial plexus.
The AC guide should be correctly directed for coracoclavicular drilling: posterior third of clavicle and close to coracoid base.
Fluoroscopy should be used to ensure correct drilling and reduction of the AC joint.
Thorough subcoracoid and subacromial debridement is necessary before drilling.
The deltotrapezial fascia should be carefully reconstructed.
AC, acromioclavicular.

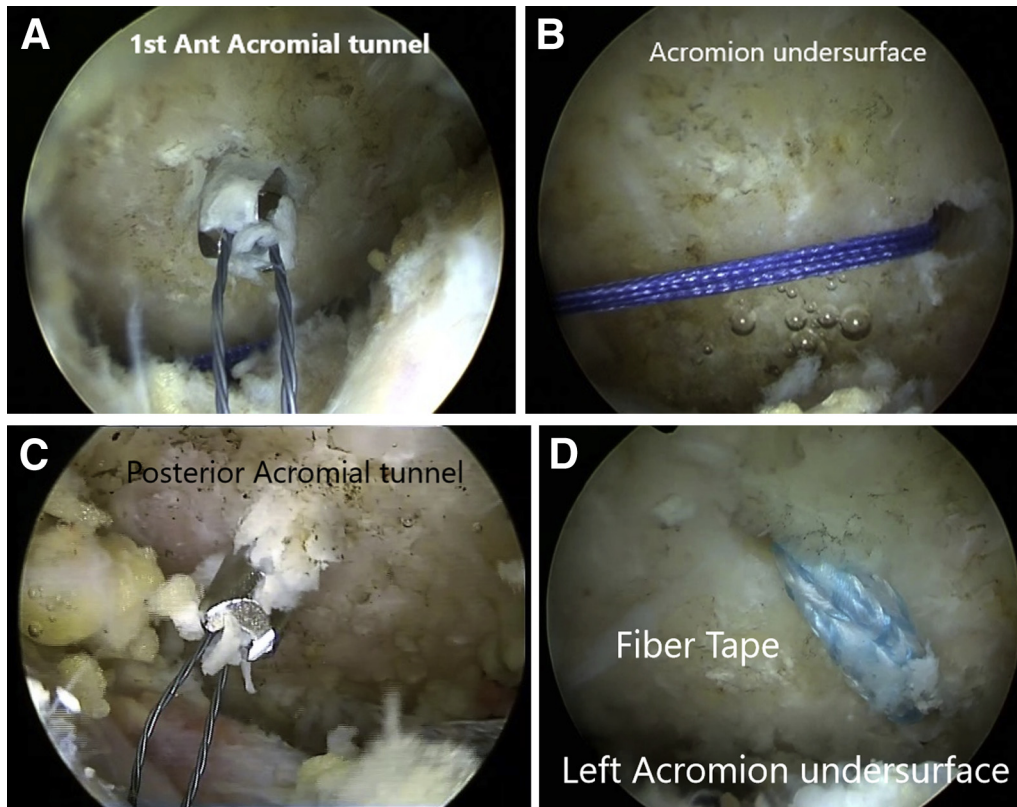


Fig 3. Arthroscopic view of subacromial space showing steps of acromioclavicular (AC) cerclage of left shoulder in beach-chair position while viewing through lateral portal. (A) Drilling of first, "anterior" (Ant) acromial tunnel. (B) Passage of shuttle suture. (C) Drilling of second, "posterior" acromial tunnel. (D) Shuttling of fiber tape from first to second tunnel and final arthroscopic view of AC cerclage from subacromial space.

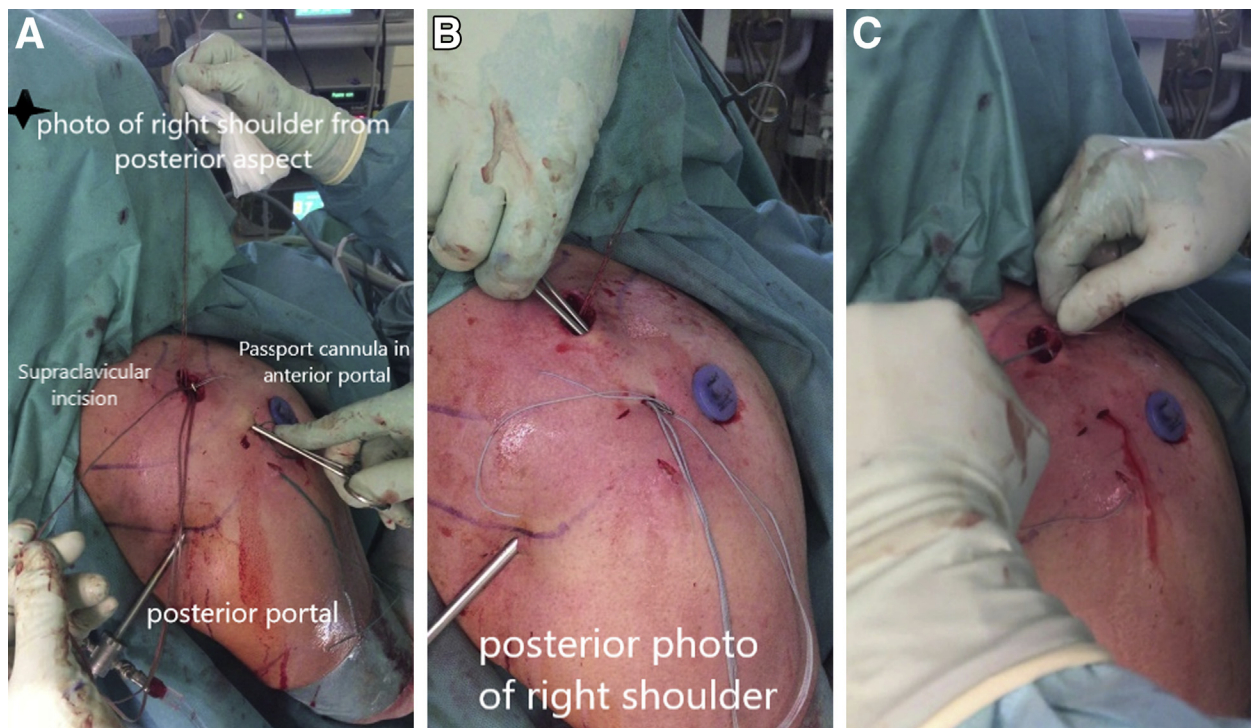


Fig 4. Outside view of right shoulder from behind with scope in posterior portal and silicone (PassPort) cannula in anterosuperior portal showing steps of acromioclavicular (AC) cerclage in beach-chair position. (A) The fiber tape is retrieved using a hemostat from the supraclavicular incision to the first acromial tunnel. (B) After passage of the fiber tapes through the acromion, the tapes are shuttled back to the clavicular incision. (C) Tying of both fiber tapes together—"final construct."

joint stabilization in high-grade type IV or V injuries, the horizontal component should be addressed to create the best possible stability. The true clinical value, however, needs to be investigated in future studies.

This procedure is technically demanding and needs a learning curve, but the risk of fracture of the coracoid or clavicle is minimized by using small tunnels and proper technique. Overall, arthroscopically assisted combined CC and AC stabilization has provided excellent clinical results without observation of a fracture in the distal clavicle, coracoid, or acromion over the past 4 years.

References

1. Braun S, Martetschläger F, Imhoff AB. Acromioclavicular joint injuries and reconstruction. In: Doral NM, Karlsson J, eds. *Sports injuries: Prevention, diagnosis, treatment and rehabilitation*. Berlin: Springer, 2015;1-12.
2. Beitzel K, Cote MP, Apostolakos J, et al. Current concepts in the treatment of acromioclavicular joint dislocations. *Arthroscopy* 2013;29:387-397.
3. Venjakob AJ, Salzmann GM, Gabel F, et al. Arthroscopically assisted 2-bundle anatomic reduction of acute acromioclavicular joint separations: 58-month findings. *Am J Sports Med* 2013;41:615-621.
4. Scheibel M, Droschel S, Gerhardt C, Kraus N. Arthroscopically assisted stabilization of acute high-grade acromioclavicular joint separations. *Am J Sports Med* 2011;39:1507-1516.
5. Barth J, Duparc F, Andrieu K, et al. Is coracoclavicular stabilisation alone sufficient for the endoscopic treatment of severe acromioclavicular joint dislocation (Rockwood types III, IV, and V)? *Orthop Traumatol Surg Res* 2015;101:S297-S303 (suppl).
6. Hann C, Kraus N, Minkus M, Maziak N, Scheibel M. Combined arthroscopically assisted coraco- and acromioclavicular stabilization of acute high-grade acromioclavicular joint separations. *Knee Surg Sports Traumatol Arthrosc* 2018;26:212-220.
7. Saier T, Venjakob AJ, Minzlaff P, et al. Value of additional acromioclavicular cerclage for horizontal stability in complete acromioclavicular separation: A biomechanical study. *Knee Surg Sports Traumatol Arthrosc* 2015;23:1498-1505.
8. Patzer T, Clauss C, Kuhne CA, et al. Arthroscopically assisted reduction of acute acromioclavicular joint separations: Comparison of clinical and radiological results of single versus double TightRope technique. *Unfallchirurg* 2013;116:442-450 [in German].
9. Beitzel K, Obopilwe E, Chowaniec DM, et al. Biomechanical comparison of arthroscopic repairs for acromioclavicular joint instability: Suture button systems without biological augmentation. *Am J Sports Med* 2011;39:2218-2225.
10. Banffy MB, Uquillas C, Neumann JA, ElAttrache NS. Biomechanical evaluation of a single- versus double-tunnel coracoclavicular ligament reconstruction with acromioclavicular stabilization for acromioclavicular joint injuries. *Am J Sports Med* 2018;46:1070-1076.
11. Vulliet P, Le Hanneur M, Cladiere V, Loriaut P, Boyer P. A comparison between two double-button endoscopically assisted surgical techniques for the treatment of acute acromioclavicular dislocation. *Musculoskelet Surg* 2018;102:73-79.