Städt. Krankenhaus München-Bogenhausen

Abteilung für Plastische, Rekonstruktive und Handchirurgie,
Zentrum für Schwerbrandverletzte

Akademisches Lehrkrankenhaus der Technischen Universität München

(Direktor: Univ.-Prof. Dr. M. Ninkovic)

Surgical Management of Pancraniofacial Synostosis and Kleeblattschädel – Analysis of 19 own cases and review of the literature

Frank Reinhard Gräwe

Vollständiger Abdruck der von der Fakultät für Medizin der Technischen Universität München zur Erlangung des Akademischen Grades eines Doktors der Medizin genehmigten Dissertation.

Vorsitzender: Univ-Prof. Dr. D. Neumeier

Prüfer der Dissertation: 1. apl.Prof. Dr. W. Mühlbauer

2. Univ-Prof. Dr. E. Biemer

Die Dissertation wurde am 08.03.2004 bei der Technischen Universität München eingereicht und durch die Fakultät für Medizin am 22.07.2004 angenommen.

INDEX AND CONTENTS

1 Introduction and purpose of this study: 3
1.1 Introduction: 3
1.2 Aim of this study: 3
2 Background: 4
2.1 Craniofacial Deformities: 4
2.1.1 History: 4
2.1.2 Pathophysiology: 4
2.1.3 Incidence: 7
2.1.4 Genetics: 7
2.1.5 Classification of craniofacial malformations: 8
2.1.6 General information: 10
2.1.7 Surgical management: 12
2.2 Kleeblattschädel: 20
2.2.1 Definition: 20
2.2.2 Aetiology 21
2.2.3 History 24
2.2.4 Classifications: 26
2.2.5 Pathophysiology 28
3 Patients and Methods: 32
4 Our Surgical Management: 34
4.1 Timing and Choice of Procedure: 34
4.2 Surgical Technique: 35
4.2.1 Frontal-orbital advancement (FOM) 37
4.2.2 Total cranial vault remodelling (Subtotal Craniectomy): 38
4.2.3 Midface osteotomies and advancement: 39
5 Results: 43
6 Discussion: 61
6.1 Review of literature 61
6.2 Discussion of techniques 70
7 Conclusion: 75
8 Summary: 77
8.1 Summary 77
8.2 Zusammenfassung 78
9 References: 79
10 Danksagung: 87
11 Vita: Frank R. Gräwe 88

Surgical Management of Pancraniofacial Synostosis and Kleeblattschädel – Analysis of 19 own cases and review of the literature

1 Introduction and purpose of this study:

1.1 Introduction:

Kleeblattschädel (**Holtermüller and Wiedemann, 1960**) is the German expression for cloverleaf skull. It was used for the first time in 1881 by Schott to describe the morphologic appearance of one of the most severe craniofacial deformities known (**Schott, 1881**). The skull shape resembles a cloverleaf with the typical trilobar appearance when seen from the front or behind. Craniosynostosis is the condition of premature fusion of cranial sutures in the newborn skull. Kleeblattschädel is one of the most severe forms of craniosynostosis and is caused by premature fusion of multiple or all skull sutures. In this condition cranial sutures close already in utero and the children are born with the typical trilobar skull deformity. Kleeblattschädel deformity is a potentially life-threatening condition that in many cases necessitates emergency intracranial surgery, sometimes even in the very first days of neonatal life. Emergency situations arise with increased intracranial pressure and hydrocephalus, severe exorbitism and prolaps of the orbital contents or with respiratory problems and upper airway obstruction due to severe midfacial hypoplasia.

1.2 Aim of this study:

This is a retrospective view into our unique experience with this rare condition. We have evaluated and treated a total of nineteen patients with the Kleeblattschädel deformity at the Craniofacial Unit in Munich since 1978. Sixteen patients underwent extensive craniofacial procedures. The surgical management and outcome of our cases is presented and discussed. A review of the literature concerning Kleeblattschädel deformity is presented and discussed with a special emphasis on surgical treatment. Guidelines for the surgical management are proposed and discussed.

2 Background:

2.1 Craniofacial Deformities:

2.1.1 History:

Hippocrates, in 100 BC, noted variability of calvarial deformities and correlated it with the pattern of cranial suture fusion (**Montaut and Stricker, 1977**). Celsus (25 B.C. to 50 A.D.) also described skulls with lacking cranial sutures (**Laitinen 1956**). Oribasios, a Greek physician, reported the presence of cranial deformities in association with palatine deformities (**Bussemaker and Daremberg, 1858**).

In 1557, Lycosthene described an infant with a deformity of the skull and limbs, the syndrome of acrocephalosyndactyly, subsequently described by Apert in 1906 (**McCarthy et al., 1990**).

2.1.2 Pathophysiology:

Sommerring made some early observations on the pathogenesis of craniosynostosis in 1791 (**Sommerring, 1839**). He observed that bone growth in the skull occurs at suture lines, and when these sutures are fused prematurely, growth is reduced in a plane perpendicular to the suture's axis. Both Otto in 1831 (**Otto, 1830**), and Virchow in 1851 (**Virchow, 1851**) corroborated these observations. Virchow further developed Otto's ideas, who described craniosynostosis in both humans and animals. What has generally become known as Virchow's law, states that skull growth is arrested in a perpendicular direction to the closed suture and compensatory overexpansion takes place at patent suture sites. These observations have served as the principal guide in understanding craniosynostosis.
In 1856, Minchin, a Scottish physician, reported two cases of sagittal synostosis. In 1866, von Graefe reported an eight-year-old boy with turrycephaly. In 1890, the French surgeon Lannelongue reported an operation in which he cut channels along the margins of a fused sagittal suture. In 1892, Lane reported a similar operation.

Van der Klaauw and Moss (**Klaauw, 1946 and Moss, 1959**), on the other hand, proposed that the cranial base was the locus of the primary abnormality rather than the calvarial suture. Moss argued that cranial base deformity caused secondary growth disturbances at the calvarial suture, with brain enlargement serving as the primary driving force for expansion and shaping in the skull. Additional modifications in craniofacial shape are induced by the development of the respiratory and digestive tracts. This concept is described as the "functional matrix" theory (**Moss, 1969 and 1975**). Burdi et al. also implicate the cranial base as the primary site of abnormality and it is postulated that coronal synostosis results from closure along the coronal ring, which consists of the coronal, frontosphenoid, and frontoethmoid sutures (**Burdi et al., 1986**).

Subsequently, several investigators have studied the effect of premature closure of a cranial vault suture on the development of the skull. Persson and associates, and others, have reported that with selective restriction of individual cranial vault sutures in animal studies, skull deformities developed that closely mimicked the clinical conditions of "synostosis" of the same cranial vault suture in humans (**Babler and Persing, 1982**) (**Babler et al., 1985**) (**Persing, 1986**) (**Persson et al., 1979**). Moreover, cranial base abnormalities, and deformities of the facial skeleton, developed secondary to the cranial vault suture restrictions. Further supportive evidence for the primacy of cranial vault suture pathology in most cases of non-syndromic craniosynostosis comes from the clinical observation by Marsh and Vannier that previously developed cranial base abnormalities were ameliorated, following cranioplasty. Only the cranial vault structure was altered surgically during cranioplasty in patients with individual suture craniosynostosis (**Marsh and Vannier, 1986**) (**Hardesty et al., 1991**).

More recently Opperman, Ogle, Longaker, and others have demonstrated developmental and biologic abnormalities in prematurely fusing sutures (**Duncan et al., 1992**) (**Longaker et al., 1992**) (**Opperman et al., 1993**). Delashaw noted that bone growth occurs at perimeter sutures with increased bone deposition directed away from the abnormally fused bone plate. This is the cause of the contralateral frontal bone bossing in unilateral coronal suture craniosynostosis as well as bilateral temporal bulges, which are characteristic for the morphology in clover leaf skull. He also noted that sutures adjacent to the prematurely fused sutures compensate in growth more than sutures distant to the fused suture (**Delashaw et al,**

1989). Moss states in his 'dural hypothesis' that there is a spatial malpositioning at five basal points of dural attachment. These five points of dural attachement are at the crista galli, the crest of the optic capsule bilaterally, and the superior edges of the lesser wings of the sphenoid bone bilaterally. He suggests that there are abnormally transmitted tensile stresses, which are the stimulus for osteogenesis at the suture (**Moss, 1975**).

A possible clue to the aetiology of synostosis may be found by understanding the metabolic and teratogenic factors that can produce synostosis. For example, hyperthyroidism is associated with craniosynostosis. Conversely, sutures remain open longer than normal in hypothyroidism (**Cohen et al., 1993**). Exposure to Warfarin in utero may produce a syndrome similar to Crouzon, with reduced anterior - posterior size, exorbitism, and maxillary hypoplasia. Finally synostosis may result from insufficient brain growth. The lack of growth of the brain causes lack of stretch across the cranial suture and results in fusion of the suture.
Animal models may ultimately help to better elucidate the causes of craniosynostosis in humans. Craniosynostosis was reported by Greene in a rabbit model (**Greene, 1933**). More recently, Mooney et al. identified a rabbit with craniosynostosis and bred a colony (**Mooney et al., 1993**) (**Mooney et al., 1994**). It was an autosomal dominant strain with variable penetrance. In some rabbits there was a complete craniosynostosis and in others it was partial. In the same colony there was unilateral or bilateral craniosynostosis.

Finally, studies of the craniosynostotic bone cells in vitro reveal that the population doubling time of these cells is longer than normal suture cells. This suggests that suppression by one of the osteoblast-derived growth factors (IGF-I, IGF-II, TGF-b1, PDGF, and bFGF) may play an important role. In most craniosynostosis syndromes one or more specific deficient growth factors and the corresponding genes can be already traced.

2.1.3 Incidence:

Craniosynostosis occurs in 1 in 2000 births (**Hockley, 1993**). In 10% to 20% of cases there is evidence of inheritance. Bilateral coronal suture synostosis occurs in 18%. In half of these it occurs as part of a complex syndrome. Apert syndrome occurs in 15.5 of 1.000.000 births and Crouzon syndrome in 1 of 60.000 births (**Cohen, 1986**). Trigonocephaly occurs in fewer than 10% and lambdoid suture craniosynostosis in less than 5% of all synostosis cases (**Sadove et al., 1990**). Kleeblattschädel deformity is the rarest of these conditions, with less than 130 cases described in the literature (**Goh et al., 1997**).

2.1.4 Genetics:

It was mentioned already, that in about 10% to 20% of cases there is evidence of inheritance. Furthermore there is a group of syndromic cases (**Table 1**) with a known pattern of inheritance, which comprises about 5% to 10% of all cases. Craniosynostosis may be associated with many syndromes, Cohen has delineated 90 syndromes, but there are a few which are most common (**Cohen, 1993**) (**Cohen et al., 1993**).

The gene for Crouzon's syndrome was mapped to chromosome 10 (**Preston et al., 1985**). After it was found that achondroplasia was caused by a mutation of the fibroblast growth factor receptor 3 gene (FGFR3), Crouzon's syndrome was identified to be caused by mutation of fibroblast growth factor receptor 2 gene (FGFR2) (**Reardon et al., 1994**). Apert's syndrome and Jackson Weiss syndrome were also mapped to chromosome 10 and found to be caused by a mutation of the fibroblast growth factor receptor 2 genes (**Jabs et al., 1994**). The gene for Pfeiffer syndrome was mapped to chromosomes 8 and 10 and caused by a mutation of the fibroblast growth factor receptor 1 or 2 gene (**Muenke and Schell, 1994**).

Syndrome:	Inheritence:
Saethre-Chotzen syndrome	Autosomal dominant
Crouzon syndrome	Autosomal dominant
Apert syndrome	Autosomal dominant
Pfeiffer syndrome	Autosomal dominant
Baller Gerhold syndrome	Autosomal recessive
Carpenter syndrome	Autosomal recessive

Table 1: Common craniofacial disorders and their mode of inheritance

2.1.5 Classification of craniofacial malformations:

A variety of different classifications for craniofacial malformations exist. The following classification illustrates the wide spectrum of craniofacial disorders.

I. Craniosynostosis

1. *Primary*

a. Non-syndromic (isolated)

(1) Single suture

i. Scaphocephaly (sagittal suture)

ii. Trigonocephaly (metopic)

iii. Plagiocephaly

a) frontal plagiocephaly (unilateral coronal)

b) occipital plagiocephaly (unilateral lambdoid)

(2) Multiple suture

i. Acrocephaly

a) Turrycephaly

b) Pyrgocephaly

ii. Oxycephaly

iii. Clover leaf skull

iv. Brachycephaly

b. Syndromic

(1) Crouzon

(2) Apert

(3) Pfeiffer

(4) Saethre-Chotzen

(5) Carpenter

2. Secondary

Results of another disorder, e.g. braindisorders

II. Facial Synostosis

1. Vomeropremaxillary dysostosis (Binder's-Syndrome)
2. Premaxillary dysostosis (Pseudo-Crouzon)

III. Facial Clefts

1. Cleft lip and Palate
2. Craniofacial Clefts (Tessier)

IV. Laterofacial Microsomias

1. Treacher-Collins Syndrome (Mandibulofacial dysostosis)
2. Unilateral facial microsomia
3. Goldenhar-Syndrome (Oculo-auriculo-vertebral dysplasia)

V. Meningoencephaloceles

1. Occipital
2. Parietal
3. Basal
4. syncipital:

a. fronto-ethmoidal

(1) nasofrontal

(2) nasoethmoidal

(3) nasoorbital

b. interfrontal

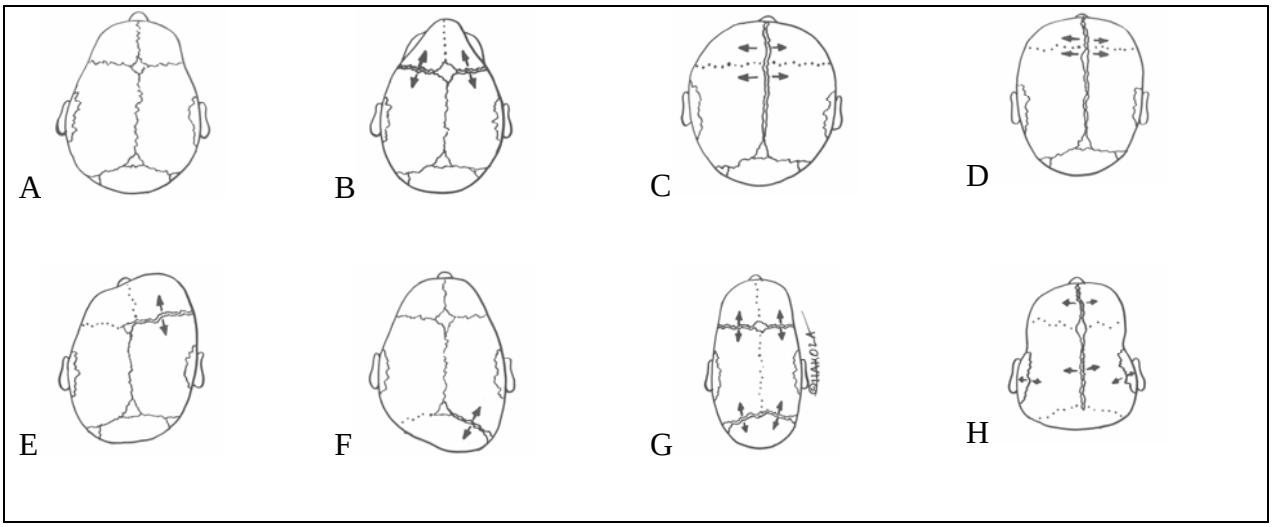

Figure 1: A: Normocephaly; B: Trigonocephaly (Metopic Synostosis); C: Brachycephaly (Bilateral Coronal Synostosis e.g. Crouzon's Syndrome); D: Oxycephaly (Late Bicoronal Synostosis or secondary or inadequately released bicoronal synostosis); E: Anterior Plagiocephaly (Unilateral Coronal Synostosis); Posterior Plagiocephaly (Unilateral Lambdoidal Synostosis); F: Scaphocephaly (Sagittal Suture Synostosis); G: Kleeblattschädel Anomaly (Bilateral Coronal and Bilateral Lambdoidal Synostosis)

2.1.6 General information:

Craniosynostosis is the process of premature fusion of cranial sutures, craniostenosis on the other hand, is the result. The cranial vault is composed of a series of bone plates, the junctions of which constitute the cranial sutures (**Figure 1**). The major cranial sutures are the metopic, sagittal, coronal, and lambdoid sutures. A partial list of other minor sutures includes the temporosquamosal, the frontonasal, and the frontosphenoidal. Facial sutures (except for the midpalatal suture) remain patent till the seventh decade, but skull sutures fuse early (**Table 2**). Skull sutures close from front to back and from lateral to medial (**Albright and Byrd, 1981**). The metopic suture begins to fuse at 2 years and is usually completely closed by 3 years, but it persists throughout life in 10% of humans. Cranial sutures function as a shock-absorbing site in childhood and fuse early in life. In addition, the cranial sutures allow the bones to overlap during passage through the birth canal and are the principal sites where

expansion of the skull occurs. Facial sutures have a shock-absorbing function related to the muscles of mastication and close later in life.

Suture	**Closure begins in years**
Metopic	2
Sagittal	22
Coronal	24
Lamdoid	26
Palatal	30-35
Frontonasal	68
Frontozygomatic	72

Table 2: Age of suture closure (Cohen MM. Am J Med Genetics 47:581, 1993)

Detectable cranial abnormalities secondary to craniosynostosis occur in approximately 1 in every 1,700 to 1,900 births (**Cohen, 1979**). In some cases, brain growth is retarded by prolonged restriction of the cranial vault secondary to fusion of the overlying sutures (**Foley and Kovich, 1957**). In most cases, fusion of a solitary suture does not result in neurologic impairment by currently available measuring techniques. When multiple sutures are involved, the possibility of compression of underlying brain increases significantly (**Renier, 1989**).

Some cases of craniosynostosis are not detectable at birth because the manifestations may be mild. When craniosynostosis is suspected, a craniofacial team should evaluate the infant.
The most common types of craniosynostosis are (1) sagittal suture synostosis producing a scaphocephaly deformity, (2) metopic suture synostosis producing a trigonocephaly deformity, (3) unilateral coronal suture synostosis resulting in an anterior plagiocephaly deformity, and (4) bilateral coronal synostosis resulting in a brachycephaly deformity (see 2.1.5: Classification). True posterior plagiocephaly due to lambdoid suture synostosis is a distinctly uncommon condition. Positional or deformational posterior plagiocephaly of the

occiput (a non-craniosynostotic, self-correcting deformity) is frequently seen and must be distinguished from true craniosynostosis.

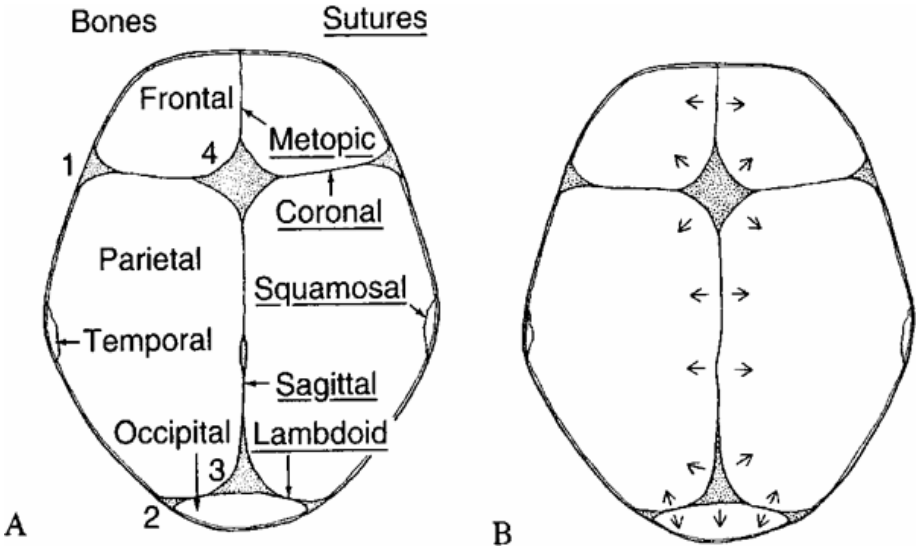

Figure 2: A: Major cranial sutures. B: Growth of the brain that is reflected in expansion of the cranial vault is always perpendicular to cranial sutures as demonstrated by arrows. (From Carson, B. S., and Dufresne, C. R. Craniosynostosis and Neurocranial Asymmetry. In C. R. Dufresne, B. S. Carson, S. J. Zinreich, (eds.). Complex Craniofacial Problems. New York: Churchill Livingstone, 1992. P. 169.)

2.1.7 Surgical management:

2.1.7.1 General:

Children with craniosynostosis should be evaluated by a craniofacial team, consisting of a plastic surgeon, neurosurgeon, ophtalmologist, and geneticist. According to the diagnosis, they should be seen by an otolaryngologist, orthodontist, speech pathologist, audiologist, and a social worker.

At many craniofacial centres surgery for sagittal synostosis is performed at three to six months of age. Frontoorbital and cranial vault remodelling is performed at about 6 to 12 months of age. However, some surgeons believe that the surgery should be performed earlier to lesson the likelihood of the craniosynostosis affecting mental development (**Shillito, 1992**) or to improve the possibility for dynamic remodelling and decrease morbidity (**Mühlbauer et al, 1989**). Conversely, others believe that the surgery should be delayed until after the first

year of age. With synostosis of a single suture, there is a 7% to 18% chance of increased intracranial pressure and an adverse effect on mental development (**Renier et al., 1987**). When multiple sutures are involved, the risk increases. The goals of therapy are to release the craniosynostosis and to provide adequate skull volume to allow the brain to develop to its maximal potential. Another important goal is to create an aesthetically normal forehead and skull that will remain normal in shape as the child grows. An aesthetically unacceptable appearance at this young age can lead to a variety of developmental and psychosocial disorders, if left untreated. It is essential to exclude deformational skull deformity. In these cases that are frequent in posterior plagiocephaly, surgery is contraindicated until non-surgical options have been pursued. In some cases with mild or partial craniosynostosis, especially in cases with metopic and lambdoid suture synostosis, a conservative wait and see attitude can be indicated.

When craniosynostosis is severe and early, as in Kleeblattschädel, release of the constricted skull can become a medical urgency. In some cases emergency surgery for cranial decompression need to be performed during the first few days of life. If there is evidence of hydrocephalus, a shunt procedure is indicated.

2.1.7.2 History:

The surgical treatment of patients with craniosynostosis syndromes dates from the late nineteenth century, when the first techniques were aimed at correcting only the functional aspects of the deformity. The earliest techniques described are linear craniectomy and fragmentation of the cranial vault. In some of the more severe deformities these techniques have been used to provide temporary brain and eye protection until a more definitive elective craniofacial procedure can be undertaken. Simple craniectomy or morcellation performed in infancy, is accompanied by a high rate of reossification. Only modest results are usually obtained, when mobilization of the orbits and midface is not performed concurrently. Additionally, the reossified bone is of poor quality and makes definitive correction at a later stage more difficult. In 1967, Tessier who is the father of craniofacial surgery, first published his results following correction of the recessed forehead and supraorbital regions using an intracranial approach that allowed accurate osteotomy, mobilization, and repositioning (**Tessier, 1967**). The current surgical treatment approach for children with syndromic craniosynostosis and accompanying midface deficiency involves an initial frontal-orbital and

cranial vault remodelling. In selected cases a midface advancement procedure (Le Fort III or monobloc) is performed at a later stage, and secondary orthognathic surgery to correct any dentofacial deformities (Le Fort I, mandibular osteotomies, and genioplasty).

Surgical intervention for the correction of craniofacial deformities in patients with syndromic craniosynostosis can be divided into those procedures that are performed early in life (6 to 12 months) for suture release, cranial vault decompression, and upper orbital reshaping and advancement and those that are performed at a later age (6 to 12 years) for midface deformities and jaw surgery (14 to 18 years). The exact timing and sequence for each of the surgical procedures is dependent on both the functional and the psychological needs of the patient (**Table 2**). Controversy still exists on optimal timing of midface osteotomies. Two main approaches are currently practiced: (1) waiting until all midface and lower face growth is complete before doing a definitive osteotomy and advancement, and (2) performing a midface advancement in late childhood with the realization that a second advancement will be necessary when mandibular growth is complete. However, with the reinvention of distraction osteogenesis for the craniofacial skeleton, midface advancement is currently performed at a much younger age with good and promising results.

2.1.7.3 Distraction of the craniofacial skeleton:

A new dimension in treating craniofacial deformities was added by the use of distraction osteogenesis in the craniofacial skeleton. Distraction osteogenesis is a technique in which bone can be lengthened by de novo bone formation as part of the normal healing process that occurs between surgically osteotomised bone segments that undergo gradual, controlled distraction. Compared to conventional approaches, the ability of the soft tissue envelope to accommodate the gradual expansion of the underlying skeletal framework is unique in craniofacial distraction. The soft tissue is not only stretched out but new tissue is generated including the neurovascular structures involved. This technique today is an important part of the reconstructive surgeon's armamentarium.

2.1.7.3.1 History:

Distraction osteogenesis, although used for several decades by orthopaedic surgeons to repair long bone defects, is only recently gaining acceptance for correction of various craniofacial deformities. Bone distraction is not a new concept. Distraction was introduced first by Codvilla nearly a hundred years ago and subsequently was popularised during the 1940's by Ilizarov, who developed a single-stage procedure to lengthen long bones without the use of grafting material. The feasibility of applying Ilizarov's principles to different craniofacial deformities was not considered until several decades after his pioneering work in the peripheral skeleton (**Ilizarov, 1992**).

The first reports of craniofacial distraction osteogenesis were in the early 1960s, when rapid expansion of the palate was carried out in growing subjects. Finally, in 1973, Snyder first described the Ilizarov technique to lengthen a surgical osteotomy of the canine mandible. Interest in craniofacial distraction at first grew slowly, with sporadic experimental reports appearing over the ensuing 2 decades. However, in the early 1990s, experimental investigation intensified following reports from New York University on lengthening of dog mandibles and from Constantino and Friedman et al, who used distraction osteogenesis to successfully close canine segmental lower jaw defects (**Constantino et al., 1993**).

Several studies (within a variety of animal models) demonstrated the application of osteodistraction at a number of different sites including the mandible, lower maxilla, midface, and cranial vault. In 1992, the first clinical results of craniofacial distraction were reported by McCarthy et al in a small series of patients with congenital mandibular deformities (**McCarthy, 1992**). Since then, several larger series with longer follow-up periods have been recorded (**Molina and Monasterio, 1992**). More recently, the technique has been successfully used for midfacial and upper craniofacial skeletal defects. Fairley et al. and Mühlbauer reported the use of continuous distraction of the midface in 10 cases with Apert syndrome in 1995 (**Fairley et al., 1995**) (**Mühlbauer, 1995**). Midfacial and orbital distraction was reported by Chin and Toth et al. (**Chin and Toth, 1997**) (**Toth et al., 1998**).

Procedure	Timing (age)	Comments
Frontal-orbital advancement	6-12 months	Repeat procedure may be indicated for continued growth restriction
Le Fort III osteotomy with advancement	4-8 years	If performed in this age group a secondary Le Fort III will be required in teenage years
Le Fort III osteotomy with advancement	9-12 years	Preferred time period for this procedure since the majority of midface growth is complete
Secondary midface advancement, Le Fort I osteotomy and mandibular osteotomies	14-18 years	Required for dentofacial occlusive deformities
Monobloc frontofacial advancement	4-8 years	Achieves improvement in forehead, orbital, and midface aesthetics. Higher incidence of infection than Le Fort III Procedure. Majority of patients will require a secondary midface procedure in teenage years

Table 3 Protocol for the treatment of syndromic craniosynostosis according to Bartlett and Mackay (From Bartlett,S. and Mackay,G. Craniosynostosis Syndromes. In S.J. Aston, R.W. Beasley, and C.H.M. Thorne(eds.) Grabb and Smith's Plastic Surgery ( ) 5th edition, Rippincott-Raven, 1997)

2.1.7.4 Frontal-Orbital Advancement

The surgical goals of frontal-orbital advancement are threefold: (1) to release the synostosed suture and to decompress the cranial vault, (2) to reshape the cranial vault and advance the frontal bone, and (3) to advance the retruded supraorbital bar, providing improved globe protection and an improved aesthetic appearance. The procedure is performed through a coronal incision. With the assistance of a neurosurgical team, a frontal craniotomy is performed to release the synostotic suture and to elevate the frontal bone. Once the frontal bone is removed, the brain is gently retracted, exposing the underlying retruded supraorbital bar, which is advanced in a tongue-in-groove manner and secured with wires, miniplates, or sutures (**Figure 7A and Figure 7B**). Cranial vault remodelling is dependent on the preoperative head shape. For severe turricephaly, a total cranial vault reshaping is performed. This procedure allows for a significant reduction in the vertical height of the skull. For the child with mild turricephaly, only the anterior two-thirds of the vault are remodelled. The supraorbital bar and forehead are advanced into an overcorrected position to allow for increased growth of the cranial vault.

Following this initial frontal-orbital advancement and cranial vault remodelling procedure, the child is seen on a 6- to 12-month basis by the craniofacial team. Continued growth of the cranial vault and midface are monitored closely by means of three-dimensional CT scans and clinical observation. Although frontal-orbital advancement provides excellent decompression of the craniosynostosis and moderate improvement in the shape of the cranial vault in the early postoperative period, continued growth restriction in both the cranial vault and the midface region often produces poor long-term aesthetic results (**David and Sheen, 1990**) (**Posnick et al., 1993**) (**Whitaker et al., 1985**). If signs of increased intracranial pressure, severe exorbitism, or an abnormally shaped cranial vault develop or persist, further surgery for cranial vault remodelling are indicated.

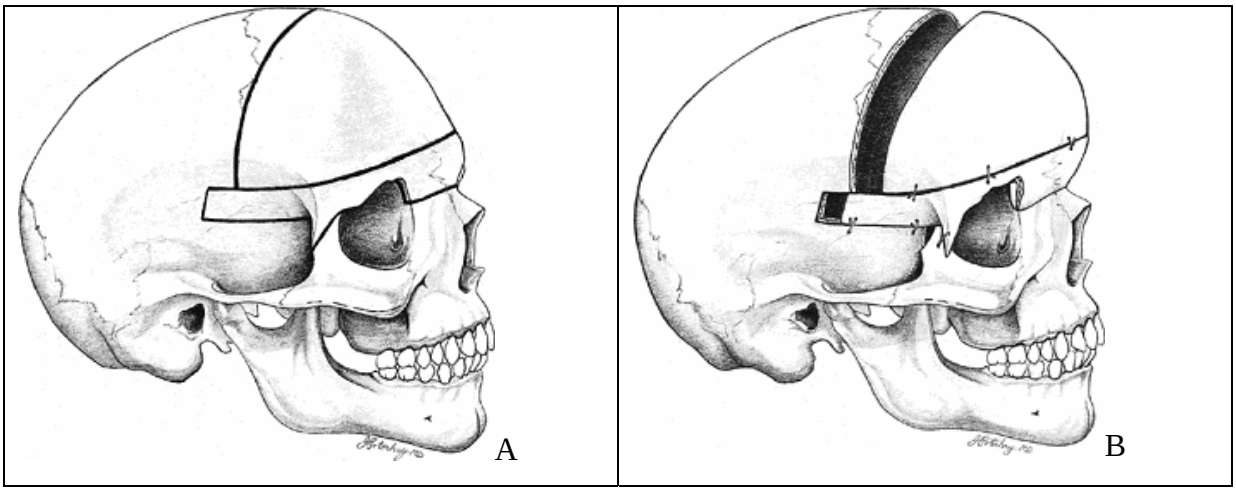

Figure 3: Frontal-orbital Advancement. A: Lines of osteotomy for forehead and supraorbital bar advancement. B: After advancement and refixation (From Bartlett,S. and Mackay,G. Craniosynostosis Syndromes. In S.J. Aston, R.W. Beasley, and C.H.M. Thorne(eds.) Grabb and Smith's Plastic Surgery, 5th edition, Rippincott-Raven, 1997).

2.1.7.5 Surgical Correction of the Midface Deformity

The first attempt to correct the midface deformity in a syndromic craniosynostosis patient was made by Sir Harold Gillies, who performed a Le Fort III procedure (**Gillies and Harrison, 1951**). The procedure, initially abandoned by Gillies, was later popularised again by Tessier (**Tessier, 1971**) (**Figure 4 and Figure 5**).

The Le Fort III osteotomy can be performed alone or, if all permanent teeth have erupted, in conjunction with a Le Fort I advancement. The monobloc procedure, which involves the

advancement of the Le Fort III fragment in coordination with the supraorbital bar and forehead ‘en bloc’, was developed by Fernando Ortiz-Monasterio (**Ortiz-Monasterio et al., 1978**) (**Figure 7 and Figure 8**). The monobloc procedure, while offering the advantage of simultaneously correcting the supraorbital and midface deformity, has been associated with a higher infection rate, which is most likely a result of the direct communication between the cranial and nasal cavities. Fearon et al. found an increased infection rate after performing the monobloc procedure in the neonatal period and did not recommend this procedure (**Fearon, J. A., and Whitaker, 1993**). Currently, the Le Fort III advancement via a subcranial approach is regarded as a good choice for correcting the midface deformity, although good results with the monobloc in patients over 8 years of age have been reported. The exact timing of midface correction remains a controversy among craniofacial surgeons. Some craniofacial centers advocate early surgical correction between the ages of 4 and 7 years; others prefer to wait until skeletal maturity is reached at around puberty, unless airway obstruction or severe exorbitism dictates immediate early surgery. The advocates of delayed surgical correction cite the evidence of high incidence of recurrent class III malocclusion in patients who undergo surgery earlier (4 to 9 years), often requiring a secondary Le Fort III procedure in the teenage years (**Bachmayer et al., 1986**) (**Kaban, 1986**). Advocates of early correction of the midface deformity believe the overall aesthetic improvement will have a significant positive psychological effect and improve self-esteem in these children, and they accept a secondary Le Fort III or monobloc osteotomy as a standard step in the treatment of these patients.

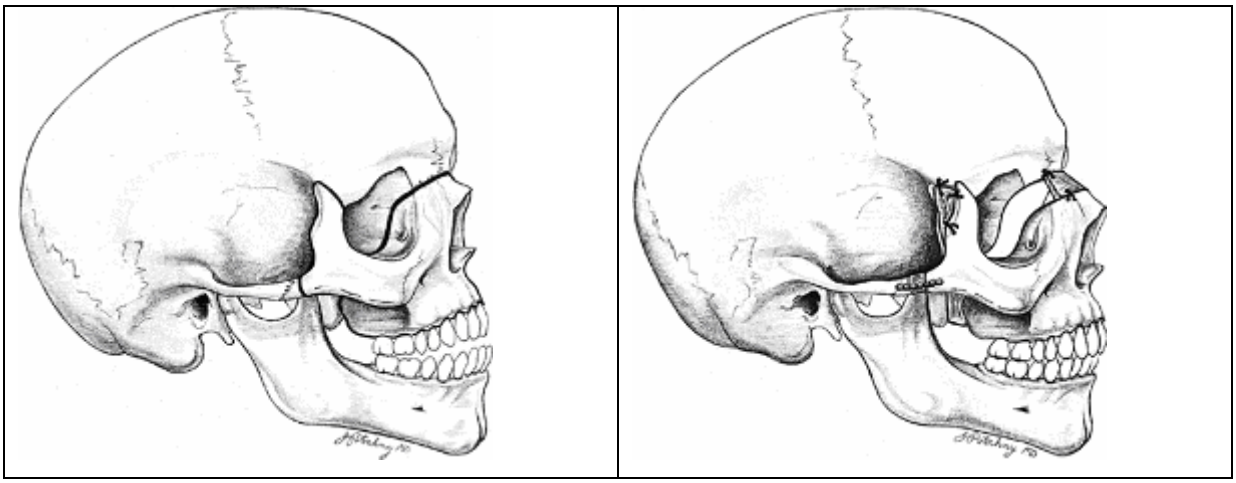

Figure 4: Le Fort III advancement. A: Lines of osteotomy. B: Midface advancement and stabilization with bone grafts and miniplates (From Bartlett,S. and Mackay,G. Craniosynostosis Syndromes. In S.J. Aston, R.W. Beasley, and C.H.M. Thorne(eds.) Grabb and Smith’s Plastic Surgery, 5th edition, Rippincott-Raven, 1997).

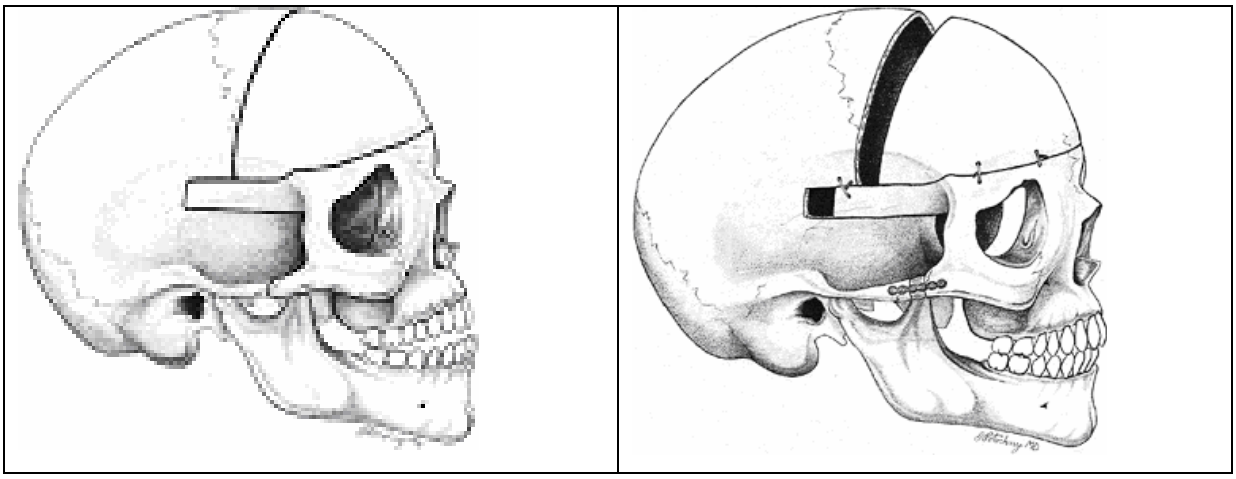

Figure 5: Monobloc advancement. A: Lines of osteotomy for monobloc osteotomy. B: Advancement of midface, orbits, and frontal bone and stabilization with bone grafts and miniplates (From Bartlett,S. and Mackay,G. Craniosynostosis Syndromes. In S.J. Aston, R.W. Beasley, and C.H.M. Thorne(eds.) Grabb and Smith's Plastic Surgery, 5th edition, Rippincott-Raven, 1997).

2.1.7.6 Orthognathic Surgery

The abnormal patterns of facial growth in children with craniosynostosis syndromes often result in significant dentofacial deformities. The class III malocclusion, secondary to midface retrusion, is the most commonly seen deformity and often develops despite appropriate midface surgical treatment. The team approach to the management of these jaw abnormalities usually involves an orthodontist and dentist, as well as a craniofacial surgeon. After surgical correction is planned, and after completion of growth of both the maxilla and the mandible and any needed presurgical orthodontic preparation, surgical procedures include a Le Fort I osteotomy and is some cases a bilateral sagittal split osteotomy with a sliding genioplasty. These surgical procedures are usually performed between the ages of 14 and 18 years, when the facial skeleton is mature and growth has completed.

2.2 Kleeblattschädel:

2.2.1 Definition:

In the medical terminology there are several terms describing this specific morphologic entity, commonly known as “Kleeblattschädel” or “clover leaf skull”. Other expressions used to describe this condition are triphyllocephaly, trefoil appearance of the skull or trilobar skull shape (**Lodge et al., 1991**).

The term “Kleeblatt” (**Schott, 1881**), which is the German expression for a clover leaf, was used for the first time by Schott for this craniofacial abnormality. He compared the appearance of the posterior skull in a case of dwarfism with a cloverleaf and mentioned that it looked clover leaf like.

Kleeblattschädel (cloverleaf skull) is one of the most severe forms of craniosynostosis and is thought to be caused by premature fusion of the coronal, lambdoid, and metopic sutures with the anterior sagittal and squamosal sutures open. A constriction ring develops from the sphenoid to the petrous ridges with bulging of the frontal and temporal bones. In the most severe form all the sutures of the skull may be fused which is then a form of pansynostosis or pancraniosynostosis. This condition is often described as craniostenosis, due to the confining nature of the synostosed skull bone, not rendering space to the growing brain. Other observations have included a shortened antero-posterior dimension of the cranial base, particularly affecting the anterior cranial fossa. This is also commonly seen in syndromic cases with brachycephaly, which are also known as acrocephaly syndromes and include Crouzon’s and Apert’s syndromes (**Witt et al., 1992**) (**Stewart et al., 1977**). They have markedly receding supraorbital borders and severe exorbitism. The eyelids may be retracted behind the globe with corneal opacity and corneal perforations if surgery is delayed (**Watters et al., 1973**) (**Figure 6**).

Figure 6: Left: Severe case with Kleeblattschädel deformity, having both respiratory and ophthalmic complications. Right: Patient that was referred to us at the age of 12 months. He suffered bilateral blindness at the age of 2 months, after severe proptosis of both eyes

The skull circumference is significantly reduced. Hydrocephalus is usually present. Choanal atresia, high arched palate, or cleft palate may be present. There may be varying severity of maxillary hypoplasia and low-set ears. Kleeblattschädel may occur in Pfeiffer's syndrome, thanatophoric dysplasia, and campomelic dysplasia of the short bone type (**Persing et al., 1989**) (**Kroczek et al., 1986**), but is also found in isolated cases as well as Apert's syndrome. In our series we found 4 cases of the Crouzon type with pancraniofacial synostosis and Kleeblattschädel (**Heeckt et al., 1993**). In an eighteenth gestational week fetus with the Kleeblattschädel deformity, Witt et al. (**Witt et al., 1992**) demonstrated that the cranial base was not fused and that the premature craniosynostosis was primarily in the coronal sutures.

2.2.2 Aetiology

The aetiology of Kleeblattschädel deformity is multifactorial and the exact underlying cause is not known yet. Moss and then later Burkhard and Fisher suggested that premature sutural closure is secondary to abnormal growth of the skull base (**Moss, 1950**) (**Burkhardt and Fisher, 1970**). Liebaldt regarded the premature sutural synostosis as the primary site of the

defect in Kleeblattschädel deformity (**Liebaldt, 1965**). One of our cases was autopsied after dying three weeks postoperatively of disseminated bacterial meningitis and the skull base was examined in detail (**Figures 7 and 8**). Histomorphology of the anterior and posterior cranial fossae appeared normal. Only in the sphenooccipital synchondrosis we found predominantly roundish and slightly hypertrophic chondrocytes in columns of reduced height. We assume that these only moderate morphological changes are a variation of the normal and cannot explain the abnormal craniofacial growth pattern. Reports on the histomorphology of the cranial base are very divergent, suggesting that the cranial base might probably not be the site of the primary defect as is still widely believed (**Heeckt et al., 1993**) (**Kroczek et al., 1986**).

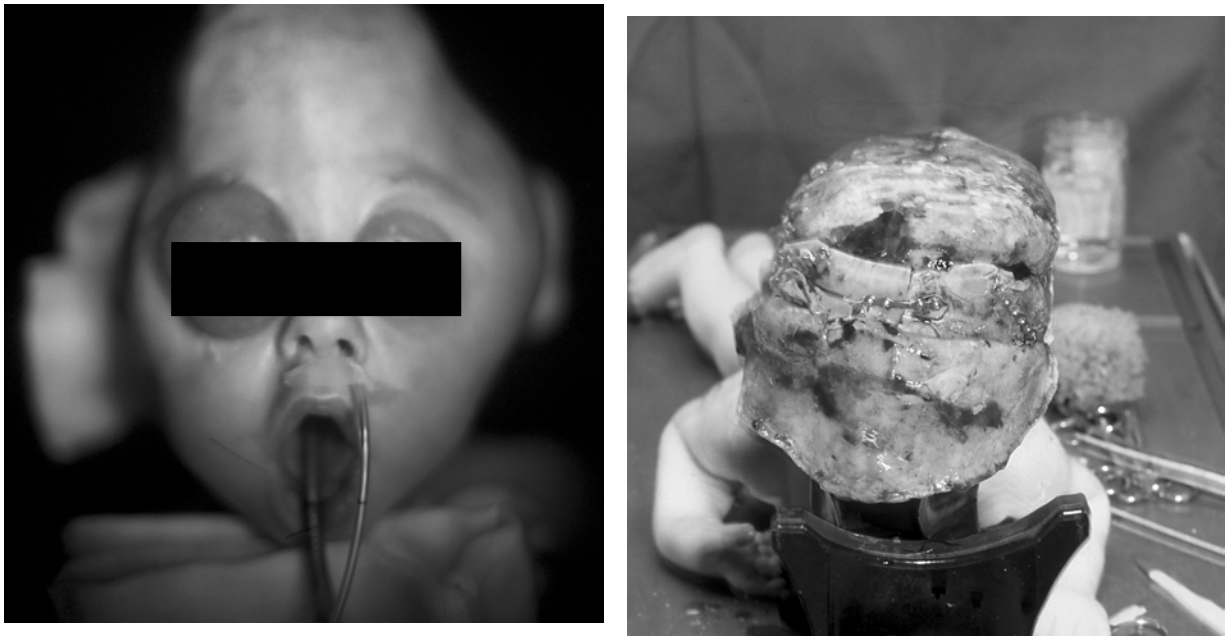

Figure 7: A patient with Pfeiffer's syndrome and severe Kleeblattschädel deformity. He died 1 week after emergency craniofacial decompression from disseminated bacterial meningitis.



Figure 8: A post mortem examination was done. The skull bone showed typical impressions and indentations from raised intracranial pressure. No abnormalities were found in the skull base.

The anomaly has been associated with a wide variety of inheritable disorders, including monogenetic syndromes, such as Apert's, Carpenter's, and Crouzon's syndromes, and chromosomal abnormalities, notably partial trisomy 13q and 15q. Other inheritable syndromes associated with Kleeblattschädel deformity but without clear cut aetiology include Pfeiffer's syndrome, thanatophoric dysplasia, and campomelic dysplasia (**Cohen, 1987**). But generally the Kleeblattschädel deformity has been seen in patients with both syndromic and nonsyndromic forms of craniosynostosis (**Gosain et al., 1997**). Lodge et al. reported 10 cases of Kleeblattschädel deformity and in 4 patients the clinical diagnosis of the condition was consistent with Pfeiffer's syndrome and in 6 patients with Crouzon's syndrome (**Lodge et al., 1993**). The malformation has also been attributed to sporadic in utero events such as amniotic banding.

For each of the above disorders, the restriction of cranial growth likely begins early in gestation, given the widespread abnormalities seen in the skull base and calvarium at birth. Prenatal ultrasound examination is able to detect Kleeblattschädel as early as at 27.5 weeks of gestation and even earlier with modern high quality ultrasonic equipment (**Salvo, 1981**).
Rohatgi studied 6 cases of cloverleaf skull deformity which all had a mild to severe degree of craniofacial dysostosis of the Crouzon type with variable degrees of exorbitism, raised intracranial pressure and mental retardation. All except one patient had maternal fever and/or drug intake during the first trimester or toxaemia of pregnancy. He postulated then that cloverleaf skull is a severe malformation of Crouzon's disease due to teratogenic change in the first trimester of pregnancy causing a developmental aberration of primary mesenchyme of the neurocranial capsule and base of the skull (**Rohatgi, 1991**).
Cohen summarises current knowledge in his discussion on Lodge et al.'s publication and postulates that current classification recognises etiologic and pathogenetic heterogeneity. Each condition associated with cloverleaf skull anomaly is an etiologic separate entity (see classification below) (**Cohen, 1993**).

2.2.2.1 Conditions with Cloverleaf Skull Anomaly:

Known etiology:

- Monogenic
    - Apert syndrome
    - Carpenter syndrome
    - Crouzon syndrome
    - Osteoglophonic dysplasia
- Chromosomal
    - dup (13q)
    - dup (15q)
- Disruptive
    - Amniotic bands
- Iatrogenic
    - Bilateral subtemporal decompression procedures for hydrocephaly

Uncertain or unknown etiology:

- Thanatophoric dysplasia type 2
- Camptomelic dysplasia, craniosynostotic type
- Cloverleaf skull with elbow ankylosis only
- Pfeiffer syndrome
- Beare-Stevenson cutis gyrate syndrome
- Say-Poznanski syndrome
- COH syndrome
- Isolated cloverleaf anomaly

(Source: Adapted from M.M.Cohen, Jr. Cloverleaf skull update. Proc greenwood Genet Ctr 6:186, 1987 and Craniosynostosis update 1986-1987 Am J Med Genet Suppl 4:99, 1988)

2.2.3 History

Holtermüller and Wiedemann observed a case in 1958 where they used the expression "Kleeblattschädel", which is the german expression for clover leaf skull. They called it Kleeblattschädel and the Kleeblattschädel-Syndrome **(Holtermüller and Wiedemann, 1960)**, which was actually recorded by Leiber and Olbrich in their second edition of 'Wörterbuch der

klinischen Syndrome' as the Holtermüller-Wiedemann Syndrome (**Leiber and Olbrich, 1959**). Certain criteria were postulated for this condition to be classified as "Kleeblattschädel-Syndrom":

1. "Kleeblattschädel" (main symptom) which describes the typical morphology of trilobed (clover leaf) skull shape, with an elevated cranial vault centrally and bilateral expansions of the temporal areas in a convex-lateral pattern. The ears are usually low set.
2. Craniofacial deformities in the regions of the orbits, the nose and both the upper and lower jaws.
3. Mikromelia of all limbs and deformities of the spine, although both criteria are not obligatory.
4. Characteristic appearance on skull X-ray, Pneumocephalus and Hydrocephalus.
5. Proggressive deterioration, also of skull growth and bad prognosis due to raising intracranial pressure.

Holtermüller and Wiedemann found other similar cases in the literature, which were described many years earlier already (**Vrolik, 1849**) (**Rudolphi, 1824**). Liebaldt, an anatomical pathologist, in 1964 examined the same case that was radiologically and clinically described by Holtermüller and Wiedemann (**Liebaldt, 1965**). He examined an additional case with Kleeblattschädel deformity. It was a corpse of a dead-born foetus that had been preserved in Formalin for more than 18 years. The specimen was made available to him by Töndury from Zürich and had multiple ankyloses of the extremities. Liebaldt described the typical trilobed deformity of the cranial vault, which he thought to be of mesoectodermal-angiodysgenetic origin. He noted the decreased brain development and consecutive internal hydrocephalus. Liebaldt divided the deformity into two different groups (**Table 4**).

	Clinical features
Group I	Isolated cranial vault deformities
Group II	Cranial vault deformities combined with "distant" skeletal deformities

Table 4: Classification according to Liebaldt (Liebaldt, 1965)

A group of German pathologists described another case of Kleeblattschädel which was a premature foetus, delivered at 31 weeks of gestation. The foetus died a few minutes after

delivery through caesarean section. (**Gathmann and Meyer, 1977**). They compared this patient with a series of other cases that have been reported in the literature. It is a retrospective study based on clinical, radiological and pathological reports as well as examination of available specimen. Gathmann et al. did an in-depth study of these cases and found certain specific variations from the normal skull anatomy which commonly occurred. They confirmed the existence of a firm, constriction ring like structure which Meyer (**Meyer, 1924**) called 'Crista orbito-parieto-occipitalis' which starts at the superolateral part of the orbital roof and the lateral part of the lesser wing of the sphenoid bone and runs from there to the occiput. Liebaldt named this structure the 'inner ring crest'. It is responsible for the division of the skull into three distinct lobes and the trilobar shape (**Liebaldt, 1964**). Frequently there is deformed bone on the superolateral parts and posterior parts of the cranial vault together with multiple bony gaps. The cranial sutures at the level of the cranial base are narrowed and the middle and posterior parts of the cranial base are shortened. The middle cranial fossa is broadened. Some cases had a small area of ossification with thin bone in the centre of the forehead which was called the rudimentary "Os bifrontale". Many variations of skull skeletal anatomy were detected and described but the predominant anatomic feature and also the main criteria remains the cloverleaf-like appearance of the skull with the typical trilobar shape. The temporal areas are mostly deformed in a convex pattern, while the third prominence or lobe is either positioned superior on the cranial vault or more posteriorly. In some cases the third prominence was occipitally (**Gathmann and Meyer, 1977**).

The earliest reported case of Kleeblattschädel was described in 1800 by Loschge (**Loschge, 1800**). The described case was a young girl, born in 1788 and she died at the age of 38 days. This case was first mentioned by Loschge in 1795 (**Loschge, 1795**). In 1965, Comings was the first to describe a case occurring in the United States (**Comings, 1965**).

2.2.4 Classifications:

Partington et al. (**Partington et al., 1971**) studied 4 cases with the Kleeblattschädel deformity and reviewed 21 other cases described in the literature. They subdivided Kleeblattschädel-syndrome into three distinct and different syndromes that are associated with the morphologic trilobar deformity:

Type:	Clinical features:
Type I	with chondrodysplasia
Type II	with localised skeletal lesions
Type III	with a normal skeleton outside the skull

Table 5: Classification of clover leaf skull deformity according to Partington (Partington et al., 1971)

The first type (Type I), is associated with thanatophoric dwarfism. In the second type (Type II), there are bony lesions outside the skull, but these are localised, not generalised. Death may occur at or before birth but usually the child survives the newborn period and may live for several years. In the third type (Type III), the prognosis is similar to Type II but the skeleton outside the skull is normal. The occurrence of affected families and siblings is reported in the Type I syndrome and raises the possibility of an autosomal recessive type of inheritance. It may suggest that thanatophoric dwarfism may be similarly inherited. The preponderance of all three types reported from Germany or from families of German descent supports a genetic rather than a teratogenic aetiology (**Partington et al., 1971**).

The radiological appearances of the skulls of all four cases of Partington et al. corresponded with those reported by other authors and showed the typical cloverleaf skull. Outside the skull, all four cases had micromelic dwarfism with short bowed tubular bones and flared metaphyses. Furthermore there was flattening of the vertebral bodies, and severe narrowing of the chest; death occurred at or soon after birth.

Maroteaux et al. (**Maroteaux et al., 1967**) argued that cases of fetal chondrodystrophy with severe bony changes are distinct from classical achondroplasia, and suggested the name thanatophoric dwarfism. 'Thanatophor' means: 'to bring death' and thanatophoric dwarfism is a disease which is caused by a generalised insufficiency of enchondral ossification, which is lethal at a very early age. Death usually occurs in the perinatal period. Except for the cloverleaf skull, the cases of Partington et al. met all the criteria of thanatophoric dwarfism and it was postulated that a cloverleaf skull may well be a previously unrecognised feature of thanatophoric dwarfism.

Gathmann et al. confirmed Partington's classification of cloverleaf skull syndrome, except for some minor variations. The typical cases all had a very distinct 'Crista orbito-parieto-

occipitalis' or 'ring crest'. Most cases had similar changes at the base of the skull and in the shape of the cranial vault.

Type:	*Described by:*	*Clinical features:*
Type I	Vrolik	Chondrodysplasia, dwarfism and early death
Type II	Loschge	Symmetrical ankylosis of the bigger joints, live expectancy a few months
Type III	Holtermüller-Wiedemann	Life expectancy is but a few months, no ankylosis or dwarfism

Table 6: Classification of Kleeblattschädel according to Gathmann et al. (Gathmann et al., 1971)

Type I and Type II cases showed a consistently shorter middle and posterior cranial fossa and the synchondroses in the skull base are narrowed. All cases with generalised dwarfism, like the case described by Vrolik from Amsterdam, are classified as Type I. They are dead-born in most cases and rarely survive the perinatal period.

Type II cases, like described by Loschge from Erlangen (1800), with symmetrical ankyloses of the big joints of the extremities show bony deformities mainly at the elbow. Cartilaginous ankyloses are most common at the knee joints and fibrous ankyloses at the toes. Survival can vary from weeks to months.

Holtermüller and Wiedemann (1960) described the cases without any ankyloses or dwarfisms that are classified as Type III cases and represent a subclass of cloverleaf skull deformity. According to Gathmann et al. the Type III cases are extremely rare and they reach a much higher age than Type I or II cases.

Gathmann also postulated that a cartilage factor and a vessel factor could be responsible for the changes. The growing brain elicits abnormal tension which has a negative influence on the skull base and leads to the abnormal growth of the cranial vault.

2.2.5 Pathophysiology

The normal embryologic development is an important factor in the understanding of the deformities. The anterior part of the skull base is of ectodermal origin and the posterior part

of mesodermal origin. Stark divides the body of vertebrates into three major parts (**Stark, 1965**):

1. Anterior region of the head and *procencephalon*
2. Posterior region of the head and *rhombencephalon*
3. *Trunk-tail* region

Table 7: Anatomical division according to Stark (Stark, 1965)

Stark divided head deformities into two main groups, first the *cyclope* and second the *otocephalic* group. The cyclope group shows deformities and defects in the rostral or anterior part. The anterior area of the head, nose, eyes, the procencephalon and the anterior base of skull are affected. In the otocephalic group the central nervous system is not commonly involved, but rather the zygomatic arch, ears and posterior area of the skull.

Bone development of the skull base commences in the cartilaginous pars supraoccipitalis when the length of the embryo is 30 mm, from there it advances anteriorly to the pars exoccipitalis, the pars basioccipitalis, the basisphenoid, and eventually at 90 mm length the presphenoid part. Cartilaginous development and bony ossification seem to be completely independent processes, as the first cartilaginous nuclei develop in the basisphenoid, and the first ossification takes place in the pars supraoccipitalis (**Theiler, 1963**).

The synchondrosis intersphenoidalis ossifies at the time of delivery, the synchondrosis spheno-occipitalis at 18 years, the synchondrosis intraoccipitalis anterior at 4 years, and the synchondrosis intraoccipitalis posterior at 2-3 years. Longitudinal growth in the skull base takes place through interstitial growth in the cartilaginous zones and through bony onlay in the sutures (**Figure 9**).

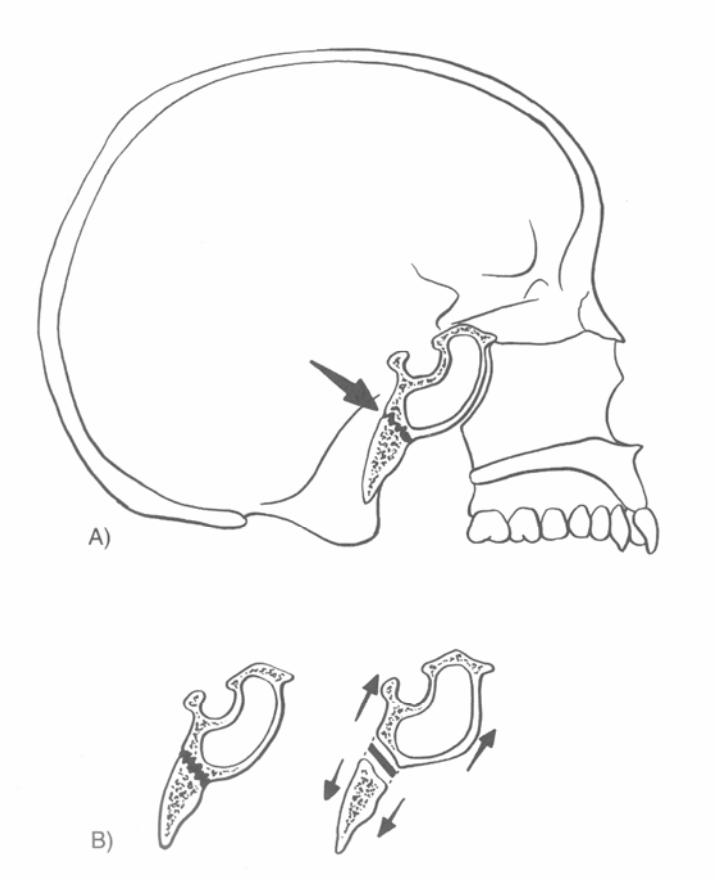

Figure 9: The sphenooccipital suture and directions of growth

Mesenchymal dura invests the growing brain with more firm areas, so called dural bands (**Blechschmidt, 1974**). It is postulated that the shape of the cranium is influenced by the growing brain and the chondrocranium, and that primary anomalies in the skull base lead to abnormal growth and tension in the developing cranium, similar to the functional matrix theory of Moss (**Moss, 1959 and 1969**).

However, Kleeblattschädel deformity results in most cases from the premature fusion of multiple cranial sutures, particularly the coronal and lambdoid sutures bilaterally, and (usually) the posterior aspect of the sagittal suture. Since the squamosal sutures, the anterior sagittal suture and metopic suture remain open, the developing brain herniates subtemporally and through an enlarged anterior fontanelle, producing the characteristic trilobed appearance (**Laurent and Cheek, 1989**).

Because of the severe restriction of cranial growth, these children typically have profound elevations of their intracranial pressure at birth, as evidenced by the presence of gyriform

indentations of the inner table of the skull, which leads to the typical 'copper beaten' appearance on conventional skull X-rays. Hydrocephalus, presumably resulting from a combination of functional aqueductal stenosis and increased resistance to venous outflow, is frequently present and contributes to elevated intracranial pressure. Before the advent of surgical treatment for this disorder, affected children died in infancy. Those who survived were severely impaired neurologically, usually institutionalised, and grotesquely misshapen (**Holtermüller and Wiedemann, 1960**) (**Partington et al., 1971**).

Burkhardt reviewed the cloverleaf skull syndrome and concluded that it is due to morphogenetic forces superimposed on a basic chondrodysplastic process (**Burkhardt, 1970**). He believes that the main factor is improper endochondral ossification, which leads to foreshortening of the base of the skull. Subsequently the frontoparietal growth of the fetal brain is hampered and it enlarges superiorly. The lateral expansions of the brain and skull are explained by gross increases in the volume of the temporal lobes due to obstruction of the cerebrospinal fluid (CSF) circulation in the lateral ventricles. Early intracranial hypertension may also lead to increased vascularisation of the diploe accounting for the haemangiomatous appearance of various skull bones found intraoperatively in certain cases. Although these theories sound quite plausible, they fail to account for the cases with cloverleaf skull deformity without generalised chondrodysplastic changes.
Descriptions of cloverleaf cases show a wide range of abnormal skull anatomy and premature ossification of cranial sutures. Dietrich-Weinholdt described complete synostosis of the anterior half of the sagittal suture with a so called 'Os biparietale'. In this case the two parietal bones were synostosed and formed one single biparietal bone (**Dietrich-Weinholdt, 1926**). Liebaldt called the bony deformation of the posterior skull 'Fontanellenknochen' and found cavities which he thought to be rudiments of an embryologic vessel network (**Liebaldt, 1966**). Bonucci and Nardi found a complete synostosis of the sagittal suture and both lambdoid sutures. The posterior fontanel was completely ossified with a bony extuberance in this area (**Bonucci and Nardi, 1972**).

In addition to the dramatic cranial dysmorphism, patients often harbour a number of other congenital anomalities. Each may influence the child's ultimate outcome independently of the skull malformation. Midfacial abnormalities are particularly common; in fact, respiratory complications secondary to obstruction of the upper respiratory tract and in a few cases choanal atresia are a frequent source of morbidity and mortality in these children. Associated

anomalies of the axial skeleton, including craniocervical instability have also been reported. Kleeblattschädel has been associated with a Arnold-Chiari malformation in two described cases. Abnormalities of the appendicular skeleton, usually as a component of one of the acrocephalo-syndactyly syndromes and abnormalities of the gastrointestinal system, notably pyloric stenosis, are also common (**Lodge et al., 1993**) (**Partington et al., 1971**) (**Resnick et al., 1995**) (**Venes, 1988**) (**Francis et al., 1992**).

3 Patients and Methods:

This is a retrospective study of nineteen patients with pancraniofacial synostosis and Kleeblattschädel deformity who were evaluated and treated by the 'Arbeitsgemeinschaft Kraniofaziale Chirurgie' in Munich, Germany, between 1978 and 2003. A great part of the patients was cooperatively managed by the Craniofacial Group Munich-Innsbruck, which is a cooperation between the two craniofacial centers, headed by Prof. Dr. Wolfgang Mühlbauer (Munich) and Prof. Dr. Anderl from Innsbruck. It represents a 25-year experience of dealing with this complex condition. The 'Arbeitsgemeinschaft Kraniofaziale Chirurgie' is cooperation between the department of Plastic Surgery headed by Prof. Dr. Wolfgang Mühlbauer (MD) at the Krankenhaus München Bogenhausen and the department of Paediatric Surgery headed by Prof. Dr. Frank Höpner (MD) at the Krankenhaus München Schwabing. The surgical team in all described cases was headed and coordinated by plastic surgeons of the above mentioned craniofacial centers. The surgical teams included paediatric surgeons who were involved in shunting procedures for raised intracranial pressure when hydrocephalus was present. Neurosurgeons were actively involved in extensive intracranial procedures.

The clinical, the radiological and photographic records of these 19 patients with cloverleaf deformity were documented and reviewed. Follow-up visits were scheduled where possible to provide information about the condition, results and patient satisfaction. All referred patients underwent a comprehensive craniofacial multidisciplinary clinical and radiological assessment at their initial presentation. Included in the clinical workup were neurosurgical, ophthalmologic and otolaryngologic evaluations. Furthermore, a detailed history of the anomaly was taken in all patients, including antenatal history, birth weight, gestation and

family history. The clinical examination included detailed examination of the head, face and extremities.

Radiological investigations included plain skull radiographs, complete high-resolution computed tomographic (CT) axial scans of the calvarium and face at both soft tissue and bony settings. Since 1992, three-dimensional CT reconstructions of the complete craniofacial skeleton were added to the routine investigations. In younger patients, if bony gaps still permitted it, pre and postoperative serial high resolution ultrasound examinations of the brain were done. Ultrasonic investigations of the skull examine the status of the ventricular system, progression in ventricle size and signs of increasing intracranial pressure. Intraoperative findings were documented and reviewed. At our institution no direct intracranial pressure measurements were performed, nor was intracranial pressure monitoring pre or postoperatively done. Post-mortem anatomical and histological examination was performed in one case that died after decompressive intracranial surgery (**Kroscek et al., 1986**). Outcome was evaluated by surgeon and patient satisfaction. The classification of Whitaker et al. was used to assess surgical outcome and results (**Whitaker et al., 1987**). All patients up to date were evaluated according to Whitaker's classification, although the treatment has not been completed in all the cases up to date.

Category I:	No refinements or surgical revisions considered advisable or necessary.
Category II:	Soft-tissue or lesser bone-contouring revisions were advisable; could be done on an outpatient basis or minimum2-day hospitalisation.
Category III:	Major alternative osteotomies or bone-graft repositioning, onlay bone grafts, Le Fort advancements; these procedures were not as extensive as the original operations.
Category IV:	A major craniofacial procedure was advisable, duplicating or exceeding the original procedure.

Table 8: Classification of Whitaker et al (Whitaker et al., 1987)

The surgical management of our own cases was studied and documented and compared with other reported series that are known to us. A thorough review on the international medical literature reporting on cloverleaf skull and its management has been done.

The patients in our series were treated in a period reaching from 1978 to 2003. A total number of 19 patients with severe Kleeblattschädel deformity were included in this study.

In our experience many patients with Apert syndrome show a mild degree of trilobed skull shape. However, patients with a minor degree of cloverleaf skull, having mild bitemporal bulging and convexity were excluded from this group. The final diagnosis was confirmed by clinical and radiological features and findings as well as genetic studies.

4 Our Surgical Management:

4.1 Timing and Choice of Procedure:

Elective craniofacial surgery for cranial vault remodelling is scheduled at 6 months of age, preferably before 12 months. Frontal-orbital mobilisation (FOM) or in certain instances posterior occipital mobilisation (POM) is the procedure of choice depending on the specific indication. Subtotal craniectomy and total cranial vault remodelling is reserved for severe cases of craniostenosis.

In cases with severe midfacial retrusion internal distraction devices for distraction of the midface are applied during the first elective intracranial procedure. After a refractive period of 7 days the distraction is commenced with a distance of 1mm per day. After completion of distraction, the devices are left in situ for three months for consolidation of the new bone created.

At our institution midface distraction is presently done at a very young age without or only with partial osteotomies and is the procedure of choice. However, the cases of this series which needed midface advancement still had complete midfacial osteotomies of the Le Fort III type. This is due to the fact that midface distractions are only routinely performed at our institution since 1994. If no urgency arises this procedure is postponed to a later stage. The cases that urgently needed midfacial advancement all had Le Fort III osteotomies with immediate advancement and bone grafting in certain cases.

Any implanted non-resorbable osteosynthesis material is routinely removed in a secondary procedure six to eight weeks after the primary procedure, to facilitate normal growth. Only distractor devices are left for at least three months until bone consolidation is obtained.

Resorbable plating systems used for rigid fixation are left in situ, but in certain cases the devices are divided through a stab incision. Dental wire is not used for fixation as it tends to migrate intracranially. Vicryl 2-0 sutures in a figure eight suturing technique are the fixation method of choice.

Emergency craniofacial procedures are necessary due to increased intracranial pressure and underlying severe craniostenosis. Other emergency operations that are performed more or less frequently in Kleeblattschädel deformity are ventriculoperitoneal shunting for hydrocephalus, tracheostomy in cases with nasopharyngeal incompetence and tarsoraphy for severe cases of proptosis and exophtalmus.

4.2 Surgical Technique:

All patients need to be in a good general medical condition that allows for a prolonged anaesthesia and extensive intracranial procedure. Preoperative evaluation is done by an experienced team of paediatric anaesthetists and pediatricians. Postoperatively the patients are transferred to a specialised paediatric intensive care unit. All infants receive prophylactic intravenous antibiotics and red blood cell concentrates for transfusion must be in the operating room and ready before surgery is started. An average of between one and two units of red blood cells is routinely needed.

The patients are placed in the supine position with the head on a special headrest. If access to the posterior skull and occipital area is needed, the patient is placed in a prone position. A zick-zack bicoronal incision is the standard method used for FOM, POM or total cranial vault remodelling. If extensive surgery is planned a temporary tarsorraphy is done and 5-0 Nylon is used for this purpose. This suture is normally removed after the procedure is finished, in certain cases it is left in situ until the third postoperative day due to oedema and swelling. As a measure of safety the endotracheal tube is sutured to the nasal septum or fixed to the alveolus with a strong suture. The head should be free to be rotated in any direction after the area is prepped and draped.

To reduce blood loss we use 0,9% NaCl solution (Saline) with 1:100.000 adrenaline to infiltrate the scalp at the planned incision sites as well as the nasofrontal and lateral orbital area. Haemostatic sutures (Prolene 4-0) are applied distal and proximal to the incision. The

incision is done with a 15 scalpel blade up to the subgaleal loose connective tissue layer which is also called the scalping layer. Following this plane the dissection is carried out bluntly with a periosteal elevator anteriorly up to a level about 1cm above the orbits. Posteriorly dissection is carried out according to the planned procedure. Haemostasis is accomplished with bipolar coagulation. At the above mentioned level just above the orbits the plane is extended subperiostally and two large laterally based periosteal flaps are elevated over the forehead. The periosteum is stripped carefully following into the orbits. Care is taken to preserve both supraorbital nerves, in some cases they need to be released from their bony foramen with an osteotome. The dissection is carefully carried forward until the nasofrontal junction is exposed medially and the frontozygomatic suture laterally. The superior, medial and lateral wall of both orbits is freed subperiostally and also the anterior part of the temporal fossa next to the lateral orbital wall. With a frontal orbital advancement (FOM) or a total or subtotal craniectomy with cranial vault remodelling the dissection stops here and the craniotomy sites are planned. If a simultaneous midfacial advancement is planned or the application of midfacial distraction devices, the dissection needs to be carried on both subperiostally and over the temporal muscles to free the inferior orbital wall, the anterior part of the zygomatic arch as well as the anterior part of the infratemporal fossa. During this surgery it is of ultimate importance to protect the content of the orbital septum, which includes the globe, the optic nerve and several other important neurovascular and muscular structures. Another important structure which needs to be preserved uninjured, is the frontal branch of the facial nerve. It traverses from the level of the tragus of the ear to the lateral eyebrow, where it supplies the muscles of facial expression of the upper part of the face. The safe plane of dissection towards the zygomatic arch is to stay just underneath the deep temporal fascia which is separated from the muscle in this area by a layer of fatty tissue. This fascia layer merges at the zygomatic arch with the periosteum, where the dissection is further carried out subperiostally. In the area of the infratemporal fossa heed must be taken to avoid injury of the internal maxillary vessels. When the operative field is sufficiently dissected and bleeding is controlled either by coagulation or by applying bonewax to bleeding bone, the planned remodelling procedure can be commenced.

After completion of the procedure the operating field is rinsed with Saline and Nebacitin solution. The periosteum is closed with 4-0 Vicryl interrupted sutures and the skin with 3-0 Vicryl subcuticular sutures and staples to the skin. A Jackson-Pratt drain is routinely inserted and left without negative pressure on the level of the head.

4.2.1 Frontal-orbital advancement (FOM)

Craniotomies are planned and executed in order to preserve the bone pieces needed for forehead remodelling. First the placement of drill holes is planned and executed and the dura is carefully and bluntly dissected from the cranial surface of the bone around the drill hole and under the planned osteotomy lines. Then a craniotome is used to perform the necessary osteotomies in the cranial bone. When the bone piece is circumferentially osteotomised, it is carefully lifted up and the sites of dural attachment are freed under direct vision. The bone piece is secured with a bone holding forceps during this manoeuvre. The bone pieces are temporarily removed and kept in swabs soaked in Saline solution.

The dura mater is carefully released from the posterior or cranial surface of the supraorbital bar, which is removed after osteotomies are done with small cutting osteotomes. The intraorbital content is carefully protected with a brain spatula of medium width. Care must be taken to not exert any traction or pressure on the orbital septum and its contents. The tip of the osteotome must be visible in the orbit during the osteotomy at all times. The supraorbital bar is the removed and reshaped to improve the aesthetic appearance of this area. The curving can be adjusted or correction of slight hypo- or hypertelorism can be achieved. The forehead is remodelled using the previously removed bone pieces. After the shape is improved, osteosynthesis is done with resorbable 3-0 Vicryl sutures in a figure eight type suture to rigidly fixate the new forehead in its desired three dimensional shape. The new forehead is then put back onto the supraorbital bar and advanced ‘en bloc’ anteriorly to enlarge the volume of the anterior cranial fossae and to deepen the superior aspect of the orbits. With an advancement of 10mm to 25mm it is in most cases necessary to use stainless steel or titanium miniplates for rigid fixation, to prevent the forehead from falling back postoperatively. The miniplates are fixed with screws on the lateral surface of the supraorbital bars as well as to the parietal bone or bone overlying the temporal fossa. All plates and screws are routinely removed after six to eight weeks (**Figures 10 and 11**).

Figure 10: Patient with pansynostosis and cloverleaf deformity at initial presentation

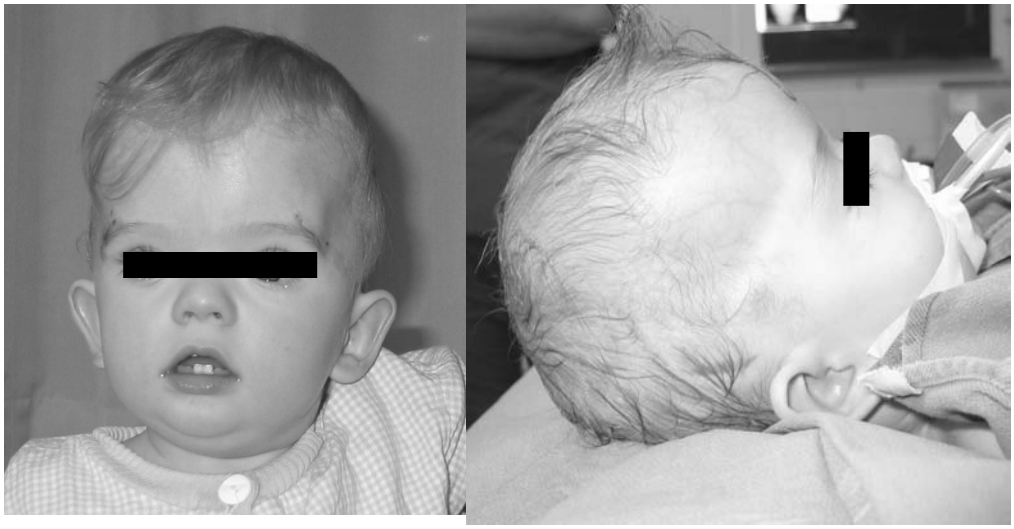

Figure 11: The same patient at 9 months of age just after miniplate removal following frontal-orbital mobilisation (FOM) and cranial vault remodelling

4.2.2 Total cranial vault remodelling (Subtotal Craniectomy):

The same surgical steps are followed as in a case with frontal-orbital advancement, where the anterior cranial vault bone is routinely removed up to the coronal sutures. In total cranial vault remodelling or the so called subtotal craniectomy, the whole cranial vault is removed according to the underlying pathology, which determines the craniotomy sites and the shape and size of bone pieces. The posterior border is up to the level of the lambda or posterior cranial fontanel. The frontal-orbital advancement and fixation of the neo-forehead is done first as described above. Now the rest of the cranial vault is put back according to the specific

design needed to reach a normal skull shape. In the past we often used titanium or stainless steel surgical miniplates, which are recently replaced by resorbable plating systems and ideally by fixation with Vicryl sutures only. Radial releasing cuts on the lateral sides or posteriorly can be done if needed to widen the shape of the skull. The osteotomised segments are bended in the required direction with a special bone bending forceps.

4.2.3 Midface osteotomies and advancement:

With severe midface hypoplasia there are several surgical options to mobilise the midface from the base of the skull and to advance it in an anterior or inferior and mostly combined direction.

4.2.3.1 Extracranial Le Fort III osteotomy and advancement

At our craniofacial unit this procedure is reserved for older children and electively performed at a later age and is for that reason not part of any early surgery. Midfacial advancement has been usually performed in conjunction with intracranial procedures for cranial vault remodelling. However, it is a useful procedure at any age when indicated by airway obstruction and when no intracranial intervention is otherwise necessary. It has been applied in two of the patients in our series. The surgical approach is similar as described above; a bicoronal incision and dissection to free both orbits are performed. The orbital content is released extensively to provide access to the lateral, medial and inferior orbital walls. Medially the sacculus of the lacrimal apparatus is identified and preserved. In most cases the anterior ethmoid arteries need to be cauterised to prevent intra- and postoperative haemorrhage. The inferior orbital fissure is also identified. Horizontal osteotomies are then performed in the naso-frontal area under the level of the lamina cribrosa. These osteotomies are extended in the medial orbital wall just behind the lacrimal system, through the orbital floor and to the lateral orbital walls where they are brought out anteriorly at the level of the fronto-zygomatic suture. A bone spreader is inserted fronto-nasally and the cut surfaces of the bones are carefully separated a few millimetres. Through this opening the bony septum is divided with an osteotome under direct vision and by digital control with a finger reaching intraorally, just above the soft palate. The pterygomaxillary junctions are carefully and bluntly separated with a periosteal elevator. In some cases that had previous midface surgery,

one might not be able to separate the midface by a blunt technique, due to excessive reossification at the previous osteotomy site. Then great care must be taken not to injure any branch of the internal maxillary artery system. The whole midfacial segment is now mobilised with special forceps that are positioned under the palate and intranasally. For immediate advancement and interpositional bone grafts the midfacial segment should be completely free. If bone grafts are necessary the donor area of choice is cranial bone to provide membranous bone for grafting. This again necessitates an intracranial procedure with splitting of cranial bone. Other donor areas to provide cortico-cancellous bone are the iliac crest or rib bone.

4.2.3.2 Cranio-orbito-facial mobilisation (intracranial Le Fort III and IV)

In seven patients of this study group we performed immediate frontal-orbital mobilisation, cranial vault remodelling and facial mobilisation, all in one procedure at an early stage. Mühlbauer and Anderl first described and performed the cranio-orbito-facial mobilisation in one procedure in very young children (**see Figure 7**). This technique was further refined and utilised in the above mentioned seven patients with Kleeblattschädel deformity with good and consistent results (**see Figure 8**). After the supraorbital bar is elevated and removed, the orbits are exposed. Orbital osteotomies are performed in the same way as in the extracranial approach. Access to the septum is less difficult as the supraorbital bar and forehead are removed already. The disjunction of the pterygomaxillary junction is also performed bluntly with a periosteal elevator. The same facial disjunction forceps are used as in the extracranial approach (**Heeckt, 1988**) (**Heeckt et al., 1994**).

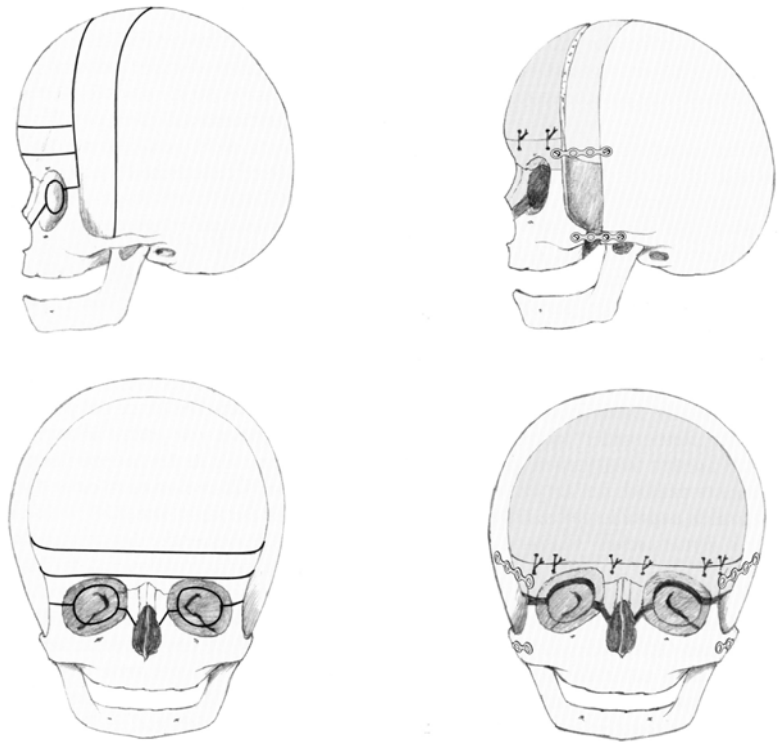

Figure 12 ‚Floating cranio-orbito-facial complex' according to Mühlbauer and Anderl (Heeckt et al., 1988)

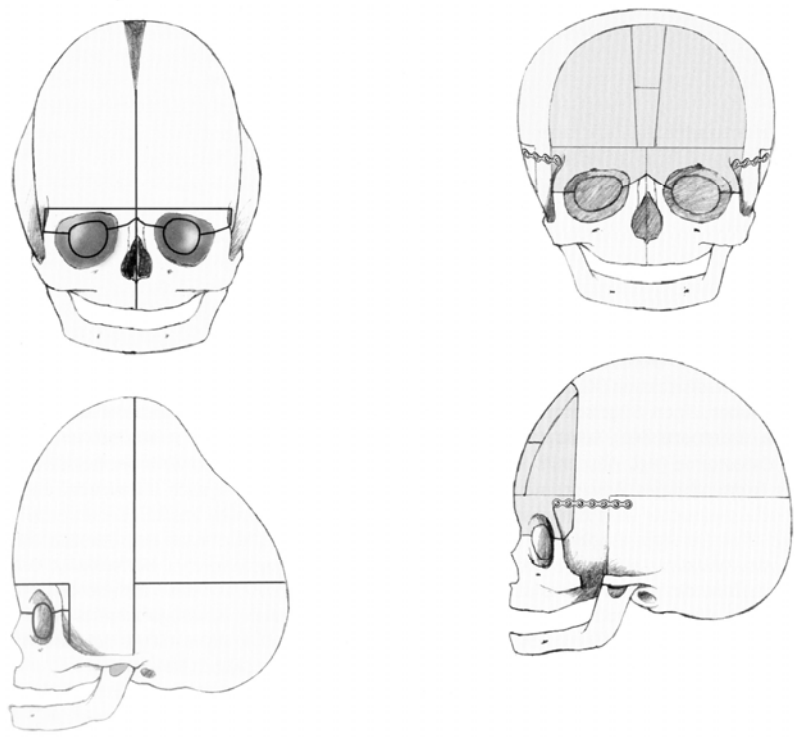

Figure 13: Subtotal Craniectomy with advancement of the frontal-orbital complex and the midface (Heeckt, 1994)

4.2.3.3 Monobloc advancement:

The forehead and orbital region rarely have an adequate and aesthetically normal shape in these severely deformed children. For this reason it is in most cases necessary to do a separate frontal-orbital remodelling, before the forehead and midface are advanced 'en bloc' as a unit. The osteotomies to free the midface from the base of the skull are the same as in a Le Fort III procedure with one exception: the supraorbital bar is left attached to the midfacial segment and the osteotomies run through the roof of the orbits. In a monobloc procedure it is necessary to open the anterior cranial fossa to perform the osteotomies. The monobloc segment can usually be advanced for about 10mm to 20mm and is fixated with rigid fixation plates and secured by cortical or cortico-cancellous bone grafts.

4.2.3.4 Midface distraction with or without osteotomies:

At our instituition, midface distraction in children up to 6 months of age is recently performed without major osteotomies. In most cases only the zygomatic arch is divided with a cutting osteotome. In infants who are older than one year we prefer to do complete standard osteotomies. Internal distraction devices are applied on the skull. All distraction devices as well as a specialised dynamic miniplate were developed at our institution. The proximal part of the distraction device is located in the temporal bone about 1cm above the ears bilaterally. The distal part is applied at the notch of the zygomatic bone at the temporal surface. Only the proximal part is rigidly fixated with srews and a plate which forms the footplate of the distraction device and is part of it. The distal part consists of a distal plunger which is specially designed to fit over this bony notch on the zygomatic bone. After the distraction device is applied it is slightly distracted, so that the distractor is in a secure position and cannot be displaced. A specifically designed dynamic miniplate is applied to the supraorbital bar on both sides and to the parietal skull bone. It is dynamic as it allows forward displacement of the forehead complex, but it restricts backward movement. In this way the forehead can move together with the distracted midface during distraction or can yield to the distending brain, which is not confined anymore by the synostosed skull. This hardware configuration is used for distraction without or with only limited osteotomies.
In the cases with standard midface osteotomies and a complete disjunction of the midfacial part, two sets of distractors need to be applied bilaterally. First, the above mentioned device

is applied on the same position. Second another distraction device with integrated plate and screw on both ends is fixated on the same positions as the dynamic miniplate in the cases without osteotomies. Both distraction devices need to be activated for simultaneous distraction. It is very important to define the requested vector of distraction and the distraction devices need to be placed accordingly. No change of direction is possible without reoperation and repositioning of the devices. The proximal end has the thread for activation of the distractor, which is brought out transcutaneously through a stab incision in the skin. Postoperatively the external part of the device is cleaned daily with antiseptic solution (**Figure 14**).

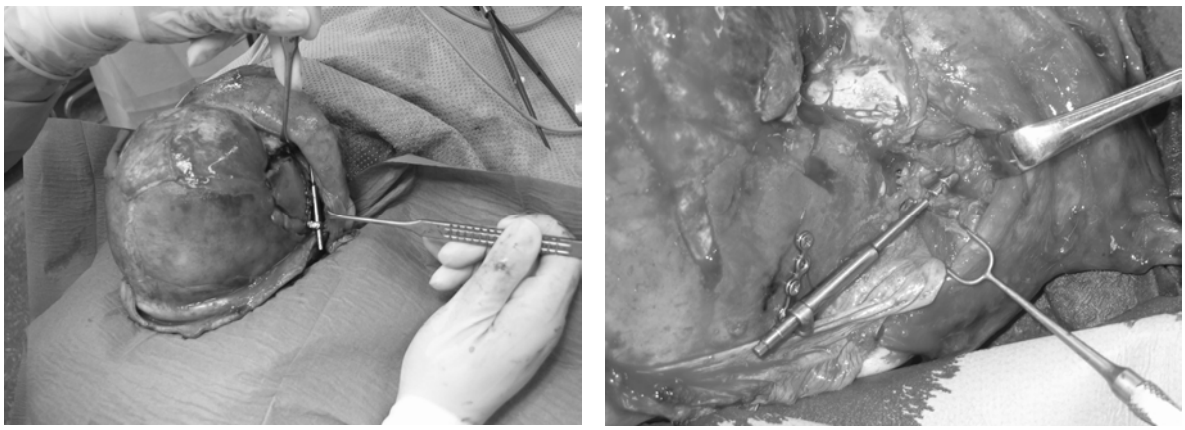

Figure 14: Placement of midafacial distractors, distal end at the posterior ridge and notch of the zygomatic arch-orbit junction and distal end on the temporal bone with the end sticking through the skin for activation

5 Results:

All 19 children of our series had typical features of Kleeblattschädel deformity and radiologically confirmed synostosis of multiple cranial sutures. Most patients had synostosis of the sagittal and coronal sutures. The lambdoid sutures were partially or completely closed in a number of cases. It was not possible to evaluate the condition of all cranial and facial sutures in the patients of our study group. Only a few cases had CT-Scans with three dimensional reconstruction and a precise diagnosis of sutural synostosis on conventional skull radiography was not possible (**Figure 15**).

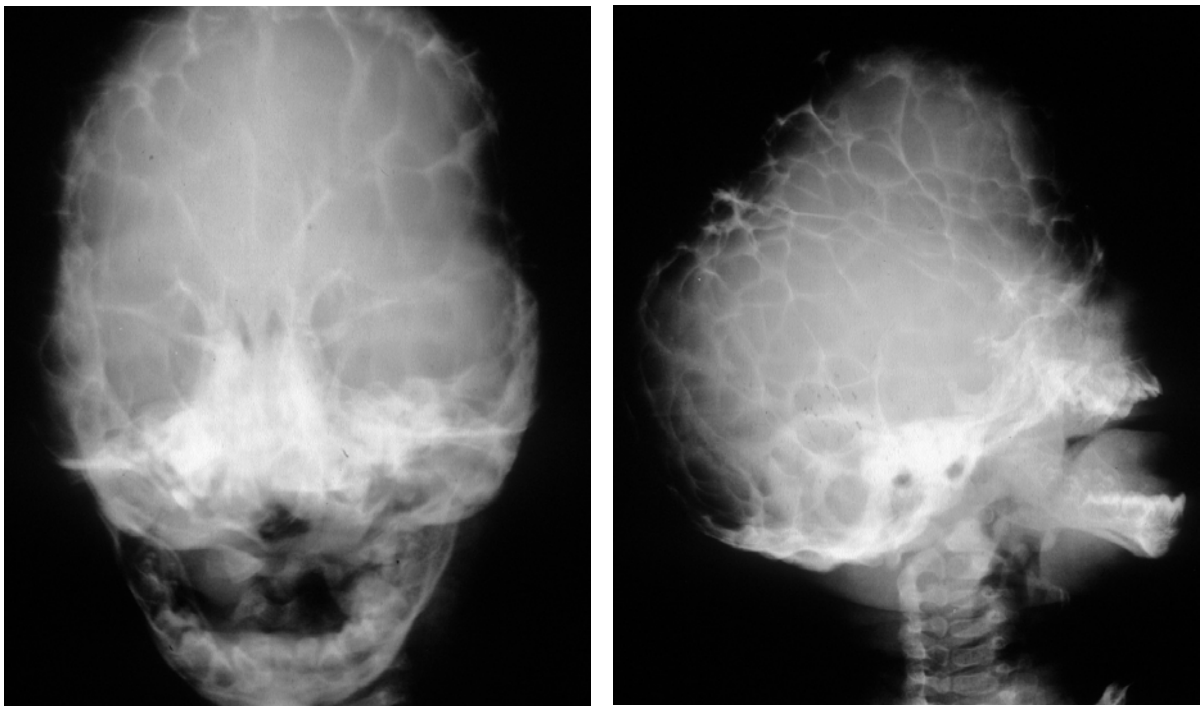

Figure 15: AP (antero-posterior) and lateral conventional skull radiographs of a patient with pansynostosis. Note the 'copper beaten' appearance of the skull bone, a sign of increased intracranial pressure and due to the pressure of the growing brain on the synostosed skull bone

Eleven patients (57,9%) were diagnosed as *pansynostosis* according to McCarthy et al., meaning a condition with premature fusion of more than three cranial sutures in the absence of any syndromic causes or features (**McCarthy et al., 1995**). Five children were diagnosed as Crouzon's syndrome (21,9%), three with Pfeiffer's syndrome (15,8%) and one child with Saethre-Chotzen's syndrome (5,2%) (**Table 9**) (**see Figures 16 and 17**).

Condition	Number	Percentage
Pansynostosis	N = 11	57,9%
Crouzon's syndrome	N = 4	21,1%
Pfeiffer's syndrome	N = 3	15,8%
Saethre-Chotzen's syndrome	N = 1	5,2%
TOTAL:	N = 19	100%

Table 9 Patients of the study group and underlying conditions

Figure 16: Left: Kleeblattschädel case with Pfeiffer' syndrome. Right: Crouzon's syndrome

Figure 17: Left: Kleeblattschädel deformity and Saethre-Chotzen's syndrome. Right: Nonsyndromic case with cloverleaf skull anomaly; Pansynostosis

More than half of the patients (57.9%) are non-syndromic cases, without any features of described syndromes. The other patients fall well into the syndromic group of craniosynostosis (42.1%).

Eleven children of nineteen (57.9%) presented with a communicating hydrocephalus. They were shunted either before or after surgery for internal decompression or remodelling craniectomy. In nine children (47.4 %), the hydrocephalus was shunted before any other surgery was done in order to give immediate relief to the compressed brain and to facilitate further craniofacial procedures. In two children (10.5%) the hydrocephalus developed at a later stage which required subsequent ventriculoperitoneal shunting.

Craniofacial surgery was performed in 16 children (84.2%). Primary craniofacial surgery was performed between the ages of 3 and 21 months (mean: 6.4 months). Primary surgery performed after 6 months of age was due to late referral of patients. One child that was not included in this group, died on the operating table immediately after the skin incision, before craniofacial surgery could be commenced. This child was a late referral and scheduled to undergo emergency cranial decompression at the age of 12 months. Four children (25.0%) underwent emergency intracranial operations for rapid decompression before the age of 6 months. Shunting procedures for hydrocephalus, temporary tarsoraphy, and tracheostomies were excluded. Seven of the sixteen children (43.8%) underwent primary midfacial advancement during the first craniofacial procedure. All sixteen children had frontal-orbital advancement performed primarily and fourteen (87.5%) received a partial or subtotal cranial vault remodelling procedure simultaneously. Postoperative follow-up time ranged from 8 months to 13.9 years with an average of 5.31 years. The majority of patients have been followed up for a long-term.

The child that died on the operating table, before surgery had been commenced, had a congenital heart defect and death was due to severe cardiac complications. Another patient who was severely affected, suffered from proptosis of the eye and unilateral blindness. He died from disseminated bacterial meningoencephalitis one week after the primary craniofacial procedure, which was performed as an emergency intervention for cranial decompression (**Figures 18 to 20**).

Figure 18: This patient had emergency craniofacial surgery for decompression of the synostosed skull at the age of 3 months. He had repeated tarsoraphies and suffered corneal ulceration on the left side from severe proptosis and blindness on the right side

Figure 19: Left: This intraoperative view shows the synostosed skull after exposure (L=occiput;R=frontal). Right: Note the immediate expansion of the brain after removing the restraining force of the bone. A frontal-orbital mobilisation and a subtotal cranial vault remodelling have been performed

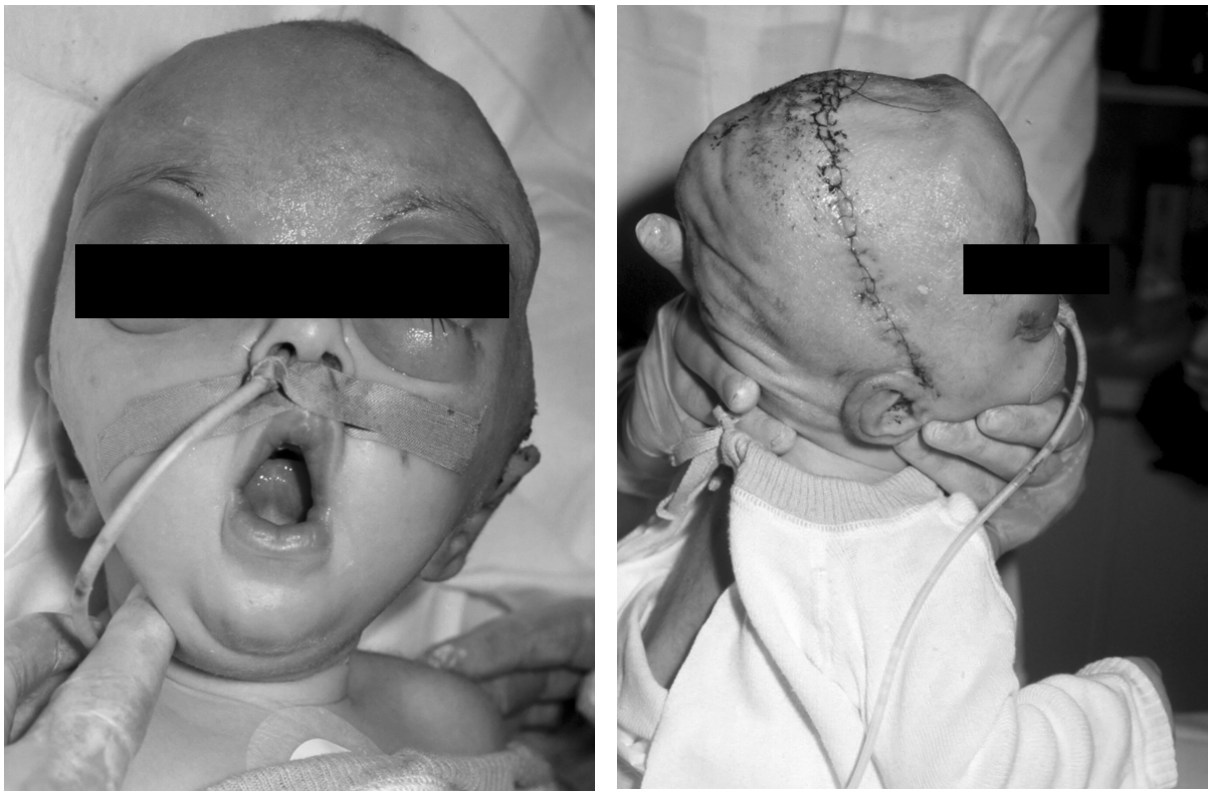

Figure 20: This was the shape of the head postoperatively. Unfortunately this child died 1 week after surgery due to a disseminated bacterial meningitis

One child was lost due to a severe pulmonary tract infection acquired after secondary surgery for miniplate removal and another child due to similar pulmonary infective complications after shunt revision (**see figures 21 to 23**). We found an overall mortality of 21.1% in our series of nineteen cases. The mortality in the operated group only was 19.0% (n=3).

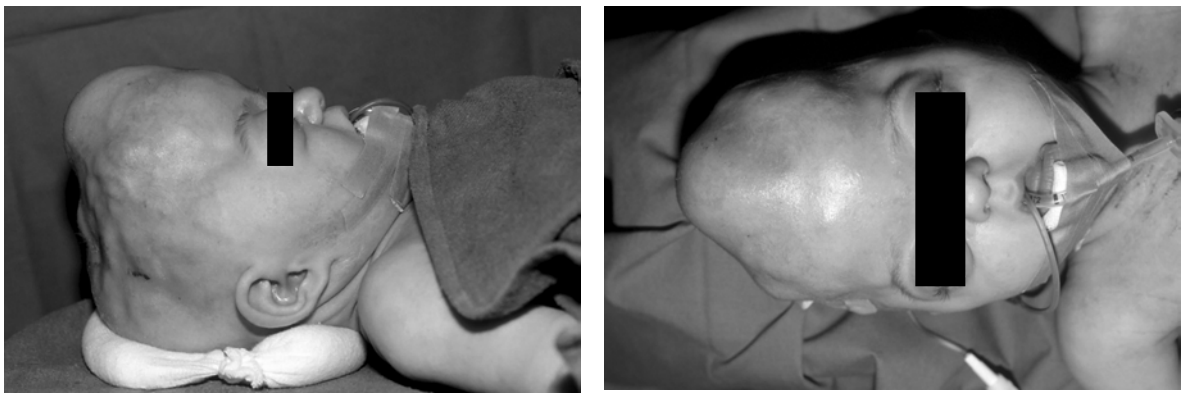

Figure 21: 7-month-old child with pansynostosis just before surgery. Severe case of trilobar skull shape with already visible midfacial retrusion

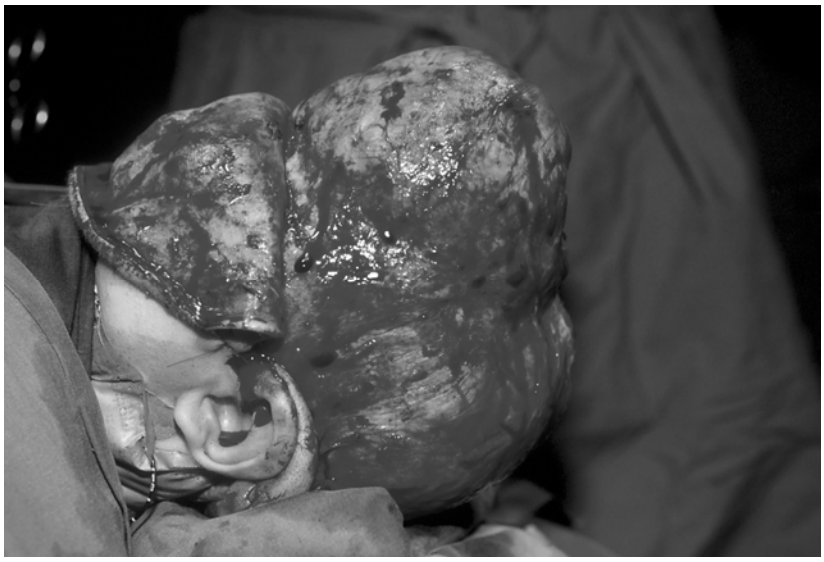

Figure 22: Intraoperative view of the same patient

Figure 23: These fotographs were taken 3 months postoperatively. Note the improved skull shape. Unfortunately, this child died from pneumonia 4 months after surgical shunt revision

One child (6.3%) had a posterior cranial vault remodelling with a posterior decompression (POM) at 9 months of age as a second stage procedure due to severe lambdoid suture

synostosis. Frontal-orbital advancement and anterior cranial vault remodelling was performed at 3 months of age.

Extensive secondary procedures for craniofacial decompression and remodelling had to be performed in two patients (12.5%). This was due to restenosis in the frontal-orbital region in one case and a secondary frontal-orbital mobilisation had to be performed. Another case developed restenosis that was more extensive, and a frontal-orbital advancement adjunctive to a subtotal cranial vault remodelling had to be performed. Onlay cranioplasties as touch-up procedures to improve the shape of the forehead were performed in two patients (12.5 %). These procedures were done extra-cranially, without opening the skull bone and getting access to the dura mater. Alloplastic material, namely methymethacrylate and hydroxyapatite had been used for inlay and onlay cranial augmentation respectively. Two patients underwent midfacial advancement procedures as secondary procedures with standard Le Fort III osteotomies (12.5%). In one case it was performed at the age of 20 months due to poor growth of the midface. Another patient had a secondary midface advancement procedure at 6 years of age, also due to midface hypoplasia. This patient had already a primary midface advancement performed at 4 months together with primary craniofacial decompression and remodelling. There are a few younger patients in our study group that might necessitate midface advancement surgery at a later stage.

In two of our patients the parents decided against a surgical intervention (12.5%). The first case had a typical cloverleaf deformity of the skull, but was lacking intracranial hypertension, hydrocephalus or other functional deficits. Skull radiographs taken directly after birth revealed that the posterior part of the sagittal suture and parts of the lambdoid sutures were still patent. The skull base was tilted almost to a vertical position and mild digital impressions were observed on conventional skull radiographs. The boy was carefully followed up over the next years. At the age of 7 years and 11 years no signs of intracranial hypertension or mental retardation have developed. The boy completed high school successfully and is presently a third-year medical student who is doing well. He has had no complaints and is satisfied with the aesthetic result (**Figures 24 and 25**).

Figure 24: Left: 3-year-old boy with pansynostosis. Conventional skull radiographs showed that parts of the sagittal suture and the lambdoid suture were still patent. He had no functional deficits or hydrocephalus and the parents decided against surgery. Right: The same patient at the age of 7 years with improved skull shape and a slight ptosis

Figure 25: The same patient at the age of 11 years. The skull shape has improved without any surgery done. The patient did well at school and is presently enrooled in his third year as medical student

All surviving children in our series developed well, without any clinical signs of elevated intracranial pressure or long-term neurological damage. Children with raised intracranial pressure due to hydrocephalus did well after successful ventriculoperitoneal shunting procedures. Elevation of intracranial pressure secondary to severe cranial synostosis and stenosis improved clinically after decompressive intracranial surgery. Vision was preserved in all patients. Aesthetic improvement ranged from good to satisfactory according to the evaluating surgeons and patient satisfaction. Mental development and intelligence is in the normal range so far and the children old enough could attend normal schools. Osteogenesis was not impaired by surgery as new bone formed and bone gaps were closed within 12 to 24 months postoperatively. Most children have nearly normal head shapes. Not a single case in our series needed a secondary operation to close any bone gaps on the skull. Some of our recent cases are still closely followed clinically and with serial 3D CT examinations but already show good bone regeneration. The skull circumference grew in most cases along the lower levels of the percentile, but was still in the normal range.

No.	Diagnosis	Surgical procedure	Age(mo)	Follow up: time (mo)	Follow up: result	Outcome (Whitaker et al.)	Cause of death
1	PS	SC, FOM	6 mo		Poor		
		MFA	1.6 years	15.5 years	Satisfactory		
		MFA	19 years	20.7 years	Satisfactory	III	
2	PS	SC, FOM	4 mo	14.3 years	Good	I	
3	PS	Planned: (SC, FOM, MFA)	12 mo		DIED		Congenital cardiac defect
4	Pfeiffer	SC, FOM, MFA	3 mo		DIED		Meningitis
5	PS	SC, FOM, MFA	6 mo	11.3 years	Good	I	
6	Crouzon	SC, FOM, MFA	4 mo		Restenosis		
		FOM	5 years		Satisfactory		
		MFA	6 years		Satisfactory		
		CP	7 years	8.1 years	Satisfactory	IV	
7	PS	SC, FOM	4 mo	6 years	Satisfactory	I	
8	PS	SC, FOM, MFA	7 mo	1.2 years	Good	I	
		Shunt revision	14 mo		DIED		Pneumonia
9	Crouzon	SC, FOM, MFA	12 mo	1.3 years	Good		
		Miniplate removal	15 mo		DIED		Pneumonia
10	Crouzon	SC, FOM, MFA	1.8 years	5.3 years	Good	I	
11	PS	SC, FOM, MFA	3 mo	4.2 years	Good	I	
12	PS	FOM	6 mo	7.3 years	Satisfactory	I	
13	PS	Not operated		23.2 years	Good		
14	Crouzon	Not operated		7 years	Satisfactory		
15	Pfeiffer	SC, FOM	6 mo	3.5 years	Good	I	
16	Pfeiffer	SC, FOM	6 mo	1.8 years	Good	I	
17	PS	SC, FOM	6 mo		Restenosis		
		FOM	1.5 years	5 years	Good	IV	
18	Saethre-Chotzen	SC, FOM	3 mo		Satisfactory		
		POM	9 mo		Good		
		CP	5.9 years	6.8 years	Good	III	
19	PS	SC, FOM	7 mo	1.3 years	Good	I	

Table 10 Clinical data of 19 patients with pancraniofacial synostosis (PCS). SC = subtotal craniectomy (cranial vaukt remodelling); FOM = frontoorbital mobilisation; MFA = midfacial advancement; CP = onlay cranioplasty with alloplastic material; POM = posterior-occipital mobilisation

All our patients could be grouped according to the Partington classification as type II or type III deformities. Four patients had cloverleaf skull anomaly in association with minor localised skeletal malformations (type II) and fifteen patients were without any skeletal malformations (type III). There were no patients in this series that fulfilled the description of thanatophoric dysplasia (type I) (**Partington et al., 1971**) (**Maroteaux et al., 1967**).

Partington classification	Number
Type I	N = 0
Type II	N = 4
Type III	N = 15

Table 11: According to Partington et al (Partington et al., 1971)

Outcome was classified according to Whitaker et al.'s categories. Miniplate removal was not included in additional procedures as we perform that as a standard procedure on each patient after 6 to 8 weeks. Only the craniofacial aspects of surgical management were considered, and tracheostomies, tarsorraphies and CSF shunting procedures were not considered. The three patients that died after surgery were excluded and not categorised as this would distort the results, as no real follow up could be done. No minimal procedures as described in category II were performed at any of our patients. Of the 14 remaining cases that were classified, ten had minor problems without needing further craniofacial surgery and belonged to category I (71.4%). One patient underwent a posterior occipital mobilisation (POM), but this was considered part of a staged primary procedure. However, he also underwent an onlay cranioplasty with hydroxyapatite at the age of 6 years and was then classified as category III (**Figures 26 to 29**).

Figure 26: Kleeblattschädel case with Saethre-Chotzen's syndrome preoperatively

Figure 27: The same patient after frontal-orbital advancement and anterior cranial vault remodelling. Note the flattened shape of the posterior skull

Figure 28: Posterior occipital mobilisation (POM) was performed as a second stage procedure at the age of 9 months. This is the postoperative view after 3 months

Figure 29: The same child at 5 years age. At this stage it was decided that the child needs some additional cranial contouring, especially in the region of the forehead. An 'onlay'cranioplasty was performed with hydroxyapatite at the age of 5 years and 9 months. These are preoperative fotographs

Another patient required a secondary Le Fort III osteotomy and advancement at the age of 20 months and a third Le Fort III operation was done at the age of 19 years. He was also added to category III. This made a total percentage of 14.3% category III cases. Two other patients needed extensive major craniofacial surgery after their primary craniofacial intervention. The first patient had a secondary frontal-orbital mobilisation at 60 months and a cranioplasty for cranial vault remodelling with methylmethacrylate at 4 years of age. With 6 years she underwent a secondary midface advancement procedure, namely a Le Fort III osteotomy and advancement (**Figures 30 to 35**).

Figure 30: Cloverleaf child with Crouzon's syndrome at initial presentation (1 mo)

Figure 31: The same patient at 5 months of age, awaiting surgery

Figure 32: At 2,5 years of age

Figure 33: At 5 years of age, the patient developed restenosis and frontoorbital dysplasia. A second frontal-orbital mobilisation and cranial vault remodelling was planned

Figure 34: At 10 years age

Figure 35: At 15 years of age

The second patient had after the primary frontal-orbital mobilisation (FOM) at 5 months, a secondary frontal-orbital remodelling (FOM) and total cranial vault remodelling at 17 months of age. Both patients fall into category IV (14.3%).

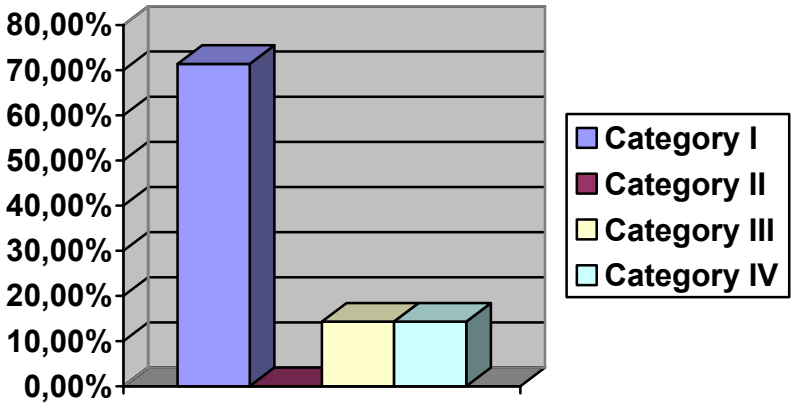

Diagram 1: Outcome and results according to Whitaker et al.

6 Discussion:

6.1 Review of literature

The natural history of nonsurgically treated children with the cloverleaf skull deformity and pancraniofacial synostosis has been described with a grim prognosis regarding survival past infancy, and those who do survive into childhood almost invariably suffer severe neurologic impairment (**Feingold et al., 1969**) (**Partington et al., 1971**) (**Holtermüller and Wiedemann, 1960**). Feingold et al. found that most children with this disorder have a marked degree of psychomotor retardation. Hydrocephalus is a constant finding and usually severe. It may be congenital or acquired, meaning it develops at the time of birth or at some point afterwards. It is in the majority of cases communicating, which occurs when the flow of cerebrospinal fluid (CSF) is blocked after it exits the ventricles. CSF can still flow between the ventricles, which remain open, thus it is called communicating. Non-communicating hydrocephalus occurs if the flow of CSF is blocked along one or more of the narrow pathways connecting the ventricles. In Kleeblattschädel deformity most cases of hydrocephalus are communicating. Non-communicating hydrocephalus has been described in only a few cases, where it was due to aquaductal stenosis. (**Feingold et al., 1969**).

The pathogenesis of hydrocephalus in cloverleaf skull is still controversial and not well defined. Angle et al. postulated that it is due to extraventricular obstruction caused by the malformation at the base of the skull and particularly by the small size of the foramen magnum. This may also be associated with invagination of the cerebellar tonsils (**Angle et al., 1967**). Berrada reported a case with an associated Arnold-Chiari malformation (**Berrada, 1963**). Müller and Hoffman described the possibility of venous compression and congestion due to parieto-occipital aplasia and constriction involving the lateral sinus. In these cases there is a marked dilation of scalp veins. Resection of the parieto-occipital “constriction band” appeared to have stabilised the hydrocephalus (**Müller and Hoffman, 1975**).

Due to the rarity of Kleeblattschadel deformity there are not many reports about the surgical treatment found in the medical literature. The first attempt at surgical correction of the deformity was reported by Angle et al. in 1967 (**Angle et al., 1967**). Subsequently, reports by Arseni et al., Zuleta et al., Rohatgi and Lodge et al. followed**.** Each reported small series of

children with the cloverleaf deformity who had undergone some attempt at surgical correction (**Arseni et al., 1972**) (**Zuleta et al., 1984**) (**Rohatgi, 1991**) (**Lodge et al., 1993**). In addition there have been anecdotal reports which describe variable corrections of the cosmetic deformity and preservation of neurological function in children who underwent decompressive surgery in early childhood (**Frank et al., 1985**) (**Müller and Hoffman, 1975**) (**Turner and Reynolds, 1980**). There is a lack of a consistent surgical philosophy as well as paucity of information regarding postoperative neurological function and cosmetic outcome. Only recently small series reported about their experience with this complex craniofacial disorder and outcome after early surgical treatment. Some guidelines are proposed and a generally more aggressive approach with early intracranial surgery and decompression has been applied.

Since patients with Kleeblattschädel often suffer both from a marked increase in intracranial pressure and a severe cosmetic deformity, reasonable management goals include the prompt reduction in intracranial pressure, as well as the establishment of an acceptable cranial appearance (**Renier, 1989**). Other related problems in this condition necessitating emergency treatment are respiratory obstruction and severe exophtalmus.

Resnick et al. reported the treatment and outcome of 7 children with the cloverleaf skull deformity between 1981 and 1993 (**Resnick et al., 1995**). Heeckt and Mühlbauer presented their experience with pancraniofacial synostosis and the Kleeblattschädel deformity during the 2nd international Congress of the International Society of Cranio-Maxillo-Facial Surgery (Florence, Italy) in 1989. In 1993 they reported 14 cases of pancraniofacial synostosis with features of Kleeblattschädel deformity and described the surgical management in 9 cases. (**Heeckt et al., 1993**) (**Mühlbauer et al., 1989**).

Lodge et al. described 10 children with Kleeblattschädel deformity who underwent cranial decompressive surgery several months after birth followed later by midfacial procedures (**Lodge et al., 1993**).

Rohatgi et al**.** presented a series of 6 patients with cloverleaf skull deformity which were treated between 1980 and 1988 (**Rohatgi, 1991**).

Hubli et al. reported a case with Kleeblattschadel deformity which needed early operative intervention at 5 days of age, where an emergeny decompression of the brain was performed. The childs native bone was unsuitable for reconstruction and an allogenic demineralised bone graft was used for calvarial reconstruction (**Hubli, Salyer and Gendler, 1998**).

Another case report of a single case describes a two staged craniectomy to correct this condition with acceptable cosmetic results (**Muller and Hoffman, 1975**).

Goh et al. report early surgery on another child with clover leaf skull and Gosain et al. describe their experience with a child with Apert syndrome and clover leaf skull features (**Goh et al., 1997**) (**Gosain et al., 1997**).

In Resnick's group all children (n=7) underwent an initial decompressive craniectomy with the removal of at least 50% of the cranial vault for relief of high intracranial pressure in early infancy, mostly in the first month of life. Delay in surgery beyond the first week of life were due to limitations imposed by the timing of referral as well as other serious medical conditions that required immediate attention. Follow up times are not specifically recorded and have not been very long in some cases. Four patients were treated with near total craniectomy without the replacement of the morcellated bone fragments. Despite the extensive nature of the decompression, the calvarium rapidly reformed circumferentially and each of the children required multiple subsequent reconstructive procedures. These repeat operations had a high rate of serious complications which led to the death of 2 children and neurological injury in a 3rd case. These complications led Resnick et al. to modify their initial decompression procedures. The 3 children treated subsequently have then undergone a staged approach with anterior craniectomy first, followed then at a second stage by posterior craniectomy with bone morcellation and replacement. This approach lowered the morbidity of the initial procedure in terms of cerebral contusion and blood loss and since the brain was always protected by either the anterior or posterior calvarium, positioning and nursing of the children was simplified. Second the bone fragments were morcellated and partially replaced which led to increased new bone formation. The bone was thicker and less adherent to the underlying dura, than with the previous technique. Fronto-orbital advancement was delayed until 6-12 months of age, by which time the frontal bone had fully reformed and provided a stable basis for advancement. Resnick et al. found that fronto-orbital advancement performed in the neonatal period frequently needed to be repeated later in infancy or childhood. When

the initial procedure was delayed until 6 – 12 months of age, this seemed to be less of a problem.

Based on these findings and upon a review of the literature concerned with this problem, they recommended a treatment algorithm for children with Kleeblattschädel (**Resnick et al., 1995**):

<u>Algorithm for the treatment of cloverleaf skull deformity (Resnick et al., 1995):</u>

1. A full medical, otolaryngologic, ophthalmologic, and radiologic evaluation on the 1st day of life (skull and cervical spine).
2. Early racheostomy if necessary (e.g. choanal atresia)
3. A preoperative CT scan
4. Decompressive craniectomy preferable during the 1st 48 hours of life
   i) Anterior craniectomy 1st
   ii) Posterior craniectomy at a 2nd stage (1 month later)

During anterior craniectomy the cranial bone is removed in a piecemeal fashion and the orbital bar anterior is left in place. Care is taken not to injure the dura mater and brain when removing the bone, which can be exceptionally thin and irregular in these cases. A ventriculostomy catheter may be placed, depending on the tenseness of the dura and on the degree of ventriculomegaly seen on the preoperative CT-scan. The craniectomy is continued posteriorly and include the lamdoid sutures. When an adequate decompression has been obtained, the calvarial bone fragments are morcellated into 2- to 3cm fragments. The fragments are moulded to give a normal shape and then fixed to the underlying dura with 4-0 sutures.

The posterior craniectomy is performed about one month later, when there has been adequate bone ossification anteriorly to permit prone positioning of the child. Bone is removed in a similar fashion, from the lambdoid sutures anteriorly to the foramen magnum posteriorly and to the petromastoid region laterally.

Resnick et al. stresses the importance of an experienced multidisciplinary craniofacial team in the long-term management of these children. A staged surgical approach is preferred due to (1) decreased blood loss in the newborn infant, (2) better protection fot the brain both intra-

and postoperatively, and (3) easier nursing and thus better nutritional status in the postoperative period (**Resnick et al., 1995**).

Lodge et al. from Australia described 10 children with Kleeblattschädel deformity who underwent cranial decompressive surgery several months after birth followed later by midfacial procedures. They underlined three main problem areas with Kleeblattschädel deformity, which need to be addressed in a three-tiered approach (**Lodge et al., 1993**):

1. the severe *cranio-orbitofaciostenosis*
2. *hydrocephalus*
3. systemic effects of *extra cranial disturbances*

All patients were referred early for assessment and treatment. Two patients had undergone urgent tarsorrhaphies as a temporary means of protecting the exposed globes. The two patients were from South East Asia and the procedures were done there prior to their transfer for primary orbitocranial decompression. Early comprehensive sutural decompression was the primary therapeutic intervention. In the initial patient, coronal and posterior craniectomies were performed and in all subsequent patients, staged combinations of fronto-orbital advancement and lambdoidal craniectomies. The advanced fronto-orbital bar required onlay augmentation and reinforcement with available calvarial bone to achieve a stable, appropriate supraorbital position, while the lambdoid craniectomy must be radical, and communicating anteriorly with the region of the coronal craniectomy in order to be adequately decompressive. In most cases there was an extreme attenuation and sometimes even absence of calvarial bone so that many of the required procedures amounted to a form of subtotal craniectomy. Due to the abnormal condition of the bone no conditional osteosynthesis techniques for bone fixation could be applied. Fixation of bone rendered exceptionally difficult in this cases. Nine of their patients (90%) required ventriculoperitoneal shunting for correction of hydrocephalus, if persistent after calvarial decompressive procedures. Four of these required subsequent early revisions to maintain patency and unresolved extreme hydrocephalus were evident in two patients (20%). There have been no midfacial procedures been performed at age less than one year.

Proptosis and eyelid retraction in the early stages proved particularly refractive. Conventional tarsorrhaphy techniques sufficed only for short periods before cutting out because of the extreme tension. In one patient, formal release of the medial canthi from their bony

attachments afforded some release of tension and more prolonged protection of the globe. Corneal scarring as a consequence was frequent.

The principal determinant of early outcome for the patients was the management of the severe faciostenosis and associated multilevel airway compromise. The midface is underdeveloped in most cases and retropositioned, severely restricting the nasopharyngeal space and nasal passages. The soft palate is frequently elongated, flaccid, and draped like a flap valve over the base of the tongue, which is also displaced posteriorly in association with the relatively small mandible. Most patients required prolonged airway support, including mechanical ventilation during the first 6 to 12 months. Despite these measures four patients died from respiratory related problems. Lodge et al. stress the need for a tailored therapeutic approach ranging from judicious use of short-term, intensive, non-surgical airway support (e.g.CPAP), prolonged mechanical ventilation, adenotonsillectomy, uvulopalatopharyngoplasty, palatal split, tracheostomy, and Le Fort III advancement. The major determinant of mortality in Lodge's series remains the management of the faciostenosis and the associated airway compromise. An overal mortality of 40% was reported. (**Lodge et al., 1993**).

Rohatgi et al. presented a series of 6 patients with cloverleaf skull deformity which were treated between 1980 and 1988 (**Rohatgi, 1991**). All showed typical features of the Crouzon type of craniofacial dysostosis with variable degrees of exorbitism, raised intracranial pressure and mental retardation. All patients had typical features of cloverleaf skull deformity and radiological showed expanded middle cranial fossae with shortened anterior and posterior fossae and honeycomb appearance in the occiput.

The treatment modalities for brain decompression and remodelling have been linear craniectomy to remove the stenosed coronal, lambdoid and squamosal sutures. In another, more severe case a morcellation cranioplasty of the frontal, parietal and squamous temporal bone was performed. Other treatment options include subtotal calvariectomy and frontal-orbital advancement. Additional duroplasty at the site of strictured dura has been performed in one case and in another the central bony bulge of the cranial vault had been excised. Frontal-orbital advancement had been done by Hoffman's technique and with the tongue in groove technique. Age at surgery varied from 7 weeks to 4.5 years. The best results were observed in the youngest infant, 7 weeks old, following morcellation cranioplasty, duroplasty, orbital decompression and delayed ventriculoperitoneal shunt. In older infants with severe craniosynostosis and exophtalmus, morcellation cranioplasty with frontal-orbital advancement

by tongue-in-groove technique gave satisfactory results. Early survival in this series was 100% and late survival 50%, with the surviving patients having normal intelligence and acceptable cosmetic results. The authors recommend early cranial remodelling and decompression, as well as early cerebrospinal fluid diversion if necessary. (**Rohatgi, 1991**).

Hubli et al. report the management of a five-day-old child with multiple cranial suture synostosis. Plain films showed a copper-beaten appearance of the skull and the diagnosis of idiopathic non-syndromal pansynostosis was made. Surgery for cranial decompression was performed immediately at the age of six days. The skull had a cobblestone appearance intraoperatively and many small areas of dural penetration through the calvarium existed. The dura had to be carefully dissected from the bony fragments and the removed bone was extremely thin and segmented due to the multiple perforations. The native bone bandeau could not been used in this case and a strip of demineralised cortical iliac bone was used instead. The demineralised bone graft was 12.0 x 1.5cm in size and was secured with resorbable sutures. The patient had a posterior cranial vault remodelling 4 months later and was followed up 2 years after the initial procedure. Neurologically the patient was intact, but had developed a turrycephalic head shape. Subsequently a frontocranial vault remodelling was performed and it was noted that the demineralised bone bandeau had taken on the characteristics of the native bone. Microscopic evaluation displayed normal osseous architecture (**Hubli et al., 1998**).

Muller and Hoffman describe a case with Kleeblattschädel deformity that was operated on by them in 1965, at the age of 4 months. The child had a severe constriction ring suggestive of an hourglass shape, separating the enlarged middle cranial fossa from the small constricted posterior fossa. Synostosis of the coronal and lambdoid sutures was present. The patient suffered of a communicating hydrocephalus and on the first procedure a lumboperitoneal shunt was placed. Ten days later the first stage craniectomy took place, during which a linear type craniectomy was performed with removal of the constriction band up to the level of the transverse sinuses. Three weeks later, on the second stage, an occipital craniectomy was carried out with a posterior release and removal of constricted bone up to the foramen magnum. The cranial configuration improved and at the age of 5 years a hypertelorism correction was performed. The patient has been followed up for 9 years postoperatively and displayed significant intellectual and growth retardation (**Muller and Hoffman, 1975**).

Goh et al. reported a case of Kleeblattschädel in 1997. In addition to the cloverleaf-type skull deformity some features of Pfeiffer syndrome were present. Early surgery was performed at four weeks of age due to the rapid progression of cranial vault height, increasing anterior fontanelle tension, and corneal abrasions following the severe proptosis. The surgery was performed in the modified prone position to give access to both frontal and occipital regions. Frontal, parietal and occipital craniotomies were performed and bone was elevated. The hard bony ridges overlying the synostosed sutures were burred down and after satisfactory decompression the bone pieces were replaced and fixated loosely with resorbable suture material and fibrin glue. Postoperatively the patient developed hydrocephalus with ventriculomegaly due to aquaduct stenosis and a ventriculoperitoneal shunt was inserted. Frontal-orbital advancement was done electively two months later and the corneal abrasions healed with no visual impairment. Goh et al. as well as Zuleta et al. favour early total craniectomy to reverse the hydrocephalus in the neonatal period. They suggest that hydrocephalus is not an invariable complication which is always present but it is rather secondary to the obliteration of the cortical subarachnoid spaces and the presence of a cranial constriction ring. The child was followed up for one year with no signs of restenosis and normal neurological development (**Goh et al., 1997**).

Another single case of a child with Kleeblattschädel deformity was reported by Gosain et al. in 1997. It was a case with Apert's syndrome with a trilobed skull shape secondary to bitemporal and frontal bossing. Some anomalies of the sphenoid bone anatomy in the cranial base could be identified. The lesser wings of the sphenoid bone were displaced superiorly and followed the fused coronal sutures on both sides. They met on a single point on the skull vertex and formed a vertical constrictive structure or band in this patient. The patient underwent a craniectomy at two months of age. Both stenotic coronal sutures and the right lambdoid sutures were removed and the stenosis and constriction band were released. At eight months of age a frontal-orbital advancement and anterior cranial vault remodelling was performed. The skull shape improved and showed correction with growth but a hydrocephalus developed and a ventriculoperitoneal shunt had to be placed. At two years of age the patient showed increasing turrycephaly and exorbitism and a repeat frontal-orbital advancement and cranial vault reshaping had to be done. The patient was followed up until 16 months after the last surgery and showed improvement in skull shape with a tendency to gradual progression of the turrycephalic characteristics. Although the trilobar shape could be corrected through early surgery, the long-term progressive turrycephaly in this patient with Apert's syndrome remained unsolved (**Gosain et al., 1997**).

Authors	n	Craniofacial Procedures	Age at surgery	Follow-up	Results
Angle et al.(1971)	1	Subtemporal decompression and cranial morcellation procedure	3.5 mo	12 mo	Left hemiparesis, marked abnormal skull shape
Arseni et al. (1972)	2	Bagdasar-Arseni procedure	3 mo – 6 years	3-5 mo	Neurological disability in both, acceptable cosmetic result in younger child
Müller and Hoffman, (1975)	1	Linear craniectomy (4mo), posterior decompression (5mo), Hypertelorism correction (5 years)	4 mo	9 years	Significant intellectual and growth retardation
Rohatgi et al. (1991)	6	1 linear craniectomy (3mo), 3 radical craniectomy ± FOM (2-3mo), 2 tongue in groove procedures (11mo-4.5 years)	2 mo-4.5 years	5-12 mo (mean=9 mo)	3 children died (3 mo – 2.5 years postop), 2 with good cosmetic result, 1 satisfactory, all intellectually normal
Heeckt et al. (1993)	11	Subtotal craniectomy and FOM	3 – 21 mo (mean=7.5mo)	3mo -12 years (mean=5 years)	2 children died, others have normal mental development and good to satisfactory aesthetic appearance
Lodge et al. (1993)	10	Combination of coronal ± lambdoid craniectomy with FOM	2weeks – 8 mo (mean=4mo)	8 mo – 19 years (mean 50 mo)	5 children died, all surviving children had CSF shunting;
Resnick et al. (1995)	7	Near-total calvarectomy (n=4), staged anterior and posterior craniectomy (n=3)	1st week – 1st mo	17 mo – 9 years (mean = 61 mo)	4 children with good outcomes (3 with staged procedures), 1 child severely impaired, 2 died
Goh et al. (1997)	1	Subtotal craniectomy (4 weeks), FOM (3 mo)	4 weeks and 3 mo	1 year	Normal neurologic development
Gosain et al. (1997)	1	Linear craniectomies (2mo), FOM (8mo), FOM (2 years)	2 mo, 8 mo and 2 years	16 mo	Turrycephaly progressively returning

Hubli et al. (1998)	1	Subtotal craniectomy (6days), posterior cranial vault remodelling (4mo), Fronto-cranial vault remodelling (2 years)	6 days and 4 mo	2 years	Neurological normal, turrycephaly
Our series	16	Subtotal craniectomy, FOM,POM, Midfacial advancement	Mean = 6.2 mo	1.2 years to 15.5 years	Mortality 19.0%, remaining with satisfactory results 71.4% (n=10)

Table 12: Table with summary of reported surgical management of cloverleaf skull deformity; FOM = frontal-orbital mobilisation , CSF = cerebrospinal fluid, POM = posterior occipital mobilisation

6.2 Discussion of techniques

Early descriptions of Kleeblattschädel deformity frequently reported very severe cases with a high mortality. Some authors suggested that survival of only a few months is possible even in the patients who belong to group III without skeletal manifestations and a less severe degree of malformation (**Partington et al., 1971**). Surgical treatment for these cases has only been considered recently. The same surgical techniques that have been invented and developed for craniofacial surgery in general have been found very useful in this condition too. Mortality rates have fallen dramatically and almost no survival was recorded in early series. Today mortality is in the range of 20 to 50%. Saji et al. reported a mortality rate of 29% in their series (**Saji et al., 1977**). We have a total mortality rate of all patients in our series of 21% (n=4). One patient died before he had been operated on. The mortality rate in the surgical group of our series is 17.6% (n=3). This compares favourably to other reported series. Resnick et al. reported a mortality of 28.6%. Lodge et al. and Rohatgi et al. both reported a 50% mortality rate.

Reviewing the literature on Kleeblattschädel deformity and its surgical management clearly demonstrates that Kleeblattschädel or cloverleaf skull deformity is not a uniform diagnosis or deformity. There is a wide spectrum of clinical and morphologic manifestations of this condition. Patients with Kleeblattschädel deformity can present as a life threatening condition with severe craniostenosis right at birth, necessitating immediate emergency intracranial surgery. Some have a more gradual onset of increased intracranial pressure. In these cases the surgery can be planned in advance and be scheduled as an elective procedure. Others

show the typical skull shape which is characteristic for this condition but lack clinical symptoms. We had two early cases with Kleeblattschädel deformity in our series, where the parents declined any surgery. Both had a moderate degree of clover leaf skull deformity. They showed the typical morphology of this deformity with trilobed skull, temporal bossing and bossing of the fronto-parietal part of the skull. Intracranial hypertension was completely absent in one case. The second case had papilledema, but no other signs or symptoms of increased intracranial pressure. Both were followed up closely for many years and interestingly improved in appearance with increasing age. They had no neurological sequelae, both were good students at school and one of them is presently enrolled at medical school and does well. This supports our theory that Kleeblattschädel deformity represents a heterogeneous group of patients with similar morphological appearance and with a multifactorial aetiology. It is a specific skull shape due to sutural synostosis and is associated in the majority of cases to a severe clinical course. Different approaches and treatment regimens for this complex problem exist and are suggested. However, some common guidelines are found.

The improvement in survival rates since the first descriptions of this condition until today are very promising. It reflects the advances and progress made in modern craniofacial surgery, especially in the last 30 years. While surgery has not been an option in these cases at all for many years, it has evolved from rather hesitant attempts of correction with high mortality rates to high tech and extensive procedures with much better survival rates. But there are still pit falls and one rigid generalised treatment protocol for Kleeblattschädel does and should not exist, although proclaimed by some authors. The series reporting their experience with Kleeblattschädel deformity are relatively small due to the rarity of this condition. Some authors report their experience with a single or just a few cases and give exact guidelines for the treatment of Kleeblattschädel deformity in general. Some of the cases that are described represent a very mild degree of this condition. Some of these, on the other hand, would have been excluded in our series.

Kleeblattschädel deformity is a multifaceted problem with a wide range of anomalies. The trilobar shape on its own is not a predictor of survival or severity. But it is a warning sign for possible problems and complications. Raised intracranial pressure due to severe cranial stenosis is but one of the possible sequeleae. Upper respiratory tract obstruction and progressive sleep apnoe due to midface hypoplasia is another important aspect, which can have fatal consequences. Severe exorbitism can lead to blindness and hydrocephalus, which

is congenital in some cases due to intracranial anomalies can exaggerate raised intracranial pressure. An individualised treatment plan which is problem orientated needs to be set up for each case.

Early surgery is favoured by most authors and should be recommended. Certain procedures did prove to do better than others; however, some patients with this deformity might not need surgery at all, while others need emergency surgery immediately after birth.

What are needed are competent craniofacial teams that are able to decide when and whom to operate. This team should have wide experience in craniofacial surgery and be capable of planning and performing all necessary procedures, which are then decided on in a team approach. The team should be headed by an experienced craniofacial surgeon located at a center of excellence in this field.

Craniofacial surgery is ideally planned and performed as elective surgery. Thorough investigations and careful planning should be routinely done in all cases. Only in life-threatening situations should this rule be broken, in order to save life and with the least minimal procedure necessary in this situation. Any other major corrections and surgery can be delayed to a later stage.

At our craniofacial center we prefer to correct craniofacial deformities at an early age. We think that early craniofacial correction is beneficial for the child in many different aspects (**Mühlbauer et al., 1989**). Especially in non-syndromic cases of craniofacial synostosis we find that by early operation better aesthetic results are achieved and spontaneous dynamic remodelling can take place. A better final head shape can be accomplished and better functional and neurological outcome. Post-surgical bony skull defects regenerate and reossify almost completely when operated between 3 and 6 months of age and grafting at a later stage is only needed in rare instances. Early surgery also improves the clinical course and outcome in syndromic cases, in spite of their inherent tendency to maintained or progressive growth disturbances. Elective craniofacial surgery is ideally done between the ages of 3 and 12 months and most of our cases are scheduled for surgery at about 6 months of age (**McCarthy et al., 1995**).

This is also true for cloverleaf cases. Most reported series on cloverleaf skull confirmed this in their experience. Most authors performed the first procedures in cloverleaf case between 6

days and 4.5 months with a mean of 2.8 months. The children that were operated at a later age were either referred late or been treated at another less experienced center before.

The most frequently performed procedures are linear craniectomies which entail removal of synostosed sutures and constriction bands in most cases. This technique is often described as strip craniectomy and has been a popular early technique to correct craniosynostosis. Another commonly used technique in clover leaf skull has been total or subtotal craniectomy with morcellation of bone with removal of the bone or replacement and remodelling of the skull. In the later series cranial vault remodelling gains wider acceptance and is commonly used. Initially a total cranial vault remodelling was performed by some authors who then changed in later cases to a staged cranial vault remodelling to lower the postoperative morbidity. The anterior and posterior parts of the cranial vault were remodelled at different stages. More recently forehead remodelling and advancement of the supraorbital bar and forehead as a unit has been applied to Kleeblattschädel cases with good and consistent results. Decompression of the anterior part of the skull with immediate pressure release and lengthening of the anterior cranial fossa is achieved, as well as an aesthetic improvement in that region. The anterior cranial vault is remodelled during the same procedure (**Marchac, 1978**). Then, at a second stage, the posterior fossa can be enlarged by a similar posterior advancement of the occipital part of the skull. Posterior decompression and in some cases posterior occipital mobilisation (POM) need to be done before any other cranial procedure in cases with Arnold-Chiari malformation, in order to create space posteriorly and to prevent cerebellar herniation. Otherwise POM is done only in severe cases with lambdoid suture synostosis or posterior cranial stenosis. It is usually performed at a second stage after previous frontal-orbital mobilisation (FOM). Frontal-orbital mobilisation is in most cases the first craniofacial procedure done and in less severe deformities it is often the only procedure necessary.

Midfacial advancement is indicated in cases with severe midfacial hypoplasia. These patients often have prominent exorbitism and nasopharyngeal obstruction, from audible stridor and sleep apnoe to respiratory problems necessitating an emergency tracheostomy in rare cases. In our series we performed midfacial advancement in eight patients (42.1%), it had to be repeated due to relapse at a later stage in one patient (5.3%). In 7 patients it was done during the first craniofacial procedure as an intracranial frontal-orbitofacial advancement or le Fort IV procedure (**Heeckt et al., 1994**) (**Figure 33**). In a child with Crouzon syndrome a secondary Le Fort III advancement had to be performed at 6 years of age. In another child with pansynostosis midfacial advancement with a Le Fort III osteotomy was performed at a

second stage 14 months after the cranial vault remodelling at the age of 20 months. Recently, since 1994, we routinely perform midfacial advancement by distraction osteogenesis during the primary procedure of anterior cranial vault remodelling at the age of 6 months. Midfacial advancement in these young babies can be done without or only with minor osteotomies of the facial skeleton. With this technique the morbidity of surgery can be significantly reduced (**Fairley et al., 1995**) (**Mühlbauer, 1995**). Distraction osteogenesis as a means of treating midfacial or mandibular hypoplasia has not been reported yet in any series on Kleeblattschädel deformity. It is a useful technique and should form part of the armamentarium of craniofacial teams that treat cloverleaf skull deformity.

Severe exorbitism is most effectively addressed by frontal-orbital and midfacial advancement. If both, the forehead and the midface are retruded the monobloc procedure with distraction is the procedure of choice. Tarsorrhaphy and occlusive therapy are only temporary measures until definite surgical treatment can take place.

Both abnormal cerebrospinal fluid (CSF) hydrodynamics and craniosynostosis may result in raised intracranial pressure. Intracranial CSF volume can increase in two ways: dilation of the ventricular cavities and dilation of the pericerebral spaces. Both of these may be observed before or after craniofacial surgery and may be static or evolve to cause symptomatic intracranial hypertension. Cinalli et al. reviewed 1727 cases that underwent craniofacial surgery and studied the incidence of hydrocephalus (**Cinalli et al., 1998**). They found that hydrocephalus almost never occurs in cases with single suture synostosis, but it is rather frequent in cases of syndromic craniosynostosis, especially in Crouzon and Apert syndrome. In cases of Kleeblattschädel deformity it is almost a constant finding. Jugular foramen stenosis at the skull base and crowding of the posterior fossa are probably the two main factors causing it in Crouzon syndrome and Kleeblattschädel deformity. In Apert syndrome ventricular dilation is more common and may reflect a more widespread brain malformation. Eleven children (57.9%) of our series presented with a communicating hydrocephalus, which was shunted either before or after surgery for cranial decompression and remodelling. In nine children (47,4 %), the hydrocephalus was shunted before any other surgery was done in order to give immediate relief to the compressed brain and to facilitate further craniofacial procedures. In two children (10,5%) the hydrocephalus developed at a later stage which required subsequent ventriculoperitoneal shunting. We also found through our experience with syndromic craniosynostosis that children with uncontrolled or badly controlled hydrocephalus often develop an unsatisfactory skull shape postoperatively. In all series this

seems to be a problem and there is no uniform opinion about pre or postoperative shunting. Golabi et al. and Persing et al. advice to perform ventriculoperitoneal shunting before decompressive cranial surgery, whereas Goh et al. prefer to perform the cranial decompression first (**Golabi et al., 1987**) (**Persing et al., 1989**).

Recent developments in prenatal diagnosis of congenital craniofacial deformities and hydrocephalus suggest that foetal surgery might deliver an answer for this problem in the future. Feingold et al. suggested that Kleeblattschädel deformity is too advanced at birth to merit surgical intervention (**Feingold et al., 1969**). Hydrocephalus and raised intracranial pressure are often present before birth in cloverleaf cases. The possibilities of foetal surgery and prenatal shunt placement may prevent neurological damage and facilitate elective surgery under controlled circumstances to decompress the confined brain in these cases (**Sutton et al., 2001**) (**Oi et al., 1999**).

7 Conclusion:

In analysing our own surgical experience in 16 cases in this series of 19 patients, and in reviewing the current literature on the management of Kleeblattschädel deformity, we come to the following conclusions:

I. Kleeblattschädel deformity represents a heterogeneous group of patients with similar morphological appearance and with a multifactorial aetiology. It is a specific skull shape due to sutural synostosis and is associated in the majority of cases with a severe clinical course.

II. Most described cases in the past had limb deformities and belonged to a group with fatal prognosis. In times of modern craniofacial surgery, mortality rates and functional outcome have significantly improved, especially in Group III Partington patients. Mortality rates of less than 20% have been achieved.

III. Outcome according to Whitaker et al.'s classification has been good in 71.4% of operated patients requiring no further surgery or only minor interventions. 14.3% of

patients needed additional procedures and another 14.3% of cases needed additional major surgery

IV. Surgery on Kleeblattschädel cases should be planned and performed by a competent multidisciplinary craniofacial team. The team should be headed by an experienced craniofacial surgeon and be located at a center of excellence in this field.

V. A problem orientated treatment plan needs to be set up for each case individually.

VI. The first procedure for cranial decompression and remodelling should be done early, and on an elective basis. The ideal timing for surgery in our opinion is between 3 and 6 months, and before 12 months of age. This is supported by the results, the low morbidity and low mortality that were obtained in our study group.

VII. State of the art techniques in Kleeblattschädel cases are frontal-orbital advancement (FOM) with simultaneous anterior cranial vault remodelling and if necessary at a second stage posterior cranial vault remodelling (POM) with posterior fossa release. These techniques show good and consistent results. Total cranial vault procedures and strip craniectomies should be avoided as they are associated with higher morbidity and less satisfactory outcomes.

VIII. Midfacial advancement is indicated in cases with severe midfacial hypoplasia leading to exorbitism or respiratory obstruction. Distraction osteogenesis is a useful technique reinvented for the use in the craniofacial skeleton. It can achieve more advancement by gradual distraction than conventional one stage advancement procedures with a less traumatic approach.

IX. Ventriculoperitoneal shunting of CSF before primary craniofacial surgery might be beneficial in cases with increased intracranial pressure and hydrocephalus. Hydrocephalus is frequently caused by venous stasis due to the abnormal cranial base anatomy in Kleeblattschädel deformity. This will not improve after craniofacial decompression in most cases.

X. *A look into the future*: recent developments in prenatal diagnosis of congenital craniofacial deformities and in foetal surgery suggest that in utero CSF shunting may prevent neurological damage and facilitate elective surgery.

8 Summary:

8.1 Summary

Kleeblattschädel is one of the most severe forms of craniosynostosis and is caused by premature fusion of multiple or all skull sutures. It is associated with several craniofacial syndromes and also occurs in isolated pansynostosis. In this condition cranial sutures close already in utero and the children are born with the typical trilobar skull deformity. Kleeblattschädel deformity is a potentially life-threatening condition that in many cases necessitates emergency intracranial surgery, sometimes even in the very first days of neonatal life. Emergency situations arise with increased intracranial pressure and hydrocephalus, severe exorbitism and prolaps of the orbital contents. Respiratory problems and upper airway obstruction due to severe midfacial hypoplasia contribute to the high morbidity and mortality in this condition. The treatment of Kleeblattschädel deformity is an extreme challenge for the craniofacial surgeon. This is a retrospective study of nineteen patients with pancraniofacial synostosis and Kleeblattschädel deformity who were evaluated and treated by the 'Arbeitsgemeinschaft Kraniofaziale Chirurgie' in Munich, Germany, between 1978 and 2003. It represents a 25-year experience of dealing with this complex condition. The surgical management and outcome of our cases is presented and discussed. A review of the literature concerning Kleeblattschädel deformity is presented and discussed with a special emphasis on surgical treatment. Guidelines for the surgical management are proposed and discussed. Surgery on Kleeblattschädel cases should be planned and performed by a competent multidisciplinary craniofacial team. The team should be headed by an experienced craniofacial surgeon and be located at a center of excellence in this field. An individualised treatment plan which is problem orientated needs to be set up for each case. The ideal timing for surgery in our opinion is between 3 and 6 months, and before 12 months of age. State of the art techniques in Kleeblattschädel cases are frontal-orbital advancement (FOM) with simultaneous anterior cranial vault remodelling and if necessary at a second stage posterior cranial vault remodelling (POM) with posterior fossa release. These techniques show good

and consistent results. Total cranial vault procedures and strip craniectomies should be avoided as they are associated with higher morbidity and less satisfactory outcomes. Midfacial advancement is indicated in cases with severe midfacial hypoplasia leading to exorbitism or respiratory obstruction. Distraction osteogenesis is a useful technique reinvented for the use in the craniofacial skeleton. Ventriculoperitoneal shunting of CSF before primary craniofacial surgery might be beneficial in cases with increased intracranial pressure and hydrocephalus. Recent developments in prenatal diagnosis of congenital craniofacial deformities and in foetal surgery suggest that in utero CSF shunting may prevent neurological damage and facilitate elective surgery.

8.2 Zusammenfassung

Kleeblattschädel ist eine Folge multipler, meist angeborener Schädelnahtsynostosen und kommt vor bei schwerstgradigen kraniofazialen Syndromkomplexen sowie Pansynostosen. Die kraniofaziale Dysmorphie beim Kleeblattschädel wird assoziiert mit Hydrocephalus und erhöhtem intrakraniellen Druck, mit ausgeprägter Mittelgesichtshypoplasie, Exorbitismus und einer hohen Morbidität und Mortalität. Die Behandlung stellt eine extreme Herausforderung dar für den kraniofazialen Chirurgen. Diese retrospektive Studie von 19 Patienten mit der Kleeblattschädel kraniofazialen Dysmorphie beschreibt und analysiert die 25-jährige Erfahrung der Arbeitsgemeinschaft Kraniofaziale Chirurgie in München mit diesem komplexen Problem. Unsere Langzeitergebnisse und Behandlungsmethoden dieser Patienten werden dargestellt und analysiert. Vergleichbare Studien von anderen internationalen Behandlungszentren werden in einer Literaturstudie analysiert. Kinder mit Kleeblattschädel sollten von einem erfahrenen multidisziplinären kraniofazialen Team an einem anerkannten Zentrum behandelt werden. Ein problemorientierter Behandlungsplan sollte individuell für jeden Patienten erarbeitet werden. Wir empfehlen frühe elektive kraniofaziale Chirurgie zwischen 3 und 6 Monaten Lebensalter und vor dem ersten Lebensjahr. Die besten Ergebnisse wurden erzielt mit einer fronto-orbitalen Mobilisation mit Remodellierung der Stirn und dem vorderen Teil des Craniums. In manchen Fällen ist eine posterior-occipitale Mobilisation indiziert zur hinteren Schädeldekompression. Totale kraniale Remodellierung und sogenannte „strip-craniectomies“ sollten vermieden werden. Ein operativer Vorschub des Mittelgesichtes ist indiziert in Fällen mit schwerer Mittelgesichtshypoplasie und Exorbitismus. Distraktionstechniken ermöglichen einen schonenderen und weiteren Vorschub als herkömmliche Techniken. Liquorumleitungen sind wichtige adjuvante

Eingriffe und es erschließen sich neue Behandlungsmethoden bei angeborenem Hydrocephalus durch foetale Chirurgie.

9 References:

- Albright, A.L., Byrd, B.P. Suture pathology in craniosynostosis. J. Neurosurg. 54 (1981) 384-387
- Angle, C.R., McIntire, M.S., Moore, R.C. Cloverleaf skull: Kleeblattschädel deformity syndrome. Am. J. Dis. Child 114 (1967) 198-202
- Arseni, C., Horvath, L., Ciurea, Y. Cloverleaf skull. Acta. Neurochir. 27 (1972) 223-230
- Babler, W. J., Persing, J. A. Experimental alteration of cranial suture growth: Effects on the neurocranium, basicranium and midface. In "Factors and Mechanisms Influencing Bone Growth", Dixon, A.D., Sarnat, B.G. (Ed.), Arliss, New York, 1982,
- Babler, W. J. Alterations in cranial suture growth associated with premature closure of the sagittal suture in rabbits. Anat. Rec. 211 (1985)
- Bachmayer, D. I., Ross, R. B., and Munro, I. R. Maxillary growth following Le Fort III advancement surgery in Crouzon, Apert, and Pfeiffer syndromes. Am. J. Orthod. Dentofacial. Orthop. 90 (1986) 420
- Berrada, A. 1963-1964 Etude sur les craniostenoses en milieu morocain. A propos de 87 observations. These Medicale, Paris, no 182.
- Blechschmidt, E. "Humanembryologie: Prinzipien und Grundbegriffe" Hippokrates-Verlag, Stuttgart, 1974
- Bonucci, E. Nardi, F. The cloverleaf skull syndrome. Histological, histochemical and ultra structural findings. Virchows. Arch. Abt. A. 357 (1972) 199-212
- Burkhardt, L. Fisher, H. Pathologische Anatomie des Schädels. In: „Handbuch der speziellen Pathologischen Anatomie und Histologie" Uehlinger, E. (Hrsg.) Springer Berlin, 1970 1.Auflage
- Burkhardt, L. „Pathologische Anatomie des Schädels" Springer, Berlin:115, 1970.
- Carson, B. S., and Dufresne, C. R. Craniosynostosis and Neurocranial Asymmetry. In "Complex Craniofacial Problems", Dufresne, C. R., Carson, B. S. Zinreich, S. J. (Ed.), Churchill Livingstone, New York, 1992, 169

- Chin, M., Toth, B. A. Le Fort III advancement with gradual distraction using internal devices. Plast. Reconstr. Surg. 100 (1997) 819-830
- Cinalli, G. Sainte-Rose, C. Kollar, E. Hydrocephalus and craniosynostosis. J. Neurosurg. 88 (1998) 209
- Cohen, M. M. Cloverleaf syndrome update. Proc. Greenwood Genetic Center 6 (1987) 186-187
- Cohen, M. M. Craniosynostosis update 1986-1987. Am. J. Med. Genet. Suppl. 4 (1998) 99
- Cohen, M. M. “Craniosynostosis. Diagnosis, Evaluation and Management”, Raven Press, New York, 1986
- Cohen, M. M. Pfeiffer syndrome update, clinical subtypes and guidelines for differential diagnosis. Am. J. Med. Genet. 45 (1993) 300-307
- Cohen, M. M. “The child with multiple birth defects”, Raven Press, New York, 1982
- Cohen, S. R., Dauser, R. C., Gorski, J. L. Insidious onset of familial craniosynostosis. Cleft Palate Craniofac. J. 30 (1993) 401-405
- Cohen, S. R., Dauser, R. C., Newman, M. D. H., Muraszko, K. Surgical techniques of cranial vault expansion for increases in intracranial pressure in older children. J. Craniofac. Surg. 4 (1993) 167-173
- Cohen, M. Craniosynostosis and syndromes with craniosynostosis: Incidence, genetics, penetrance, variability and new syndrome updating. Birth Defects 15 (1979) 13
- Comings, D. E. The Kleeblattschädel syndrome – A grotesque form of hydrocephalus. Br. Clin. Lab. Obs. 67 (1965) 126-129
- Costantino, P. D., Friedman, C. D., Shindo, M. L., Experimental mandibular regrowth by distraction osteogenesis. Long-term results. Arch. Otolaryngol. Head Neck Surg. 119 (1993) 511-516
- David, J. D., Sheen, R. Surgical correction of Crouzon syndrome. Plast. Reconstr. Surg. 85 (1990) 344
- Delashaw, J. B., Persing, J. A., Broaddus, W. C., Jane, J. A. Cranial vault growth in craniosynostosis. J. Neurosurg. 70 (1989) 159-165
- Dietrich-Weinholdt, H. Ein Hydrocephalus chondrodystrophicus congenitus mit vorzeitigen Nahtsynostosen. Zieglers Beitr. Path. Anat. 75 (1926) 259-268

- Duncan, B. W., Adzick, N. S., Moelleken, B. R., Chua, J., Bradley, S. M., Longaker, M. T., Levinsohn, D. G., Harrison, M. R., Kaban, L. B. An in-utero model of craniosynostosis. J. Craniofac. Surg. 3 (1992) 70
- Fairley, J., Mühlbauer, W., and Anderl, H. Continuous midfacial distraction. In the proceedings of the sixth International congress of the international society of craniofacial surgery, Marchac, D. (Ed.), Monduzzi Editore, Bologna, 1995
- Fearon, J. A., and Whitaker, L. A. Complications with facial advancement: A comparison between the Le Fort III and monobloc advancements. Plast. Reconstr. Surg. 91 (1993) 990
- Feingold, M., O'Connor, J. F., Berkman, M., Darling, D. B. Kleeblattschädel syndrome. Am. J. Dis. Child 118 (1969) 589-594
- Foley, W. M., and Kovich, V. G. The effects of mechanical immobilization on sutural development in the growing rabbit. J. Neurosurg. 14 (1957) 584
- Francis, P. M., Beals, S., Rekate, H. L., Pittman, H. W., Manwaring, K., Reiff, J. Chronic tonsillar herniation and Crouzon's syndrome. Pediatr. Neurosurg. 18 (1992) 202-206
- Frank, L. M., Mason, M. A., Magee, W. P., Penix, J. O., Schechter, G. L. The Kleeblattschädel deformity: Neurologic outcome with early treatment. Pediatr. Neurol. 1 (1985)379-391
- Gathmann, A., Meyer, R. D. „Der Kleeblattschädel Ein Beitrag zur Morphogenese", Springer-Verlag, Berlin, 1977
- Gillies, H., and Harrison, S. H. Operative correction by osteotomy of recessed malar maxillary compound in a case of oxycephaly. Br. J. Plast. Surg. 3 (1951) 123
- Goh, K. Y. C., Ahuja, A., Fok, T. F., Poon, W. S. Cloverleaf skull-when should one operate. Singapore Med. J. 38 (1997) 217-220
- Golabi, M., Edwards, M. S., Ousterhout, D. K. Craniosynostosis and hydrocephalus. Neurosurgery 21 (1987) 66
- Gosain, A. K., Moore, F. O., Hemmy, D. C. The Kleeblattschadel anomaly in Apert syndrome: intracranial anatomy, surgical correction, and subsequent cranial vault development. Plast. Reconstr. Surg. 100 (1997) 1796-802
- Greene, H. S. M. Oxycephaly and allied conditions in man and in the rabbit. J. Exp. Med. 57 (1933) 967-976
- Hardesty, R. A., Marsh, J.L., Vannier, M. W. Unicoronal synostosis: A surgical intervention. Neurosurg. Clin. North. Am. 2 (1991) 641-653

- Heeckt, P., Mühlbauer, W., Anderl, H., Schmidt, A., Höpner, F. Early radical treatment of pancraniofacial synostosis. Ann. Plast. Surg. 30 (1993) 312-319
- Hockley, A. D. Craniosynostosis. Lancet 342 (1993) 189-190
- Holtermüller, K., Wiedemann, H.-R. Kleeblattschädel-Syndrom. Med. Monatsschr. 14 (1960) 439-446
- Hubli, E. H., Salyer, K. E., Gendler, E. Demineralised bone bandeau in a patient with Kleeblattschädel skull deformity. Ann. Plast. Surg. 41 (1998) 81-85
- Ilizarov, G. A. The principles of the Ilizarov method. Bull. Hosp. Jt. Dis. Orthop. Inst. 48 (1998)
- Ilizarov, G.A. “The Transosseous Osteosynthesis: Theoretical and Clinical Aspects of the Regeneration and Growth of Tissue” Springer-Verlag, New York, 1992
- Jabs, E. W., Li, X., Scott, A. F., Meyer, G., Chen, W., Eccles, M., Mao, J.I., Charnes, L. R., Jackson, C. E., Jaye, M. Jackson Weiss and Crouzon syndromes are allelic with mutations in fibroblast growth factor 2. Nature Genet. 8 (1994) 275-279
- Kaban, L. B., Conover, M., and Mulliken, J. B. Mid-face position after Le Fort III advancement: A long-term follow-up study. Cleft Palate J. 123 (1986) 75
- Klaauw, C. J. van der. Cerebral skull and facial skull. Arch. Neerl. Zool. 7 (1946) 16
- Kroczek, R. A., Mühlbauer, W., Zimmermann, I. Cloverleaf skull associated with Pfeiffer syndrome: pathology and management. Eur. J. Pediatr. 145 (1986) 442-445
- Laurent, J. P., Cheek, W. R. Craniosynostosis. In “Pediatric Neurosurgery”, Venes, J. L., McLaurin, R. L., Schut, L., Epstein, F. (Ed.), Saunders, Philadelphia, 1989, first edition, 107-119
- Leiber, B., Olbrich, G. „Wörterbuch der klinischen Syndrome“ Urban u. Schwarzenberg, München:, 1959
- Liebaldt, G. Das Kleeblattschädel-Syndrom als Beitrag zur formalen Genese der Entwicklungsstörungen des Schädeldaches. Ergeb. Allg. Path. Anat. 45 (1964) 23-38
- Liebaldt, G. „Zur Patho-Anatomie des Kleeblattschädel-Syndroms. Dysostosen, generalisierte und lokalisierte Knochenentwicklungsstörungen“ G Fischer Verlag, Stuttgart, 1966, 102-103
- Lodge, M. L., Moore, M. H., Haneih, A., Trott, J. A., David, D. J. The cloverleaf skull anomaly: Managing extreme cranio-orbitofaciostenosis. Plast. Reconstr. Surg. 91 (1993) 1-9

- Loschge, F. H. „Beschreibungen einiger Missbildungen an dem Kopfe und den Zungenbeinen eines Kindes. Beiträge für die Zergliederungskunst“, Fig.I-VII, Leipzig, 1800, 313-337
- Loschge, F. H. “De sceleto hominis simmetrico”, 65, Erlangen, 1795.
- Marchac, D. Radical forehead remodelling for craniostenosis. Plast. Reconstr. Surg. 61 (1978) 823
- Maroteaux, P., Lamy, M., Robert, J. M. Le nanisme thanatophore. Presse Medicale 75 (1967) 2519
- Marsh, J. L., and Vannier, M. W. Cranial base changes following surgical treatment of craniosynostosis. Cleft. Palate J. 23 (1986) 9
- McCarthy, J. G., Schreiber, J., Karp, N., Thome, C. H., Grayson, B. H. Lengthening the human mandible by gradual distraction. Plast. Reconstr. Surg. 89 (1992) 1-8
- McCarthy, J. G. Craniosynostosis. In “Plastic Surgery”, McCarthy, J. G. (Ed.), Saunders Publishers, Philadelphia, 1990
- Meyer, R. Hydrocephalus chondrodystrophicus mit Bemerkungen über den „Perioststreifen“ bei Chondrodystrophie. Virchows Arch. Path. Anat. 253 (1924) 766-774
- Molina, F., Monasterio, F. O. Mandibular elongation and remodelling by distraction: a farewell to major osteotomies. Plast. Reconstr. Surg. 96 (1992) 825-840
- Montaut, J., Stricker, M. Dysmorpheies Craniofaciales: Les synostoses Prematuries. In (Craniostenoses et Faciostenoses), Masson, Paris, 1977
- Mooney, M. P., Losken, H. W., Siegel, M. I., Lalikos, A., Smith T. P., Burrows, A. M. Development of a strain of rabbits with congenital simple, nonsyndromic coronal suture synostosis: Part 1. Breeding demographics. Inheritance pattern and craniofacial anomalies. Cleft Palate Craniofac. J. 31 (1994) 1-7
- Mooney, M. P., Losken, H. W., Siegel, M. I., Lalikos, A., Burrows, A. M., Smith, T. P. Development of a strain of rabbits with congenital simple, nonsyndromic coronal suture synostosis: Part 2. Somatic and craniofacial growth. Cleft Palate Craniofac. J. 31 (1994) 8-16
- Mooney, M. P., Losken, H. W., Tschakaloff, A., Siegel, M. I., Losken, A., Lalikos, J. F. Congenital bilateral coronal suture synostosis in a rabbit and comparisons with experimental models. Cleft Palate Craniofac. J. 30 (1993) 121-128
- Moss, M. L. Functional anatomy of cranial synostosis. Childs Brain 1 (1975) 22-33

- Moss, M. L., Salentijn, L. The primary role of functional matrices in facial growth. Am. J. Orthod. 55 (1969) 566
- Moss, M. L. The pathogenesis of premature cranial synostosis in man. Acta. Anat. 37 (1959) 351
- Muenke, M., Schell, U. A common mutation in the fibroblast growth factor receptor 1 gene in Pfeiffer syndrome. Nature Genet. 8 (1994) 269-274
- Mühlbauer, W., Anderl, H., Heeckt, P. Early facial advancement in craniofacial stenosis. In “Craniofacial surgery” Marchac, D., (Ed.), Springer Verlag, Berlin, 1987, 123-127
- Mühlbauer, W., Anderl, H., Heeckt, P., Schmidt, A., Ramatschi P. Early operation in craniofacial dysostosis. World J. Surg. 13 (1989) 366-372
- Mühlbauer, W., Anderl, H., Ramatschi, P., Schmidt, A. Radical treatment of craniofacial anomalies in infancy and the use of miniplates in craniofacial surgery. Clin. Plast. Surg. 14 (1987) 101
- Mühlbauer, W., Anderl, H., Schmidt, A., Ramatschi, P. Asymmetrical cranio orbital facial stenosis. Ann. Plast. Surg. 26 (1987) 45
- Mühlbauer, W. Distraction osteogenesis in the treatment of Apert’s syndrome in infancy. In “Transactions of the scientific meeting of the International Plastic, Reconstructive, and Aesthetic Surgery Society, Yokohama, Japan”, Harii, K. (Ed.), Kugler Publications, Amsterdam:, 1995
- Muller, P. J., Hoffman, H. J. Cloverleaf skull syndrome. J. Neurosurg. 43 (1975) 86-91
- Oi, S., Bapapar, B., Klekamp, J., Samii, M. Prerequisites for fetal neurosurgery: management of central nervous system anomalies toward the 21st century. Critical Review in Neurosurgery 28 (1999) 252
- Opperman, L. A., Sweeney, T. M., Redmon, J., Persing, J. A., Ogle, R. C. Tissue interactions with dura mater inhibit osseous obliteration of developing cranial sutures. Dev. Dynamics 198 (1993) 312
- Ortiz-Monasterio, F., Fuente del Campo, A., and Carillo, A. Advancements of the orbits and the mid-face in one piece, combined with frontal repositioning for the correction of Crouzon’s deformities. Plast. Reconstr. Surg. 61 (1968) 507
- Otto, A. W. Lehrbuch der pathologischen des menschen und der Thiere. Rucker Verlag, Berlin, 1830

- Partington, M. W., Gonzales-Crussi, M. W., Khakee, F., Wollin, S. G., Wollin, D. G. Cloverleaf skull and thanatophoric dwarfism. Report of four cases, two in the same sib ship. Arch. Dis. Childh. 46 (1971) 656-664
- Persing, J. A., Jane, J. A., Edgerton, M. T. Surgical treatment of craniosynostosis. In: “Scientific Foundation and Surgical Treatment of Craniosynostosis” Persing, J. A., Jane, J. A., Edgerton, M. T. (Ed.) Williams & Wilkins, Baltimore, 1989
- Persing, J. A., Babler, W. J., Jane, J. A., Duckworth, P. F. Experimental unilateral coronal synostosis in rabbits. Plast. Reconstr. Surg. 77 (1986) 369
- Persson, K. M., Roy, W. A., Persing, J. A., Rodeheaver, G. T., Winn, H. R. Craniofacial growth following experimental craniosynostosis and craniectomy in rabbits. J. Neurosurg. 50 (1979) 187
- Posnick, J. C., Lin, K. Y., Jhawar, B. J., Armstrong, D. Crouzon syndrome: Quantitative assessment of presenting deformity and surgical results based on CT scans. Plast. Reconstr. Surg. 92 (1993) 1027
- Preston, C. B., Losken, H. W., Evans, W. G. Restitution of facial form in a patient with hemifacial microsomia. The Angle Orthodontist 55 (1985) 197-205
- Reardon, W., Winter, R. M., Rutland, P., Pulleyn, L. J., Jones, B. M., Malcolms, S. mutations in the fibroblast growth factor receptor 2 gene cause crouzon syndrome. Nature Genet. 8 (1994) 98-103
- Renier, D., Brunet, L., Marchac, D. IQ and craniostenosis: Evolution in treated and untreated cases. In “Craniofacial Surgery”, Marchac, D. (Ed.) Springer-Verlag, Berlin, 1987, 114
- Renier, D. Intracranial Pressure in Craniosynostosis: Pre- and Postoperative Recordings—Correlation with Functional Results. In “Scientific Foundations and Surgical Treatment of Craniosynostosis” .J. A. Persing, M. T. Edgerton, and J. A. Jane (Ed.), Williams & Wilkins, Baltimore, 1989, 263
- Resnick, D. K., Pollack, I. F., Albright, A. L. Surgical management of the cloverleaf skull deformity. Pediatr. Neurosurg. 22 (1995) 29-38
- Rohatgi, M. Cloverleaf skull-a severe form of Crouzon’s syndrome: A new concept in aetiology. Acta Neurochir. 108 (1991) 45-52
- Rudolphi, K. A. Über den Wasserkopf vor der Geburt, nebst allgemeinen Bemerkungen über Missgeburten (gelesen in der Akademie der Wissenschaften am 1. April 1824) Berlin, 1824, 121-130

- Sadove, A. M., Kalsbeck, J. E., Eppley, B. L., Javed, T. Modifications in the surgical correction of trigonocephaly. Plast. Reconstr. Surg. 85 (1990) 853-858, 1990
- Salvo, A. F. In utero diagnosis of Kleeblattschädel. Prenat. Diagn. 1 (1981) 141-145
- Schott. Seltene Schädelmissbildung. Wiener Med. Blätter 4 (1881) 601-606
- Shillito, J. A. Plea for early operation for craniosynostosis. Surg. Neurol. 37 (1992) 182-188
- Sommerring, S. T. „Vom Baue des menschlichen Korpers“ Voss Verlag, Leipzig:, 1839, zweite Auflage
- Stark D. „Embryologie. Ein Lehrbuch auf allgemein biologischer Grundlage“ Thieme, Stuttgart, 1965
- Stewart, R. E., Dixon, G., Cohen, A. The pathogenesis of premature craniosynostosis in acrocephalosyndactyly (Apert’s syndrome). Plast. Reconstr. Surg. 59 (1977) 699
- Sutton, L. N., Suri, P., Adzick, N. S. Fetal Neurosurgery. Neurosurgery 48 (2001) 124
- Tessier, P. Osteotomies totales de la face. Syndrome de Crouzon, syndrome d’Apert: Oxycephalies, scaphocephalies, turricephalies. Ann. Chir. Plast. 12 (1967) 273
- Tessier, P. The definitive plastic surgical treatment of the severe facial deformities of craniofacial dysostosis: Crouzon’s and Apert’s disease. Plast. Reconstr. Surg. 48 (1971) 419
- Theiler, K. Embryonale und postnatale Entwicklung des Schädels. Handbuch der medizinischen Radiologie. Bd.VII/1, 36-42. Springer Verlag, Berlin-Göttingen-Heidelberg, 1963.
- Toth, B. A., Kim, J. W., Chin, M., Cedars, M. Distraction osteogenesis and its application to the midface and bony orbit in craniosynostosis syndromes. J. Craniofac. Surg. 9 (1998) 100-113
- Turner, P. T., Reynolds, A. E. Generous craniectomy for Kleeblattschädel anomaly. Neurosurgery 6 (1980) 555-558
- Venes, J. L. Arnold Chiari malformation in an infant with Kleeblattschädel: an acquired malformation? Neurosurgery 23 (1988) 360-362
- Virchow, R. Ueber den cretinismus, namentlich in Franken. Und ueber pathologische Schadelformen. Verh. Phys. Med. Gesante Wurzburg 2 (1851) 230
- Vrolik, M. Tabulae ad illustrandem embryogenesin hominis et mammalium tam naturalem quam abnormen. Tabula 35, 36. Hydrocephalus internus. Amsterdam: London, 1849

- Watters, E. C., Hiles, D. A., Johnson, B. L. Cloverleaf skull syndrome. Am. J. Ophtalmol. 76 (1973) 716-720
- Whitaker, L. A., Bartlett, S. P., Shut, L., Bruce, D. Craniosynostosis: An analysis of the timing, treatment, and complications in 164 consecutive patients. Plast. Reconstr. Surg. 80 (1987) 195
- Witt, P. D., Hardesty, R.A., Zuppan, C., Rouse, G., Hasso, A. N., Boyne, P. Fetal Kleeblattschädel cranium: morphologic, radiologic, and histologic analysis. Cleft Palate Craniofac. J. 29 (1992) 363
- Zuleta, A., Basauri, L. Cloverleaf skull syndrome. Childs Brain 11 (1984) 418-427

10 Danksagung:

Ich möchte mich ganz besonders bei Herrn Prof. Dr. Wolfgang Mühlbauer für seine Förderung und Unterstützung bei dieser Arbeit bedanken. Prof. Dr. Mühlbauer gehört zu den großen Pionieren der kraniofazialen Chirurgie in Deutschland und hat vor mehr als 25 Jahren mit dieser Arbeit in München begonnen. Dank seiner besonderen Leistung konnte ein Zentrum für kraniofaziale Chirurgie unter Leitung der Plastischen Chirurgie in München entstehen, wo schwerste kraniofaziale Missbildungen behandelt werden können.

Mein besonderer Dank gilt auch meiner Frau für ihre Unterstützung und Geduld während der Fertigstellung dieser Arbeit.

Ich möchte diese Arbeit all den betroffenen Kindern und Familien widmen, die durch angeborene kraniofaziale Missbildungen betroffen sind.

11 Vita: Frank R. Gräwe

Geboren am 14.07.1965 in Diez/Lahn

1984	Abitur an der Tilemannschule in Limburg
1985-1987	Wehrdienst
1988-1993:	Medizinstudium an der Universität von Pretoria, Südafrika: Abschluss: Bachelor of Medicine and Surgery; M.B.Ch.B (Pret) (MD)
1993-1994:	„Housemanship“ in Empangeni / Südafrika am Ngwelezana Hospital
1994:	Approbation als Arzt (Health Professional Council of South Africa, HPCSA)
1995:	Amerikanisches Staatsexamen (ECFMG)
1994-1995:	Assistenzarzt in der Neurochirurgie an der Universität von Stellenbosch in Südafrika (Tygerberg Hospital)
1995-2000:	Weiterbildung zum Facharzt für Plastische Chirurgie an: • Department of Plastic Surgery, University of Stellenbosch / Südafrika, Tygerberg Hospital, Prof. Dr. Benny Zeeman • Department of Plastic & Maxillofacial Surgery, University of Kapstadt / Südafrika, Groote Schuur Hospital, Prof. Dr. Don Hudson
2000:	Facharztanerkennung für Plastische u. Rekonstruktive Chirurgie und Master Degree in Plastic Surgery - M.Med (Plast & Recon) (Stell)
1998-2000:	Nebenberufliche Tätigkeit in eigener Praxis in der Ästhetischen-Plastischen Chirurgie
2000:	Tätigkeit als Facharzt in Plastischer Chirurgie, Tygerberg Hospital

2000-2001:	1. Fellowship bei Dr. Daniel Marchac in Paris: Subspezialisierung in der Kraniofazialen Chirurgie u. Ästhetischen Gesichtschirurgie
	2. Fellowship bei Dr. Francoise Firmin in Paris: Subspezialisierung in Rekonstruktiver u. Ästhetischer Chirurgie, und Ohrmuscheltotalrekonstruktion
2001-2003:	Anstellung als Facharzt am Krankenhaus München Bogenhausen in der Plastischen Chirurgie, Spezialgebiet Kraniofaziale Chirurgie (Chefarzt Prof. Dr. Wolfgang Mühlbauer)
2002:	European Board Exam in Plastic, Reconstructive and Aesthetic Surgery (Europäisches Facharztexamen für Plastische Chirurgie)
2002:	EURAPS/AAPS (fellowship) Reisestipendium der Europäischen Gesellschaft für Plastische Chirurgie in die USA
2003:	Fellowship bei Dr. Kenneth Salyer (2003 President of the International Society of Craniofacial Surgery) am International Craniofacial Institute in Dallas / Texas: Subspezialisierung in Kraniofazialer Chirurgie und Ästhetischer Gesichtschirurgie
2004:	Nostrifizierung in Österreich, Titel: Dr.med.univ. (Universität Innsbruck)
2004:	Niederlassung als Facharzt für Plastische und Ästhetische Chirurgie in München

Mitgliedschaften:

- Ordentliches Mitglied im Verein der Deutschen Plastischen Chirurgen (VDPC)

- Ordentliches Mitglied der Südafrikanischen Gesellschaft für Plastische Chirurgie (APRSSA)

- General Medical Council (GMC, Grossbritannien)

- Health Professional Council of South Africa (HPSCA)

Zahlreiche Teilnahmen und wissenschaftliche Vorträge an nationalen und internationalen Kongressen im Fachgebiet. Mehrere wissenschaftliche Publikationen sowie aktive Teilnahme an der universitären Lehrtätigkeit.