

Giant Malignant Mesenchymoma of the Spermatic Cord with Bidirectional Differentiation

R. Paul^a H. Leyh^a M. Hillemanns^b H. Höfler^b R. Hartung^a

^a Urologische Klinik und Poliklinik und

^b Institut für Allgemeine Pathologie und Pathologische Anatomie, Klinikum rechts der Isar, Technische Universität München

Key Words

Malignant mesenchymoma · Sarcoma · Bidirectional differentiation · Spermatic cord neoplasm

Schlüsselwörter

Malignes Mesenchymom · Sarkom · Bidirektionale Differenzierung · Samenstrangtumor

Summary

Background: Spermatic cord neoplasms are a rare tumor entity and, moreover, of benign behavior. Malignant tumors of the spermatic cord are mostly of mesenchymal origin. We present the unusual case of a giant malignant mesenchymoma of the spermatic cord with bidirectional differentiation into a liposarcoma and a leiomyosarcoma. **Case Report:** A 84-year-old male patient presented with a scrotal mass on the left side which was observed growing since 1 year and misdiagnosed as scrotal hernia or testicular hydrocele. Ultrasound and computed tomography demonstrated a solid tumor suggesting a spermatic cord tumor. The patient underwent hemiscrotectomy, and the histological examination of the 2,500-gram specimen revealed a malignant mesenchymoma originating from the spermatic cord with two distinct histopathological compartments of liposarcoma and leiomyosarcoma. Because an adjuvant therapy protocol is of questionable effect and because of the patient's age no further therapy was applied. The patient was closely followed and is now, 5 years after surgery, still free of disease. **Conclusion:** Even in older patients, scrotal masses should be considered malignant tumors as long as no benign diagnosis has been proven. Although malignant mesenchymomas are rare tumors with poor prognosis, in selected cases even large tumor masses, as presented, can be cured by surgery.

Zusammenfassung

Hintergrund: Samenstrangtumoren sind selten, überwiegend benignen Ursprungs und stammen meist aus mesenchyemalem Gewebe. Ein ungewöhnlicher Fall eines riesigen malignen Mesenchymoms des Samenstranges mit bidirektionaler Differenzierung in ein Liposarkom und ein Leiomyosarkom wird vorgestellt. **Kasuistik:** Wir berichten über den Fall eines 84-jährigen Patienten mit einer zunehmenden Schwellung im linken Skrotum, die seit einem Jahr im Wachstum beobachtet und als Skrotalhernie bzw. Hydrozele testis mißdeutet wurde. Ultraschalluntersuchung und Computertomographie zeigten einen soliden Tumor mit der Verdachtsdiagnose eines Samenstrangtumors. Der Patient unterzog sich einer Hemiskrotektomie. Die histologische Untersuchung des 2500 g schweren Präparates ergab als Befund ein malignes Mesenchymom, welches aus dem Samenstrang entstammte und zwei unterschiedliche Kompartimente, ein Liposarkom und ein Leiomyosarkom, aufwies. Aufgrund des Alters des Patienten und da eine adjuvante Therapie nur fraglichen Erfolg hat, wurde keine weitere Therapie durchgeführt. Der Patient wurde in kurzen Abständen kontrolliert und ist 5 Jahre nach der Operation tumorfrei. **Schlußfolgerung:** Skrotalschwellungen sollten auch bei älteren Patienten als krebverdächtig angesehen werden, solange die gutartige Diagnose der Schwellung nicht bewiesen ist. Obwohl maligne Mesenchymome seltene Tumoren mit insgesamt schlechter Prognose sind, kann im Einzelfall, wie hier berichtet, eine chirurgische Sanierung auch bei großen Tumoren erreicht werden.

Case Report

A 84-year-old man presented with giant scrotal mass on the left side which was observed growing over 1 year (fig. 1A) to our department. The patient was referred due to the misleading diagnosis of an increasing testicular hydrocele or scrotal hernia. Ultrasound revealed a 27×17×11-cm solid tumor of the spermatic cord. Staging computed tomography (CT) confirmed the tumor (fig. 1B) and demonstrated no other tumor deposits. The patient underwent a left hemiscrotectomy and reconstruction of the scrotum and penis (fig. 1C). The histological examination revealed a tumor weighing 2,500 g, demonstrating features of a malignant mesenchymoma (fig. 1D) with two different mesenchymal compartments, a liposarcoma of sclerosing type (90% of the tumor mass) and a leiomyosarcoma (10%), confirmed by positive immunohistochemistry for vimentin of the whole tumor specimen as well as sm-actin and desmin for the leiomyosarcomatous compartment. On the other hand, negative immunohistochemistry was noted for cytokeratin, lysozyme and S-100. There was only a low mitotic rate noted (1–2 mitotic cells per 40 microscopic views), and atypical mitosis was found. No tumor necrosis was noted, suggesting a slow tumor progression rate. The tumor specimen showed negative margins, although because of the multinodularity of the tumor the pathologist could not prove a complete resection. The patient showed primary wound healing and could be discharged on day 10. The patient did not receive adjuvant therapy because of age, tumor entity and complete resection, but was closely followed. The patient was last seen 5 years after surgery, and no evidence of recurrence or metastasis was found.

Discussion

Mesenchymal tumors demonstrating combined features of adipose and smooth muscle differentiation are very rare [1]. The majority of soft tissue tumors with the combination described was reported as benign lesions. Only case reports of malignant, multidifferentiated mesenchymomas were published up to now [1, 2]. Although malignant mesenchymomas are very rare tumor entities, case reports demonstrated this type of tumor in a variety of tissues including kidney [3], pleura [4], mediastinum [5], brain [6], heart [7], liver [8], and others.

Also spermatic cord tumors are very rare tumors and mostly of benign origin [9]. Lioe and Biggart [9] noted only 22% malignant tumors nearly 50% of which were metastases, the other 50% presented as primary tumors of the spermatic cord mostly originating from mesenchymal tissue. Of these primary mesenchymal tumors, there are case reports of a liposarcoma [10], leiomyosarcoma [11], lymphomas [12, 13], malignant fibrous histiocytoma [14], and others. Malignant mesenchymomas of the spermatic cord have been reported before [1, 15–17]; to our knowledge, we present the largest malignant mesenchymoma and the second-largest tumor of the spermatic cord ever reported in the literature [14]. The tumor specimen weighed a total of 2,500 g, and hemiscrotectomy was necessary to perform a complete resection. Reconstruction of the scrotum and penis was performed to obtain a good cosmetic result (fig. 1C). Staging examination with CT scans of the abdomen, pelvis and thorax did not show organ metastases nor lymph node enlargement. There is no adjuvant treatment protocol established because these tumors are rare, therefore the benefit of additional radiotherapy or chemotherapy remains unknown [13]. There are reports [18] that adjuvant radiation therapy may reduce the incidence of local recurrence but does not influence overall survival, although that study was biased due to different follow-up times and staging examinations. The same result was reported from the European Organization for Research and Treatment of Cancer Soft Tissue and Bone Sarcoma Group for adjuvant chemotherapy [19]. They reported a local recurrence rate reduced from 31 to 17%, but similar overall survival rates with and without adjuvant chemotherapy (56 vs 63%). Glenn et al. [20] reported in 1985 a tendency towards survival advantage for the group with adjuvant chemotherapy in patients with soft-tissue sarcomas, but noted a significant rate of toxicity, especially doxorubicine-induced cardiomyopathy. Also, only little is known about the prognosis of these tumor entities, but MSKCC sarcoma staging system, which is based on grade, size, depth and presence or absence of metastases,

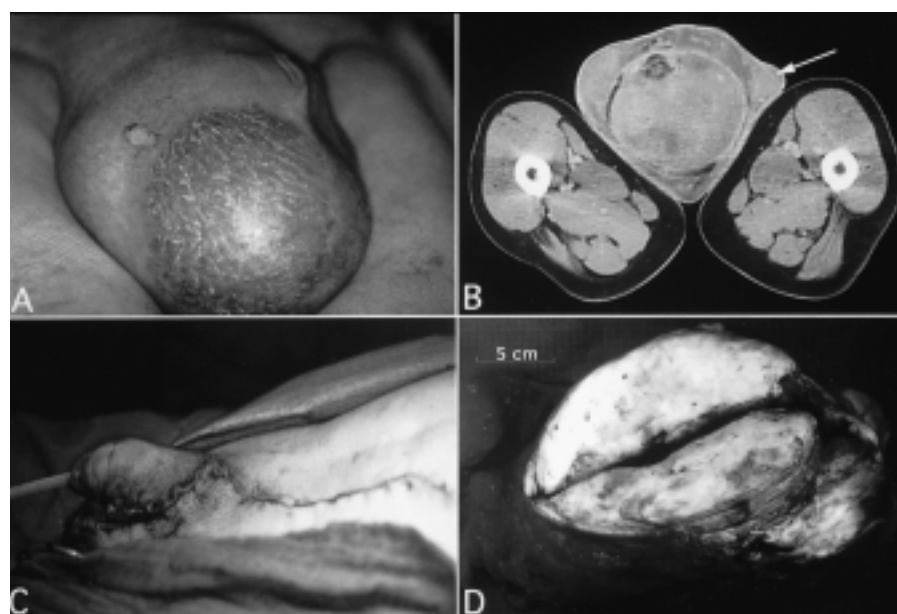


Fig. 1. **A** Giant malignant mesenchymoma of the spermatic cord preoperative situs of massive enlarged left scrotum. **B** CT scan of the scrotum demonstrating a 27×17×11 cm large inhomogeneous, solid mass in the left scrotum with intact left testicle (arrow). **C** Plastic reconstruction of the left scrotum and penis after hemiscrotectomy and tumor resection. **D** Surgical tumor specimen of a multinodulated mass with yellowish surface.

seems to apply also in urological sarcomas [21]. Especially malignant mesenchymomas are a particularly aggressive type of sarcoma, and late tumor recurrence up to 9 years after diagnosis and resection has been reported [23]. Because of this uncertain effectiveness of adjuvant therapy, the high toxicity rate, and the patient's age we decided to follow him closely and to refrain from applying adjuvant chemotherapy or radiotherapy.

Conclusion

Although malignant tumors of the scrotum in elderly patients are a rare feature painless swelling of the scrotum even in these patients should be considered a malignant disease unless the benign diagnosis of the swelling is proven. Only early surgical intervention may be curative in the case of mesenchymal tumors of the spermatic cord. Even if the reported case of a giant malignant mesenchymoma, which was observed growing over 1 year, seems to have a favorable outcome for this patient, this case report may be an exception of a tumor entity with poor prognosis.

References

- 1 Suster S, Wong TY, Moran CA: Sarcomas with combined features of liposarcoma and leiomyosarcoma. *Am J Surg Pathol* 1993;17:905-911.
- 2 Nash A, Stout AP: Malignant mesenchymoma in children. *Cancer* 1961;14:524-533.
- 3 Quinn CM, Day DW, Waxman J, Krausz T: Malignant mesenchymoma of the kidney. *Histopathology* 1993;23:86-88.
- 4 Sheffield M, Rao PR: Malignant mesenchymoma of the pleura. *South Med J* 1996;89:526-528.
- 5 al-Kana R, Rangwala AF, Sills C, Rienzo A: Case report: Malignant mesenchymoma of the mediastinum. *N J Med* 1992;89:851-855.
- 6 Fandino J, Alba J, Botana C, Gomez-Bueno J: Malignant mesenchymoma of the brain. A case report. *Neurochirurgie* 1992;38:98-101.
- 7 Mc Kenney PA, Moroz K, Haudenschild CC, Shemin RJ, Davidoff R: Malignant mesenchymoma as a primary cardiac tumor. *Am Heart J* 1992;123:1071-1075.
- 8 Flemming P, Lang H, Georgii A: Mesenchymal tumors of the liver: Their frequency and histopathological diagnostic problems in surgical interventions. *Verh Dtsch Ges Pathol* 1995;79:116-119.
- 9 Lioe TF, Biggart JD: Tumours of the spermatic cord and paratesticular tissue. A clinicopathologic study. *Br J Urol* 1993;71:600-606.
- 10 Farhat F, Kattan J, Culine S, Theodore C, Terrier-Lacombe MJ, Genin J, Mounedji-Boudiaf L, Bekradda M, Droz JP: Liposarcoma of the spermatic cord: Apropos of a case with review of the literature. *Bull Cancer* 1994;81:223-225.
- 11 Bodo G, Casetta G, Ghabin H, Vottero M, Gamba P: Leiomyosarcoma of the spermatic cord. Case report and revision of the literature. *Minerva Urol Nefrol* 1994;46:179-181.
- 12 Moller MB: Non-Hodgkin's lymphoma of the spermatic cord. *Acta Haematol* 1994;91:70-72.
- 13 Ferry JA, Harris NL, Young RH, Coen J, Zietman A, Scully RE: Malignant lymphoma of the testis, epididymis and spermatic cord. A clinicopathological study of 69 cases with immunophenotypic analysis. *Am J Surg Pathol* 1994;18:376-390.
- 14 Staiman VR, O'Toole KM, Rubin MA, Lowe FC: Giant malignant fibrous histiocytoma of the testis/spermatic cord: Psychologic and possible etiologic complications of unethical Nazi medical experimentation. *Urology* 1996;48:939-943.
- 15 Sano M, Takagi Y, Kimura M, Akagashi K, Hisasue S, Adachi H, Wakabayashi J: Malignant mesenchymoma in the scrotum. A case report. *Nippon Hinyokika Gakkai Zasshi* 1998;89:903-906.
- 16 McCluggage WG, Lioe TF, Caughley LM: Malignant mesenchymoma of the spermatic cord. *Histopathology* 1994;24:493-495.
- 17 Fujita T, Akino H, Suzuki Y, Isomatsu Y, Okada K: Malignant mesenchymoma of the spermatic cord. A case report. *Hinyokika Kyo* 1994;40:165-168.
- 18 Fagundes MA, Zietman AL, Althausen AF, Coen JJ, Shipley WU: The management of spermatic cord sarcomas. *Cancer* 1996;77:1873-1876.
- 19 Bramwell V, Rouesse J, Steward W, Santoro A, Schraffordt-Koops H, Buesa J, Ruka W, Priario J, Wagener T, Burgers M, Van Unnik J, Contesso G, Thomas D, van Glabbeke M, Markham D, Pinedo H: Adjuvant CYVADIC chemotherapy for adult soft tissue sarcoma - reduced local recurrence but no improvement in survival: A study of the European Organization for Research and Treatment of Cancer Soft Tissue and Bone Sarcoma Group. *J Clin Oncol* 1994;12:1137-1149.
- 20 Glenn J, Kinsella T, Glatstein E, Tepper J, Baker A, Sugarbaker P, Sindelar W, Roth J, Brennan M, Costa J, Seipp C, Wesley R, Young RC, Rosenberg SA: A randomized, prospective trial of adjuvant chemotherapy in adults with soft tissue sarcomas of the head and neck, breast, and trunk. *Cancer* 1985;55:1206-1214.
- 21 Russo P, Brady MS, Conlon K, Hajdu SI, Fair WR, Herr HW, Brennan MF: Adult urological sarcoma. *J Urol* 1992;147:1032-1036.
- 22 Brady MS, Perino G, Tallini G, Russo P, Woodruff JM: Malignant mesenchymoma. *Cancer* 1996;77:467-473.
- 23 Poilleux J, Premont M, Forest M, Duthieuw B: Mesenchymatous tumor of the spermatic cord with late recurrence in the retroperitoneal space. Apropos of a case. *Chirurgie* 1989;115:577-580.