

# Vascular Endothelial Growth Factors, Angiogenesis, and Survival in Human Ileal Enterochromaffin Cell Carcinoids

Sophie Besig<sup>a</sup> Petra Volland<sup>a</sup> Dorothee M. Baur<sup>a</sup> Aurel Perren<sup>b</sup>  
Christian Prinz<sup>a</sup>

<sup>a</sup>2nd Medical Department, and <sup>b</sup>Institute of Pathology, Technical University of Munich, Munich, Germany

## Key Words

Enterochromaffin cell · Carcinoid · Vascular endothelial growth factor · Angiogenesis

## Abstract

**Background and Aims:** Well-differentiated neuro-endocrine ileal carcinoids are composed of serotonin-producing enterochromaffin (EC) cells. Life expectancy is determined by metastatic spread to the liver because medical treatment options are still very limited. Selective inhibition of angiogenesis or lymphangiogenesis might prevent tumour growth and metastatic spread. We examined the role of the vascular endothelial growth factors (VEGFs) A, B, C, D, and their receptors (VEGFRs) 1, 2, 3 in angiogenesis and lymphangiogenesis of ileal EC cell carcinoids with and without liver metastases. **Methods:** The expression of various VEGFs and VEGFRs was determined by quantitative real-time RT-PCR in healthy mucosa, primary tumour, lymph node metastases and liver metastases of 25 patients with ileal EC cell carcinoids. Microvessel density (MVD) was determined by CD-31 staining in primary tumours and lymphatic vessel density (LVD) by LYVE-1 staining. VEGF expression levels, MVD, LVD, and patients' survival time were correlated using logistic regression and Kaplan-Meier survival analysis. **Results:** VEGF-A was highly expressed with no difference between normal

mucosa and tumours. VEGF-B and -D as well as VEGFR-1 and -2 expression levels were significantly increased in the tumours when compared to normal mucosa. Patients with liver metastasis, however, had a significantly lower expression of the factors A, B, and C and the receptors 2 and 3. MVD in primary tumours positively correlated with the expression of VEGF ligands and their receptors, except for VEGF-D. LVD did not correlate with any VEGF ligand or receptor. Interestingly, low expression levels of VEGF-B were associated with poor survival. **Conclusion:** Patients with more aggressive metastatic spreading had relatively decreased expression levels of VEGF ligands and receptors. Thus, anti-angiogenic therapy may not be a suitable target in metastatic ileal EC cell carcinoids.

Copyright © 2009 S. Karger AG, Basel

## Introduction

Ileal carcinoids are composed of serotonin-producing enterochromaffin (EC) cells and belong to the well-differentiated neuro-endocrine carcinomas of the gut [1]. They represent the vast majority of the neuro-endocrine tumours of the ileum [2]. Life expectancy of patients with this type of neuro-endocrine cancer is determined by metastatic spreading that occurs via lymphatic vessels

into local and retroperitoneal lymph nodes, and via portal vessels to the liver [3, 4]. Targeted disruption of established lymphatic vessels by extended lymphadenectomy improves prognosis of patients with carcinoids and other gastro-intestinal tumours such as gastric cancer [5], but fails to cure carcinoid tumours. Most of these surgical treatments act as tumour and lymph node debulking [6].

Angiogenesis, lymphangiogenesis, and some of their mediators, the family of vascular endothelial growth factors (VEGFs), have been proven to be important factors for metastatic spread and to have a prognostic impact in several solid tumours [7, 8]. VEGF-A, the best-known representative of the family, binds to the vascular endothelial growth factor receptors (VEGFRs) 1 and 2 and via VEGFR-2 strongly induces endothelial cell proliferation mainly of blood vessels [9]. However, the role of VEGF-B and its receptor VEGFR-1 could not be settled finally till now [10]. VEGF-C and VEGF-D, signalling through VEGFR-3 and when proteolytically processed through VEGFR-2, are not only involved in angiogenesis, but also in the development of the lymphatics, as VEGFR-3 is expressed primarily in lymphatic endothelial cells [11, 12].

Strong vascularization seems to be a typical feature of ileal carcinoids [13], so a possible improvement of the treatment of ileal EC cell carcinoids by inhibition of angiogenesis or lymphangiogenesis needs to be further investigated. Previous findings in midgut carcinoids using immunohistochemistry reported high levels of VEGF-A expression [14]. One study described a poor outcome of carcinoids with high VEGF-A expression as well as of carcinoids with high microvessel density (MVD) [15]. Intriguingly, the opposite has been described in pancreatic endocrine tumours, a related tumour entity [16]. Therefore, we aimed to examine the presence and distribution of subtypes of VEGF ligands, VEGFRs, MVD, and lymphatic vessel density (LVD) in ileal EC cell carcinoids in detail. We correlated their presence with the survival of patients. Our studies reveal that ileal EC cell carcinoids express VEGF ligands and receptors partially in large amounts such as VEGF-A and partially in quite low amounts such as VEGFR-3. Apart from VEGF-D, all VEGFs and VEGFRs were associated with blood vessel density, but none of them correlated with LVD. High expression levels of these factors tended to be associated with carcinoids lacking haematogenous spread and there was a tendency for poor prognosis in low-expressing tumours, which was significant for VEGF-B. So we suggest a low outcome of therapies targeting the VEGF family in at least metastasized ileal EC cell carcinoids.

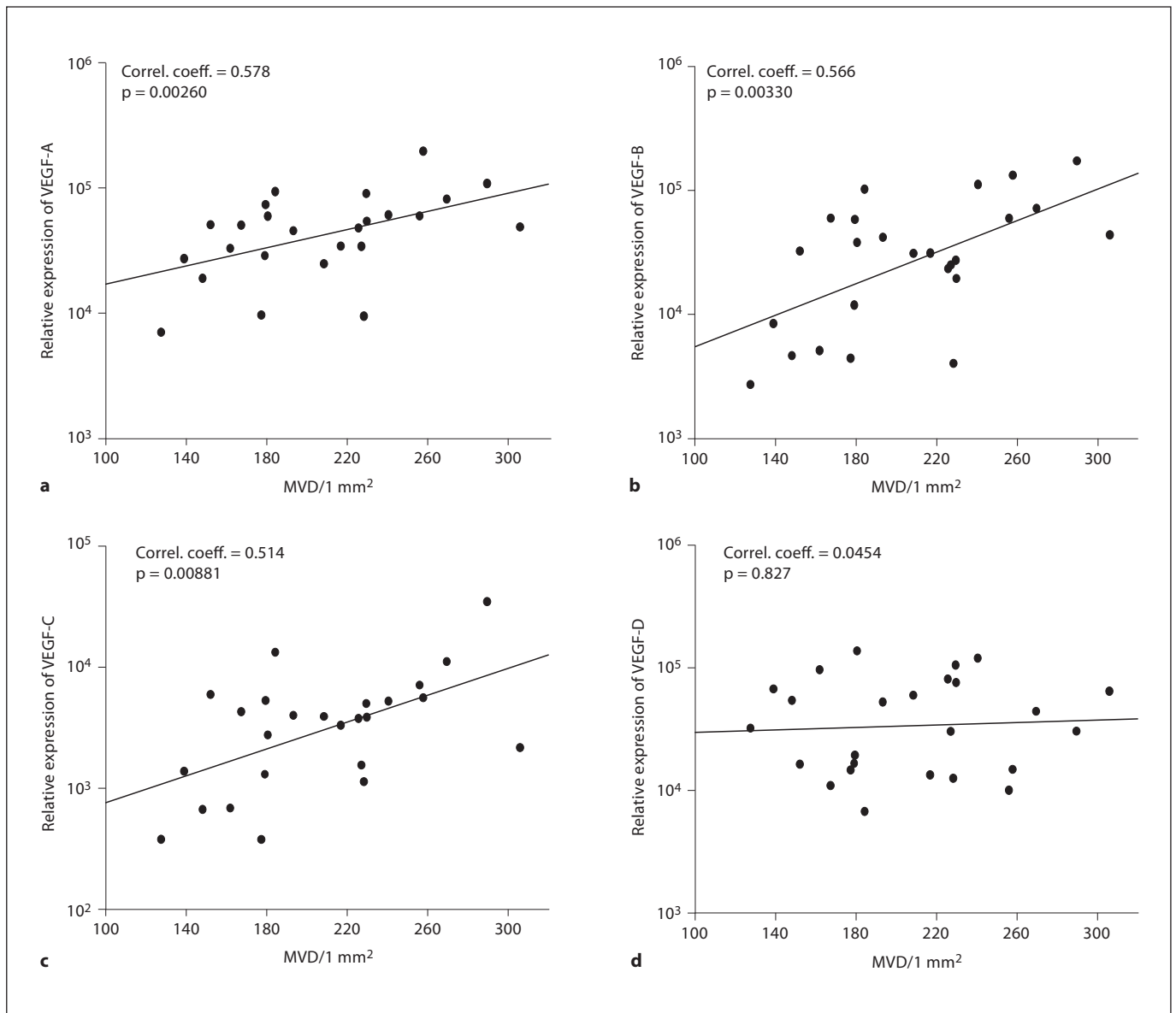
**Table 1.** Patients' (n = 25) characteristics

Sex	
Men	10
Women	15
Age	
Mean age at surgery, years	59 ± 14
Age range, years	35–87
Additional therapy	
Chemotherapy	3
Radiation	0
Dotatoc	2
Somatostatin	7
Interferon	3
None	15
Tumor stage	
pT1	3
pT2	10
pT3	6
pT4	6
Lymph node status	
N1	25
Liver metastasis	
M0	15
M1	10
Disease stage	
Stage IIIB	15
Stage IV	10
Grading	
G1	19
G2	6

## Materials and Methods

### *Patients' Characteristics and Specimens*

The retrospective study included 25 patients with ileal EC cell carcinoids diagnosed and treated between 1992 and 2004 at the Klinikum rechts der Isar, Technical University of Munich, Germany. All patients gave informed consent. Surgical resection specimens were evaluated by two histopathologists. All tumours expressed the vesicular monoamine transporter 1, a marker protein for EC cells. Patients' and tumour characteristics such as sex, age at surgery, additional therapy, TNM status, stage, and grade are summarized in table 1. TNM staging and grading, using the Ki-67 index, was performed following current guidelines for endocrine ileal tumours [17]. As all patients showed lymph node metastases at the time of diagnosis, disease stage was at least IIIB. Ten patients with liver metastases (M1) had disease stage IV. In addition to the primary tumours, tissues for all but 1 lymph node metastasis (n = 24) and for all but 2 liver metastases (n = 8) were available. Follow-up was performed from the date of surgery until April 1, 2007. Dropout was defined as disease-unrelated death (n = 1), alive at the point of evaluation (n = 11) or last secure proof of life before the point of evaluation (n = 5). None of the patients received additional medical treatment before surgery.



**Fig. 1.** Spearman correlation of MVD with expression of VEGF-A (a), VEGF-B (b), VEGF-C (c), VEGF-D (d), VEGFR-1 (e), VEGFR-2 (f), and VEGFR-3 (g) in primary tumours (n = 25). MVD was calculated as mean of CD-31-positive counts per 1 mm<sup>2</sup>. mRNA amounts were determined by quantitative RT-PCR and presented

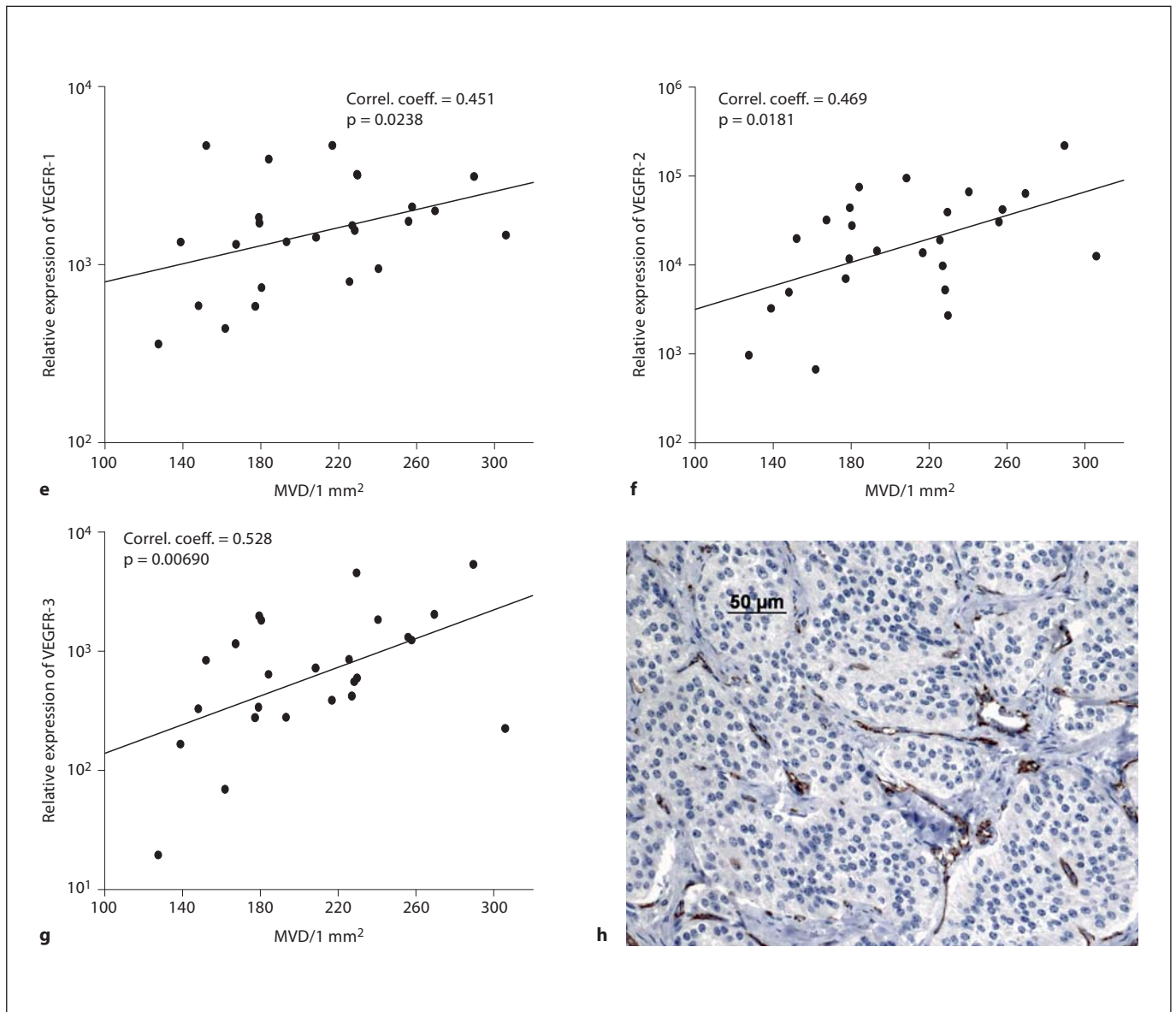
as relative expression normalized to 10<sup>6</sup> GAPDH mRNA copies. Indicated p values and correlation coefficients were calculated by Spearman correlation. **h** Immunohistochemical staining of CD-31-positive vessels (brown) in a representative primary EC cell tumour of the ileum. Magnification ×200.

#### Tissue Preparation

Under RNase-free conditions, formalin-fixed paraffin-embedded tissue samples were sectioned at 10 μm. Sections were dewaxed with xylene, rehydrated and stained with haematoxylin. Whole tissue or separated areas (tumour or normal mucosa) of the section were microdissected to extract total RNA. Tissue amounts per slide lay between 50 and 300 mm<sup>2</sup> in most cases. Small tumour areas were balanced by an increased number of serial sections used.

#### RNA Extraction and cDNA Synthesis by RT-PCR

Scraped-off tissue was immersed in 200 μl lysis buffer (Tris/HCl, pH 8.0; 0.1 mmol/l EDTA, pH 8.0; 2% SDS, pH 7.3) containing 500 μg proteinase K (Applichem, Darmstadt, Germany) and incubated for 16 h at 60°C until completely lysed. To avoid potential problems caused by the use of formalin-fixed paraffin-embedded tissue, we used a classical phenol/chloroform method followed by RNA precipitation that allows recovery of short RNA fragments. Precipitation was performed with an equal volume of



isopropanol, 0.1 volume of 3 mol/l sodium acetate and 20 µg carrier glycogen (Roche, Mannheim, Germany) at -20°C for a minimum of 2 h. Subsequently, the RNA pellet was washed once in 70% ethanol, dried and resuspended in 20 µl of RNAse-free water. The RNA was transcribed into cDNA using Superscript II reverse transcriptase (Invitrogen, Karlsruhe, Germany), according to the manufacturer's instructions. Quality of extracted mRNA was controlled by photometric measurement (BioPhotometer, Eppendorf, Germany). mRNA was accepted as pure with a 260 nm/280 nm quotient higher than 1.8.

#### Quantitative RT-PCR

Quantitative TaqMan® real-time RT-PCR was performed using the ABI PRISM 7700 sequence detection system (Applied Bio-

systems, Foster City, Calif., USA) as described previously [18, 19]. A mastermix was prepared on ice using the Absolute™ QPCR ROX Mix (ABgene, Hamburg, Germany), according to the manufacturer's instructions and mixed with 5 µl of cDNA. Added primers and 5'-FAM/3'-TAMRA-labelled, fluorogenic probes (MWG-BIOTECH AG, Ebersberg, Germany) were designed to lie in different exons to skip intron sequences and prevent amplification of genomic DNA (sequences are listed in table 2). Reaction conditions were 2 min initial incubation at 50°C, followed by 15 min at 95°C to activate the hot-start polymerase and continued with 40 cycles of 95°C for 15 s, 58°C for 20 s, and 72°C for 30 s. All reactions were performed in duplicate. PCR product lengths were 62–146 bp. To equalize for different tissue amounts, mRNA copy numbers of all genes investigated were normalized to 10<sup>6</sup>



GAPDH mRNA copies obtained for each tissue sample. The resulting relative copy numbers for each investigated gene were used for further analysis.

#### *Immunohistochemistry and Determination of MVD*

Immunohistochemical staining for endothelial CD-31 was performed on an automated staining system (Ventana BenchMark; Ventana Medical Systems Tucson, Ariz., USA). Antigen retrieval was performed by heating (CC1 mild, Ventana BenchMark). The primary antibody, a monoclonal mouse anti-human CD-31 clone JC-70-A (Dako ChemMate, Glostrup, Denmark), was incubated at a dilution of 1:30 for 50 min at room temperature. Visualization was performed using the avidin-biotin complex method, which yields a brown staining. Haematoxylin (Applichem GmbH) was used as counterstaining.

For LYVE-1 staining, tissue was unmasked by heating in the microwave oven for 20 min at 360 W in an antigen unmasking solution (Vector, Burlingame, Calif., USA) according to the manufacturer's instructions. Next, endogenous peroxidase activity was quenched by pretreatment with 3% H<sub>2</sub>O<sub>2</sub> for 10 min, followed by incubation with 5% normal rabbit serum (Vector) in an avidin D solution (Vector) for 15 min and with a goat IgG LYVE-1 polyclonal antibody (R&D Systems, Inc., Minneapolis, Minn., USA) diluted 1:150 in 1% normal rabbit serum for 60 min at room temperature. After further incubation with a biotinylated rabbit anti-goat antibody (Vector) 10 µg/ml for 25 min and with an ABC kit (Vector) for 25 min, immunoreaction was visualized by treatment with diaminobenzidine and hydrogen peroxide substrate buffer H<sub>2</sub>O<sub>2</sub> (R&D Systems, Inc.). Haematoxylin (Applichem GmbH) was used as counterstaining.

Microvessels were defined on CD31- or LYVE-1-stained slides using the method specified by Weidner et al. [20] meaning that any brown-stained endothelial cell or cell cluster that was clearly separated from adjacent microvessels, tumour cells and other connective tissue elements was considered a single, countable microvessel. For each tumour, pictures were taken of at least 20 consecutive, unselected fields at a magnification of ×200 (fig. 1h). The number of CD31 or LYVE-1-positive structures in each image was counted. The mean MVD and the mean LVD for each tumour were calculated as the mean of counts per 1 mm<sup>2</sup>.

#### *Statistical Analysis*

Results are presented as box plots or as mean ± SEM. Data were analysed by the Mann-Whitney rank sum test, Kaplan-Meier survival analysis, Spearman correlation and log rank test for survival analysis depending on the data set of concern; p values ≤ 0.05 were considered to be significant.

## **Results**

### *Expression of VEGF Ligands and VEGFRs in Ileal EC Cell Carcinoids*

The expression of VEGF ligands and their receptors was quantitatively determined in healthy mucosa, primary tumour and – where available – in matched lymph node and liver metastases. VEGF-A expression showed no differences between the tissues (fig. 2a), but was ex-

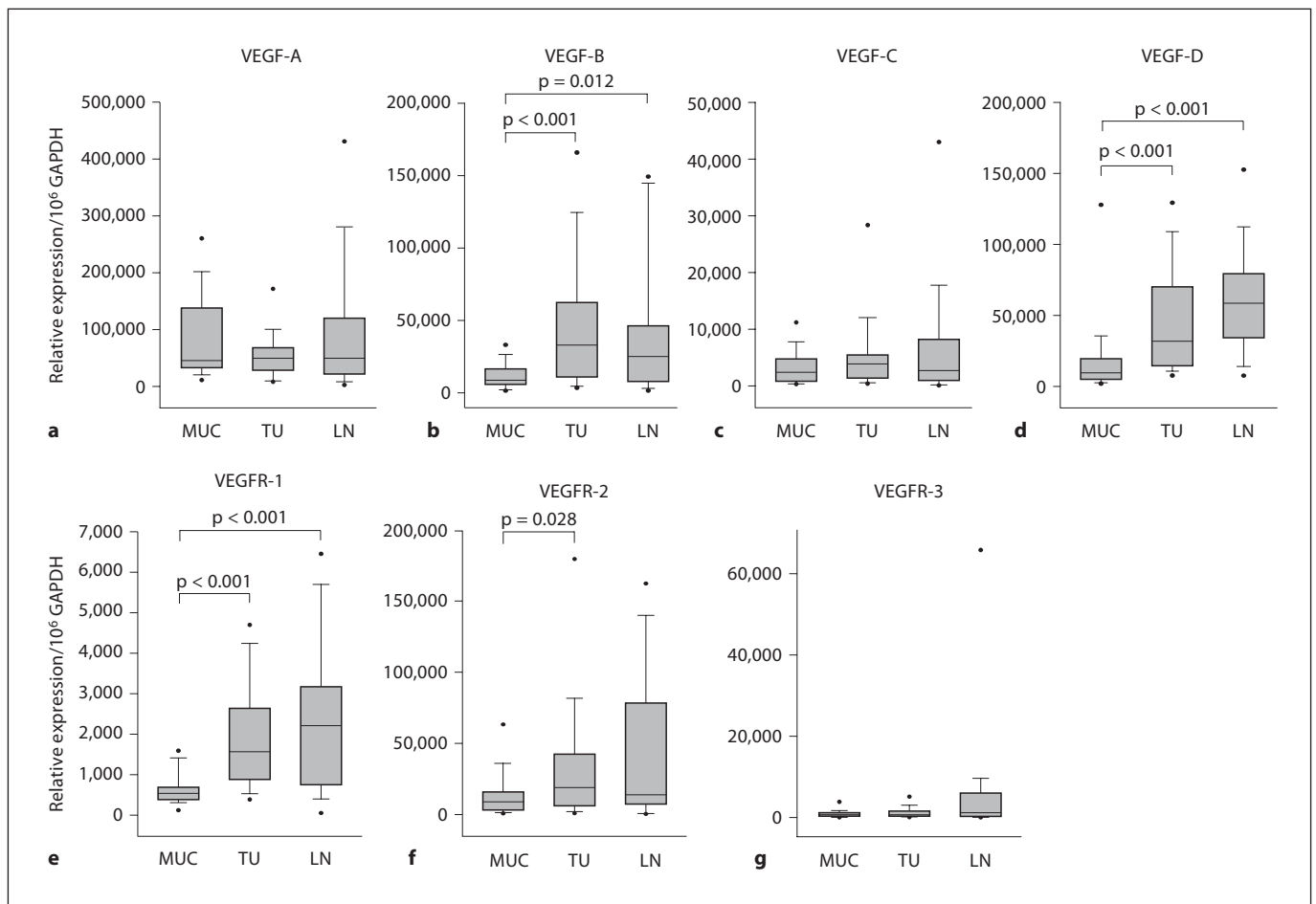
pressed at a higher level as VEGF-B and -D. VEGF-B and -D expression was found to be significantly increased in the primary tumour (p < 0.001) and in lymph node metastases (p = 0.012 for VEGF-B and p < 0.001 for VEGF-D) when compared to normal mucosa (fig. 2b, d). In contrast, the overall low level of VEGF-C expression was only slightly increased in primary tumour tissue and in the lymph node metastasis (fig. 2c).

When analysing the expression patterns of the corresponding receptors, VEGFR-1 was expressed significantly higher, both in primary tumour and lymph node metastases compared to matched normal mucosa samples (fig. 2e, p < 0.001), while VEGFR-2 expression was significantly elevated only in primary tumour tissues (fig. 2f, p = 0.028). VEGFR-2, with a mean relative expression of 33,917/10<sup>6</sup> GAPDH mRNA copies ± 9,104 SEM in primary tumours, was expressed in all about 10- to 20-fold higher than VEGFR-1 with a mean relative expression of 1,865/10<sup>6</sup> GAPDH mRNA copies ± 249 SEM. VEGFR-3 showed (at a rather low average level) an increased expression in lymph node metastases, but this was not statistically significant (fig. 2g). Remarkably, there was an overall absence of significant differences between the expression levels in primary tumours and lymph node metastases for all VEGF ligands and receptors. Similarly, quite homogenous expression levels in primary tumour (n = 10), lymph node metastasis (n = 9), and liver metastasis (n = 8) were also found in the M1 patients' group with liver metastases (fig. 3). Due to the small size of these subgroups, statistical calculations have to be interpreted with caution.

### *Correlation of VEGF and VEGFR Expression with MVD and LVD in Primary EC Cell Carcinoids*

As angiogenesis was the major focus in our study, the density of CD-31-positive microvessels per 1 mm<sup>2</sup> in primary tumours was evaluated as a counterpart of VEGF ligand and receptor expression. Comparison between vessels in the tumour centre and periphery revealed no difference (data not shown). MVD was correlated with expression levels of the VEGF ligands (fig. 1a–d) and receptors (fig. 1e–g). As expected, all correlations were positive and statistically significant (p < 0.01 for VEGF-A, -B, -C and VEGFR-3, p < 0.05 for VEGFR-1 and -2), except for VEGF-D (fig. 1d). Figure 1h illustrates the immunohistochemical staining of CD-31-positive blood vessels in a representative primary tumour.

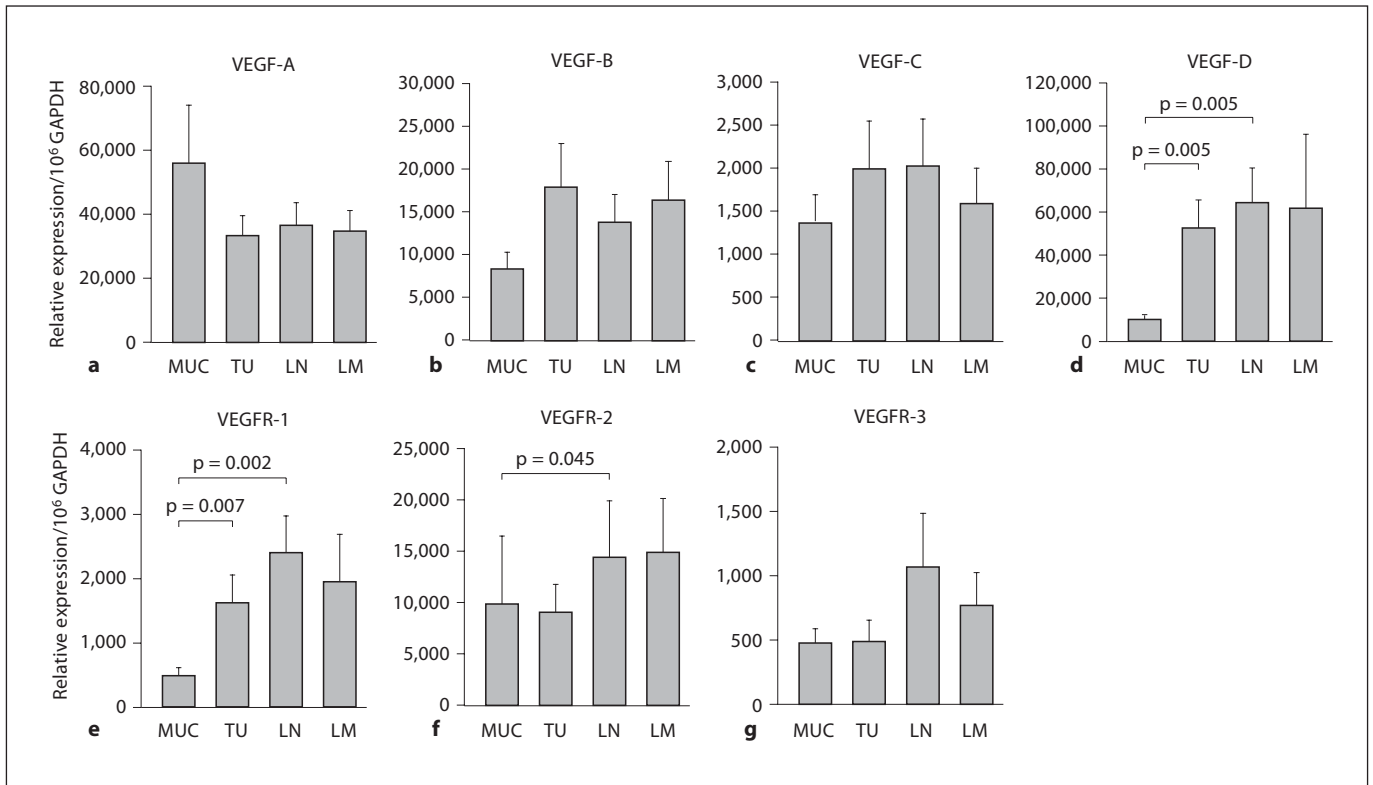
Further, LVD was determined in primary tumours by LYVE-1 staining (fig. 4d), a specific marker for lymphatic endothelial cells [21]. To investigate the relation of



**Fig. 2.** Expression of VEGF-A (a), VEGF-B (b), VEGF-C (c), VEGF-D (d), VEGFR-1 (e), VEGFR-2 (f), and VEGFR-3 (g) in primary EC cell tumours (TU), lymph node metastases (LN) and matched normal mucosa (MUC) of 25 patients. mRNA amounts were determined by quantitative RT-PCR and are presented as relative expression normalized to  $10^6$  GAPDH mRNA copies. Boxes represent the 25th, 50th, and 75th percentiles, whiskers the 10th and 90th percentiles, and filled circles the 5th and 95th percentiles. p values are indicated and were calculated by the Mann-Whitney rank sum test.

**Table 2.** Sequences of primers and probes for quantitative RT-PCR analysis

Gene	Forward primer	Reverse primer	Fluorogenic probe
GAPDH	5'-GGGAAGCTTGTTCATCAATGGA-3'	5'-CGCCCCACTTGATTTTGG-3'	5'-ATCCCATCACCATCTTCCAGGAGCG-3'
VEGF-A	5'-TACCTCCACCATGCCAAGTG-3'	5'-GATGATTCTGCCCTCCTCCTT-3'	5'-TCCCAGGCTGCACCCATGGC-3'
VEGF-B	5'-CCCTGTCTCCCAGCCTGAT-3'	5'-CGCGAGTATACACATCTATCCATGA-3'	5'-CCCTGGCCACCAGAGGAAAGTGG-3'
VEGF-C	5'-AGGAAAGAAGTTCACCACCAA-3'	5'-GCCTTCTGGCGGTTTCGT-3'	5'-CATGCAGCTGTTACAGACGGCCATG-3'
VEGF-D	5'-CTGGAACAGAAGACCACTCTCATC-3'	5'-CTCGCAACGATCTTCGTCAA-3'	5'-CAGGAACCAGCTCTCTGTGGGC-3'
VEGFR-1	5'-TCACTGCCACTCTAATTGTCAATGT-3'	5'-AAACGATGACACGGCCTTTT-3'	5'-AAACCCAGATTTAC-3'
VEGFR-2	5'-CAAGACAGGAAGACCAAGAAAAGAC-3'	5'-GGTGCCACACGCTCTAGGA-3'	5'-TTGCGTGGTCAGGCAGCTCACA-3'
VEGFR-3	5'-GCTGAGACCCGTGGTTCTCT-3'	5'-CTATGCCTGCTCTCTATCTGTCTCAA-3'	5'-ACGACCTACAAAGGCTCTGTGGACAACCA-3'



**Fig. 3.** Expression of VEGF-A (a), VEGF-B (b), VEGF-C (c), VEGF-D (d), VEGFR-1 (e), VEGFR-2 (f), and VEGFR-3 (g) in primary EC cell tumours (TU, n = 10), lymph node metastases (LN, n = 9), liver metastases (LM, n = 8) and matched normal mucosa (MUC, n = 10). mRNA amounts were determined by quantitative

RT-PCR and presented as relative expression normalized to 10<sup>6</sup> GAPDH mRNA copies. Values are means ± SEM. p values are indicated and were calculated by the Mann-Whitney rank sum test.

VEGF ligand and receptor expression to lymphangiogenesis, LVD was compared with the expression levels. Surprisingly, even the lymphangiogenesis-related ligands VEGF-C and -D (fig. 4a, b) and VEGFR-3, mainly expressed on lymphatic endothelium (fig. 4c), did not correlate significantly with the lymphatic vessel count, nor did the other ligands and receptors. Figure 4d demonstrates a primary tumour with LYVE-1-positive lymphatic vessels.

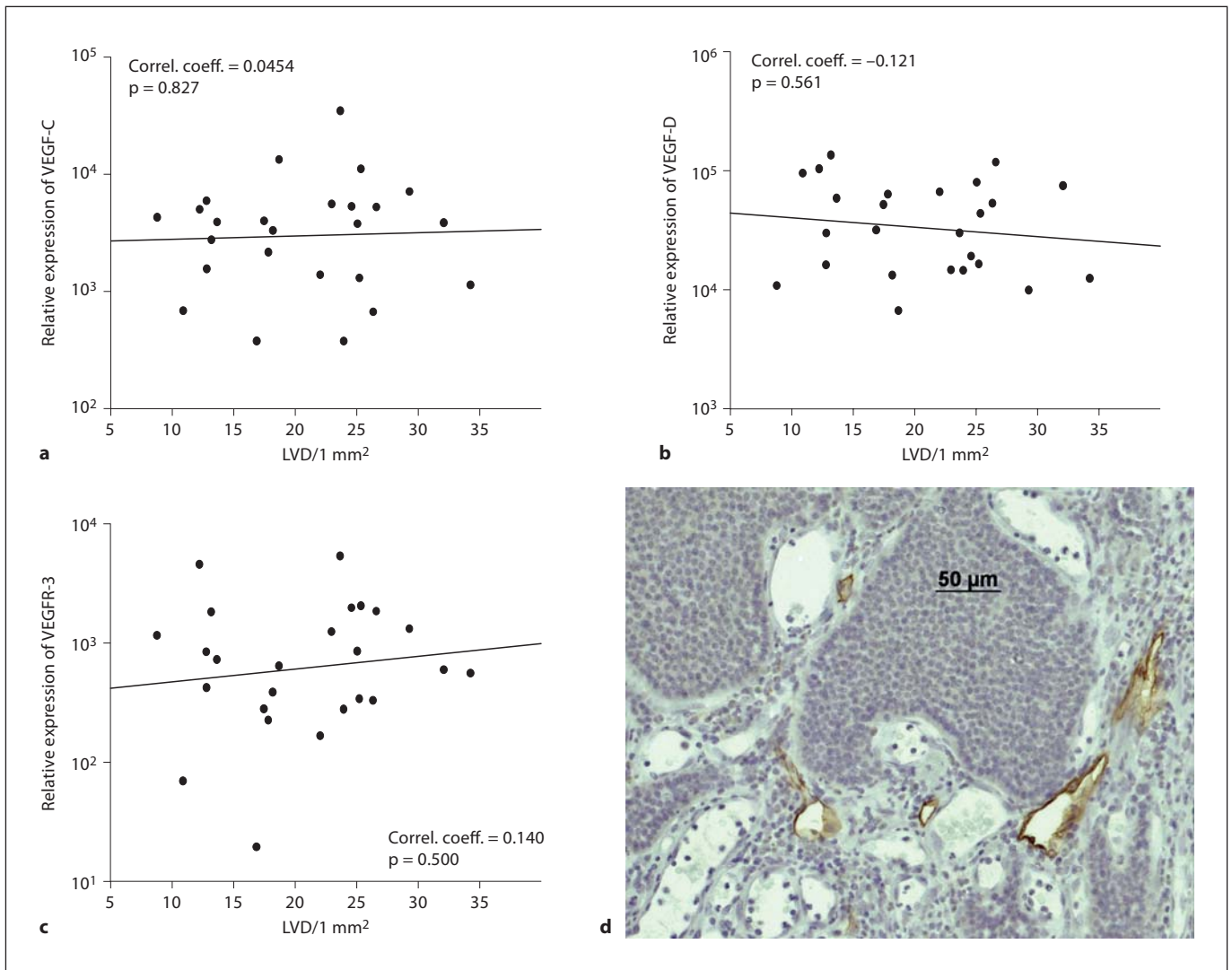
#### Comparison of M0 Status with M1 Status Regarding MVD and Expression of VEGF Ligands and Receptors

The prognosis of midgut carcinoids is largely depending on the presence of metastases in the liver [6]. Therefore, we analysed MVD, LVD and expression patterns of VEGF ligands and their receptors in the primary tumours with special attention to differences between patients without liver metastases (M0) and patients with liver metastases (M1) at the time of diagnosis. As depicted in fig-

ure 5, primary tumours of patients with liver metastases revealed a significantly lower expression level of most ligands and receptors (p < 0.05 for VEGF-A, p = 0.004 for VEGF-B and -C, p < 0.01 for VEGFR-2 and -3). Only the reduced expression of VEGFR-1 in the M1 group was not significant (fig. 4e). However, VEGF-D (fig. 5d) was the exception with a non-significant increase in M1 primary tumours. Interestingly, MVD also tended to be lower in primary tumours of patients with liver metastases (fig. 5h), but the p value of 0.081 did not reach statistical significance, while LVD showed no difference between regional and distant metastasized primary tumours.

Comparing the M1 group with the M0 group expression levels in lymph node metastases, the tendency of all VEGF ligands and receptors remained identical (comparison not shown). These findings are in accordance with the data in figure 3.

A similar pattern is also found by regarding the tumour diameter (data not shown). Bigger tumours have a



**Fig. 4.** Spearman correlation of LVD with expression of VEGF-C (a), VEGF-D (b), and VEGFR-3 (c) in primary tumours (n = 25). LVD was calculated as mean of LYVE-1-positive counts per 1 mm<sup>2</sup>. mRNA amounts were determined by quantitative RT-PCR and presented as relative expression normalized to 10<sup>6</sup>

GAPDH mRNA copies. Indicated p values and correlation coefficients were calculated by Spearman correlation. **d** Immunohistochemical staining of LYVE-1-positive vessels (brown) in a representative primary EC cell carcinoid of the ileum. Magnification  $\times 200$ .

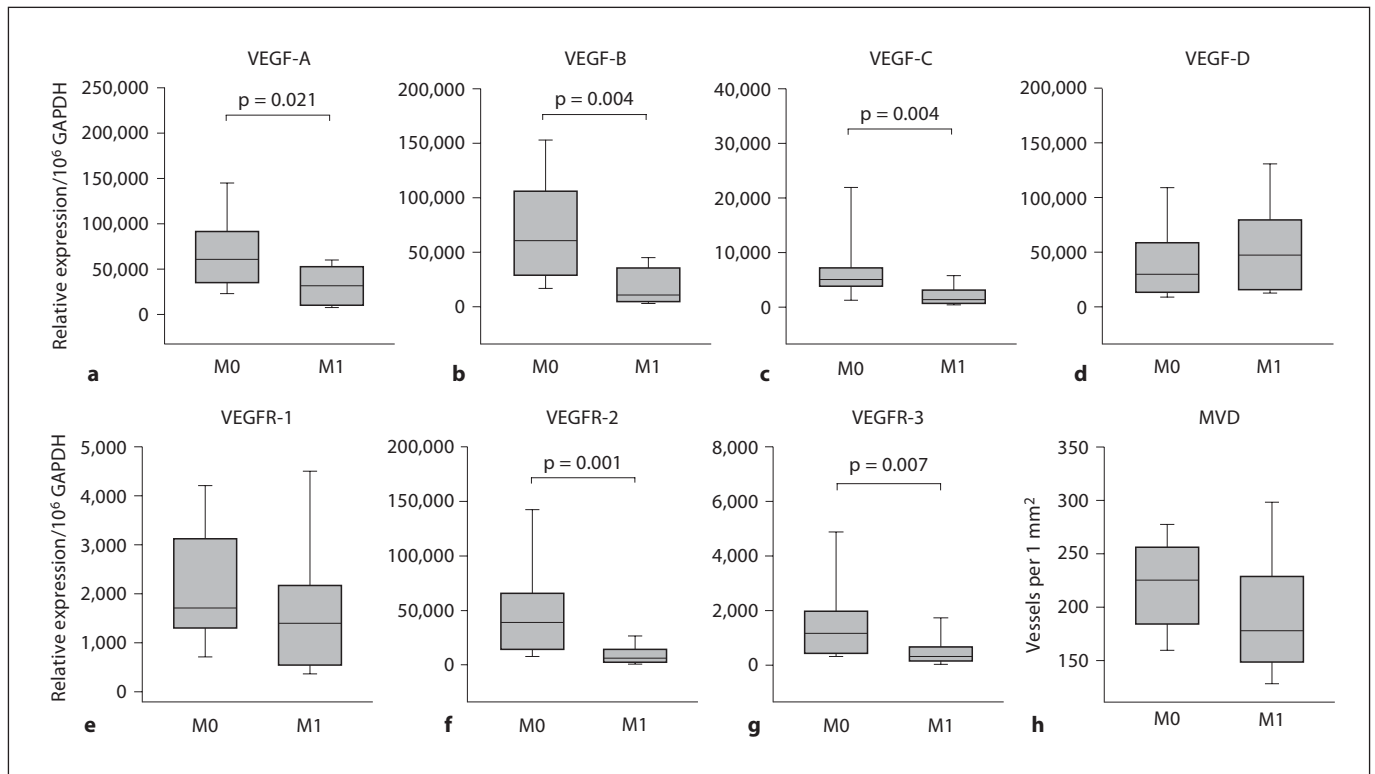
significantly decreased MVD ( $p = 0.025$ ) and a significantly decreased expression of VEGF ligands ( $p < 0.05$  for VEGF-A,  $p < 0.01$  for VEGF-B and -C) and receptors ( $p < 0.05$ ), except VEGF-D, which here shows an opposite tendency.

#### *Prognostic Relevance of MVD and VEGF Ligands and Receptors in Patients with Ileal Carcinoids*

Another aim of this study was to determine whether MVD or expression of VEGF ligands and receptors

could be used for survival prognosis of patients with ileal EC cell carcinoids. Kaplan-Meier survival analysis was calculated for all VEGF ligands and receptors. But most of the parameters were not related to survival (data not shown). Only a low VEGF-B expression showed a significant relation with poor survival after resection of the carcinoid (fig. 6b,  $p = 0.017$ ), while VEGF-A expression barely missed significance (fig. 6a). Further, MVD and LVD were of no prognostic relevance (data not shown).





**Fig. 5.** Comparison of primary tumours originating from patients without liver metastases (M0, n = 15) with tumours of patients with liver metastases (M1, n = 10) regarding expression levels of VEGF-A (a), VEGF-B (b), VEGF-C (c), VEGF-D (d), VEGFR-1 (e), VEGFR-2 (f), VEGFR-3 (g), and MVD (h). Expression was determined by quantitative RT-PCR and is shown as relative expression

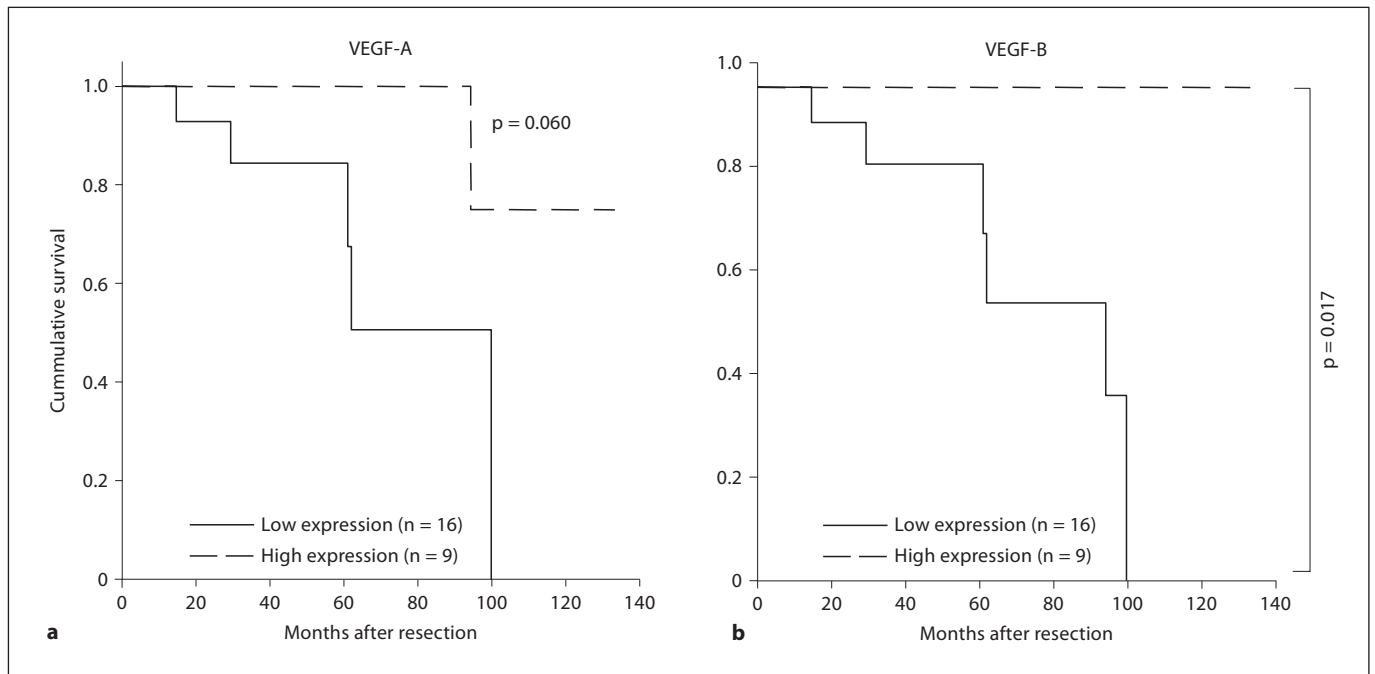
normalized to 10<sup>6</sup> GAPDH mRNA copies. MVD was calculated as mean of CD-31-positive counts per 1 mm<sup>2</sup>. Boxes represent the 25th, 50th, and 75th percentiles and whiskers the 5th and 95th percentiles. p values are indicated and were calculated by the Mann-Whitney rank sum test.

## Discussion

Ileal EC cell carcinoids are characterized by the development of lymph node as well as liver metastases, but the molecular mechanism underlying this process has not been characterized so far. A possible mechanism is the secretion of angiogenic factors by tumour cells, allowing the formation of capillary vessels during tumour invasion for the nutrition of the tumour, but also lymphatic vessels necessary for lymph node metastasis [22]. We therefore aimed to identify the role of angiogenic and lymphangiogenic factors involved in the process of distant spreading for ileal EC cell carcinoids. The expression levels of different angiogenic ligands and receptors were determined by semi-quantitative RT-PCR and expression was correlated with MVD, LVD, as well as with patients' survival. It has to be mentioned that ileal mucosa mainly consists of non-endocrine cells, and thus, a comparison

between different cell types may not be exact. However, we matched the expression of the factors in different tissues of each patient, allowing an individual comparison of basal expression in ileal mucosa versus tumour or metastatic tissue.

VEGF-A is a member of the VEGF family that accounts for the induction of angiogenesis via VEGFR-1 and -2 [9]. VEGF-A expression has been detected in numerous solid cancer tissues, and monoclonal antibodies against VEGF-A such as Avastin are widely used in clinical practice, especially in macula degeneration [23] and colorectal cancer [24]. In our current work, we detected a comparably high expression of VEGF-A in ileal EC cell carcinoids, consistent with previous findings using immunohistochemistry in carcinoids of varying origin [14, 15, 25]. Additionally, VEGF-A expression showed a close positive correlation to MVD. Therefore, VEGF-A may indeed be important for vascularization of these tumours



**Fig. 6.** Kaplan-Meier survival curve correlating patients' survival with high versus low expression of VEGF-A (**a**) (low  $n = 16$ , high  $n = 9$ , cut-off at 55,000 mRNA copies/ $10^6$  GAPDH mRNA copies) and VEGF-B (**b**) (low  $n = 16$ , high  $n = 9$ , cut-off at 45,000 mRNA copies/ $10^6$  GAPDH mRNA copies) in primary tumours. Survival time is presented in months after resection. Analysed with survival log rank.

corresponding to the findings of Zhang et al. [15], while other studies could not prove an association of VEGF-A and microvessel growth [14, 25]. The influence of VEGF-A on lymphangiogenesis is not quite clear. Some studies indicate a lymphangiogenic effect of VEGF-A through VEGFR-2 expressed in lymphatic endothelial cells [26], while others point out the opposite [27]. However, our findings did not reveal any relation of VEGF-A to LVD. Furthermore, VEGF-A expression did not significantly correlate to patients' survival, even if there has been a tendency to poorer outcome at low levels, a trend that corresponds to the significant decrease in VEGF-A expression in ileal EC cell carcinoids with hepatic spread. In contrast to our results, Zhang et al. [15] proved an association of high VEGF-A with poor prognosis in neuroendocrine tumours with mixed origin, while other studies found no correlation of VEGF-A with tumour malignancy [14, 25]. Overall, it appears that VEGF-A is important for vascularization in ileal EC cell carcinoids, but does not appear to be a specific target, as it is also highly expressed in normal mucosa and downregulated in tumours with distant metastases.

VEGF-B acts as a selective ligand of VEGFR-1 and is detectable in most tissues and organs [28, 29], and many neoplasms [30]. The exact function of VEGF-B *in vivo* is still unknown [31]. Some investigators suggest a lacking pro-angiogenic function of VEGF-B [32–34], while others found a positive influence on angiogenesis [10, 35–38]. Recent investigations indicate a potent anti-apoptotic effect of VEGF-B by downregulation of apoptosis and cell death-related proteins [39]. In our study, we found that VEGF-B was expressed at a low level, but significantly enhanced in tumour tissue of primary ileal EC cell carcinoids and lymph node metastases in contrast to normal mucosa, suggesting that VEGF-B expression might play a role in local tumour development. This finding corresponds to observations in other carcinomas, which had higher VEGF-B levels than the corresponding normal tissue, e.g. colon carcinoma [40]. In our study, the clear positive correlation to MVD indicates a possible connection of VEGF-B to angiogenesis, while the lacking correlation to LVD confirms the widespread opinion of an absent lymphangiogenic role of VEGF-B [10, 12, 31]. All tumours had at least regional lymph node metastases, so a possible association of lymphatic metastases with VEGF-

B expression, like in colorectal cancer [41], could not be analysed. But there was a significant downregulation of VEGF-B in tumours with distant metastases. Consequently, considering targeted therapy in the context of increased VEGF-B expression in ileal EC cell carcinoids has to be scrutinized regarding the influence of distant metastases and the negative correlation of low expression levels with survival.

VEGF-C, a member of the VEGF family, has lymphangiogenic potential through VEGFR-3 and acts after proteolytic processing through VEGFR-2 [12, 42]. Compared to the other VEGF ligands, VEGF-C levels were quite low, showed no significant increase in neoplastic tissue and decreased with distant metastases. Although a positive correlation between VEGF-C expression and lymph node metastasis and a prognostic impact of VEGF-C have been described by several groups for several cancer types (see review in Duff et al. [43]), we found no correlation between VEGF-C and LVD or survival. However, high VEGF-C expression was associated with high MVD, indicating a possible angiogenic function in ileal EC cell carcinoids.

Furthermore, VEGF-D has been shown to stimulate tumour angiogenesis, lymphangiogenesis, and tumour progression through interaction with VEGFR-3 and –after processing – VEGFR-2 on blood and lymphatic vessel endothelial cells [9, 42, 44, 45]. Production of VEGF-D by tumour cells has been reported in numerous other cancer tissues, such as gastric [46] or colorectal cancer [47]. We found an increased production of VEGF-D in primary tumours and lymph node metastases compared to normal mucosa. In contrast to the other VEGF ligands, VEGF-D expression revealed no difference with raising malignancy, and did not correlate with MVD. Additionally, this ligand did not show any relation to LVD or prognostic relevance, raising the question of its function in the ileal EC cell carcinoids. One possible answer may be an autocrine activation of VEGFR-2 by VEGF-D, as VEGFR-2 can be located on the surface of endothelial cells or of the tumour cell itself [48].

The VEGFRs as targets for these ligands and mediators of angiogenesis or lymphangiogenesis were also in the centre of attention of our study. Furthermore, they have already been therapeutically focused in clinical trials [49].

The role of VEGFR-1, a receptor for VEGF-A and -B mainly located on endothelial cells, remains poorly understood. Some studies limit its function to a decoy receptor for VEGF-A without signalling power, others suggest a direct impact in pathological angiogenesis [10].

Causal for these contradictory findings may be the differences in phosphorylation of the receptor tyrosine kinases altered by the different ligands [50]. Although in our study there has been a significant elevation in neoplastic tissue and a correlation to MVD, expression levels of VEGFR-1 were very weak and had no prognostic relevance, questioning its therapeutic influence in ileal EC cell carcinoids. In line with this are previous findings [25], which did reveal a partial expression on ileal carcinoids by immunohistochemistry, but could not associate MVD, tumour malignancy, or prognosis with VEGFR-1 expression.

VEGFR-3 binds VEGF-C and -D preferentially and is an important mediator of lymphangiogenesis [31]. In our study, VEGFR-3 occurred mainly in lymph node metastases, corresponding to the normally quite restricted location of VEGFR-3 on lymphatic vessels [42, 44]. The surprising lack of correlation with LVD and existing association with MVD may indicate VEGFR-3 co-expression with VEGFR-2 on blood vessel endothelia, as found in other tumours [12], since LVD levels were clearly lower than MVD in the examined tumours. So, a therapeutic approach targeting the blockade of VEGFR-3 for restricted inhibition of lymphangiogenesis does not seem promising.

VEGFR-2, a receptor of VEGF-A and proteolytically processed VEGF-C and -D, is involved integrally in proliferation and migration of blood vessel endothelial cells [31]. Corresponding to previous findings [25], in our study, the expression of this receptor was increased significantly in primary tumours compared to normal mucosa, but, in contrast, strongly correlated with MVD. Additionally, the remarkable high absolute level of VEGFR-2 may indicate the additional localization of the receptor on the surface of the tumour cells and the possibility of an autocrine loop [48, 51]. Anyway, the decreased expression in tumours with distant metastases and the lacking influence on patients' survival suggest a limited therapeutic impact in advanced ileal EC cell carcinoids consistent with a non-randomized phase II study with sunitinib, an oral tyrosine kinase inhibitor with activity against VEGFRs and other receptors, which could not definitely define its activity against advanced carcinoid tumours [49].

Angiogenesis is necessary for tumour growth beyond a critical size of about 1 mm<sup>3</sup> [52]. In line with Zhang et al. [15] and in contrast to La Rosa et al. [25], in our study the density of CD-31-positive vessels positively correlated with the expression of VEGF ligands and their receptors, except for VEGF-D. This observation corresponds to the

well-known influence of these pro-angiogenic factors secreted by tumour cells or surrounding stroma cells on vessel development [53]. High MVD is correlated with an adverse prognosis and higher tumour malignancy in many carcinomas [53], but our data did not reveal any prognostic impact of the MVD in ileal EC cell carcinoids; vessel density even tended to decrease with rising malignancy, indicating an inverse association of tumour aggressiveness and MVD for neuro-endocrine digestive tumours, as suggested by Poncet et al. [54] and proved for pancreatic neuro-endocrine tumours in several studies [16, 55].

Lymphangiogenesis is another possible target for cancer therapy. An association of high LVD, rising regional and distant metastases, and poor patients' survival was found for different types of tumours [8]. Further, the VEGF-C/VEGF-D/VEGFR-3 signalling axis was shown to induce metastatic spread [56], and a variety of human cancers revealed a correlation between high expression of VEGF-C, VEGF-D and/or VEGFR-3 and high LVD, lymph node metastasis and shortened survival [57–59]. In contrast, our findings did not show a correlation between the overall low LVD and expression levels of any VEGF or VEGFR, especially of VEGF-C, -D, and VEGFR-3, with systemic spread, or patients' overall survival in ileal EC cell carcinoids. These inconsistent results may be explained by lymphangiogenesis as an early event in tumourigenesis, losing its prognostic relevance in advanced cancers [56], as this study only contains tumours of stages III and IV.

In striking contrast to the data for VEGF-A in neuro-endocrine digestive tumours reported by Zhang et al. [15], we found that high expression of the VEGF family as well as blood and LVD in ileal EC cell carcinoids did not correlate with patient survival. Only VEGF-B showed a correlation between low expression levels and poor survival, and the same trend was also observed for VEGF-A.

In accordance with this, there was an almost generally significant decrease in VEGF ligand and receptor expression, excluding VEGF-D, and a trend of lower MVD in tumours with liver metastases. This very important finding underlines the observation that while there is increased expression of vascular growth factors in ileal EC cell carcinoids, its level does not seem to be of functional importance for aggressive metastatic spreading. This corresponds to pancreatic endocrine tumours [16] and a xenograft model revealing lower MVD, lower VEGF-A expression, and distant spreading with raising malignancy of neuro-endocrine tumours [54], while Zhang et al.

[15] correlated tumour spreading in neuro-endocrine digestive tumours of mixed origin with high VEGF-A expression. The loss of expression in tumours with liver metastases is also in line with previous observations from our own group [60] showing low expression levels of matrix metalloproteinases. Considering genomic studies on carcinoids revealing large chromosomal alterations [61], a possible conclusion is a loss of differentiation during tumour development underlining the thesis of Poncet et al. [54] regarding high MVD as a marker of differentiation in neuro-endocrine digestive tumours.

In summary, the present study provides evidence that VEGFR-1, -2, and -3, and ligands A, B, C, and D are expressed in ileal EC cell carcinoid tumours and were, apart from VEGF-D, related to MVD, while none of them correlated with LVD. High expression levels of these factors tended to be associated with carcinoids without haematogenous spread and VEGF-B revealed poor prognosis when expressed at low levels. The other VEGFs and VEGFRs, as well as MVD and LVD failed to demonstrate a prognostic impact in this study. Consequently, although angiogenesis is essential for tumourigenesis, an anti-angiogenic therapy targeting the VEGF ligand and receptor family does not seem promising for advanced ileal EC cell carcinoids.

### Acknowledgement

The study was supported by DFG Pr 411/12-1. This work is part of the medical thesis of S.B.

### References

- 1 Levy AD, Sobin LH: From the archives of the AFIP: gastrointestinal carcinoids: imaging features with clinicopathologic comparison. *Radiographics* 2007;27:237–257.
- 2 Capella C, Heitz PU, Hofler H, Solcia E, Kloppel G: Revised classification of neuro-endocrine tumours of the lung, pancreas and gut. *Virchows Arch* 1995;425:547–560.
- 3 Janson ET, Holmberg L, Stridsberg M, Eriksson B, Theodorsson E, Wilander E, Oberg K: Carcinoid tumors: analysis of prognostic factors and survival in 301 patients from a referral center. *Ann Oncol* 1997;8:685–690.
- 4 Tomassetti P, Campana D, Piscitelli L, Casadei R, Nori F, Brocchi E, Santini D, Pezzilli R, Corinaldesi R: Endocrine tumors of the ileum: factors correlated with survival. *Neuroendocrinology* 2006;83:380–386.
- 5 Roukos DH, Kappas AM: Perspectives in the treatment of gastric cancer. *Nat Clin Pract Oncol* 2005;2:98–107.



- 6 Hofler H, Stier A, Schusdziarra V, Siewert JR: Classification of neuroendocrine tumors of the gastrointestinal tract and pancreas and its therapeutic relevance. *Chirurg* 1997; 68:107–115.
- 7 Carmeliet P, Jain RK: Angiogenesis in cancer and other diseases. *Nature* 2000;407:249–257.
- 8 Das S, Skobe M: Lymphatic vessel activation in cancer. *Ann NY Acad Sci* 2008;1131:235–241.
- 9 Ferrara N, Gerber HP, LeCouter J: The biology of VEGF and its receptors. *Nat Med* 2003;9:669–676.
- 10 Nash AD, Baca M, Wright C, Scotney PD: The biology of vascular endothelial growth factor-B (VEGF-B). *Pulm Pharmacol Ther* 2006;19:61–69.
- 11 Makinen T, Veikkola T, Mustjoki S, Karpanen T, Catimel B, Nice EC, Wise L, Mercer A, Kowalski H, Kerjaschki D, Stacker SA, Achen MG, Alitalo K: Isolated lymphatic endothelial cells transduce growth, survival and migratory signals via the VEGF-C/D receptor VEGFR-3. *EMBO J* 2001;20:4762–4773.
- 12 Tammela T, Enholm B, Alitalo K, Paavonen K: The biology of vascular endothelial growth factors. *Cardiovasc Res* 2005;65: 550–563.
- 13 Schnirer II, Yao JC, Ajani JA: Carcinoid – A comprehensive review. *Acta Oncol* 2003;42: 672–692.
- 14 Terris B, Scoazec JY, Rubbia L, Bregeaud L, Pepper MS, Ruzsniowski P, Belghiti J, Flejou J, Degott C: Expression of vascular endothelial growth factor in digestive neuroendocrine tumours. *Histopathology* 1998;32: 133–138.
- 15 Zhang J, Jia Z, Li Q, Wang L, Rashid A, Zhu Z, Evans DB, Vauthey JN, Xie K, Yao JC: Elevated expression of vascular endothelial growth factor correlates with increased angiogenesis and decreased progression-free survival among patients with low-grade neuroendocrine tumors. *Cancer* 2007;109:1478–1486.
- 16 Couvelard A, O’Toole D, Turley H, Leek R, Sauvanet A, Degott C, Ruzsniowski P, Belghiti J, Harris AL, Gatter K, Pezzella F: Microvascular density and hypoxia-inducible factor pathway in pancreatic endocrine tumours: negative correlation of microvascular density and VEGF expression with tumour progression. *Br J Cancer* 2005;92: 94–101.
- 17 Rindi G, Kloppel G, Couvelard A, Komminoth P, Korner M, Lopes JM, McNicol AM, Nilsson O, Perren A, Scarpa A, Scoazec JY, Wiedenmann B: TNM staging of midgut and hindgut (neuro) endocrine tumors: a consensus proposal including a grading system. *Virchows Arch* 2007;451:757–762.
- 18 Rad R, Gerhard M, Lang R, Schoniger M, Rosch T, Schepp W, Becker I, Wagner H, Prinz C: The *Helicobacter pylori* blood group antigen-binding adhesin facilitates bacterial colonization and augments a nonspecific immune response. *J Immunol* 2002;168: 3033–3041.
- 19 Rad R, Brenner L, Bauer S, Schwendy S, Layland L, da Costa CP, Reindl W, Dossumbekova A, Friedrich M, Saur D, Wagner H, Schmid RM, Prinz C: CD25+/Foxp3+ T cells regulate gastric inflammation and *Helicobacter pylori* colonization in vivo. *Gastroenterology* 2006;131:525–537.
- 20 Weidner N, Semple JP, Welch WR, Folkman J: Tumor angiogenesis and metastasis – Correlation in invasive breast carcinoma. *N Engl J Med* 1991;324:1–8.
- 21 Florez-Vargas A, Vargas SO, Debelenko LV, Perez-Atayde AR, Archibald T, Kozakewich HP, Zurakowski D: Comparative analysis of D2–40 and LYVE-1 immunostaining in lymphatic malformations. *Lymphology* 2008;41:103–110.
- 22 Sipos B, Klapper W, Kruse ML, Kalthoff H, Kerjaschki D, Kloppel G: Expression of lymphangiogenic factors and evidence of intratumoral lymphangiogenesis in pancreatic endocrine tumors. *Am J Pathol* 2004;165: 1187–1197.
- 23 Bashshur ZF, Haddad ZA, Schakal A, Jaafar RF, Saab M, Noureddin BN: Intravitreal bevacizumab for treatment of neovascular age-related macular degeneration: a one-year prospective study. *Am J Ophthalmol* 2008; 145:249–256.
- 24 Fieth C, Kebig A, Mohr K: Angiogenesis inhibitors in cancer therapy. Bevacizumab against colon carcinoma. *Pharm Unserer Zeit* 2007;36:442–445.
- 25 La Rosa S, Uccella S, Finzi G, Albarello L, Sessa F, Capella C: Localization of vascular endothelial growth factor and its receptors in digestive endocrine tumors: correlation with microvessel density and clinicopathologic features. *Hum Pathol* 2003;34:18–27.
- 26 Nagy JA, Vasile E, Feng D, Sundberg C, Brown LF, Detmar MJ, Lawitts JA, Benjamin L, Tan X, Manseau EJ, Dvorak AM, Dvorak HF: Vascular permeability factor/vascular endothelial growth factor induces lymphangiogenesis as well as angiogenesis. *J Exp Med* 2002;196:1497–1506.
- 27 Burton JB, Priceman SJ, Sung JL, Brakenhielm E, An DS, Pytowski B, Alitalo K, Wu L: Suppression of prostate cancer nodal and systemic metastasis by blockade of the lymphangiogenic axis. *Cancer Res* 2008;68: 7828–7837.
- 28 Aase K, Lymboussaki A, Kaipainen A, Olofsson B, Alitalo K, Eriksson U: Localization of VEGF-B in the mouse embryo suggests a paracrine role of the growth factor in the developing vasculature. *Dev Dyn* 1999;215:12–25.
- 29 Li X, Aase K, Li H, von Euler G, Eriksson U: Isoform-specific expression of VEGF-B in normal tissues and tumors. *Growth Factors* 2001;19:49–59.
- 30 Salven P, Lymboussaki A, Heikkila P, Jaaskela-Saari H, Enholm B, Aase K, von EG, Eriksson U, Alitalo K, Joensuu H: Vascular endothelial growth factors VEGF-B and VEGF-C are expressed in human tumors. *Am J Pathol* 1998;153:103–108.
- 31 O’Toole ZK, Makarem JA, Shamseddine AI: Vascular endothelial growth factor family of ligands and receptors: review. *Blood Cells Mol Dis* 2007;38:258–268.
- 32 Bhardwaj S, Roy H, Gruchala M, Viita H, Kholova I, Kokina I, Achen MG, Stacker SA, Hedman M, Alitalo K, Yla-Herttuala S: Angiogenic responses of vascular endothelial growth factors in periaortic tissue. *Hum Gene Ther* 2003;14:1451–1462.
- 33 Reichelt M, Shi S, Hayes M, Kay G, Batch J, Gole GA, Browning J: Vascular endothelial growth factor-B and retinal vascular development in the mouse. *Clin Experiment Ophthalmol* 2003;31:61–65.
- 34 Rissanen TT, Markkanen JE, Gruchala M, Heikura T, Puranen A, Kettunen MI, Kholova I, Kauppinen RA, Achen MG, Stacker SA, Alitalo K, Yla-Herttuala S: VEGF-D is the strongest angiogenic and lymphangiogenic effector among VEGFs delivered into skeletal muscle via adenoviruses. *Circ Res* 2003;92:1098–1106.
- 35 Silvestre JS, Tamarat R, Ebrahimian TG, LeRoux A, Clergue M, Emmanuel F, Duriez M, Schwartz B, Branellec D, Levy BI: Vascular endothelial growth factor-B promotes in vivo angiogenesis. *Circ Res* 2003;93:114–123.
- 36 Wafai R, Tudor EM, Angus JA, Wright CE: Vascular effects of FGF-2 and VEGF-B in rabbits with bilateral hind limb ischemia. *J Vasc Res* 2009;46:45–54.
- 37 Wright CE: Effects of vascular endothelial growth factor (VEGF)A and VEGFB gene transfer on vascular reserve in a conscious rabbit hindlimb ischaemia model. *Clin Exp Pharmacol Physiol* 2002;29:1035–1039.
- 38 Mould AW, Greco SA, Cahill MM, Tonks ID, Bellomo D, Patterson C, Zournazi A, Nash A, Scotney P, Hayward NK, Kay GF: Transgenic overexpression of vascular endothelial growth factor-B isoforms by endothelial cells potentiates postnatal vessel growth in vivo and in vitro. *Circ Res* 2005;97:e60–e70.
- 39 Li Y, Zhang F, Nagai N, Tang Z, Zhang S, Scotney P, Lennartsson J, Zhu C, Qu Y, Fang C, Hua J, Matsuo O, Fong GH, Ding H, Cao Y, Becker KG, Nash A, Heldin CH, Li X: VEGF-B inhibits apoptosis via VEGFR-1-mediated suppression of the expression of BH3-only protein genes in mice and rats. *J Clin Invest* 2008;118:913–923.



- 40 Hanrahan V, Currie MJ, Gunningham SP, Morrin HR, Scott PA, Robinson BA, Fox SB: The angiogenic switch for vascular endothelial growth factor (VEGF)-A, VEGF-B, VEGF-C, and VEGF-D in the adenoma-carcinoma sequence during colorectal cancer progression. *J Pathol* 2003;200:183-194.
- 41 Kawakami M, Furuhashi T, Kimura Y, Yamaguchi K, Hata F, Sasaki K, Hirata K: Expression analysis of vascular endothelial growth factors and their relationships to lymph node metastasis in human colorectal cancer. *J Exp Clin Cancer Res* 2003;22:229-237.
- 42 Stacker SA, Achen MG, Jussila L, Baldwin ME, Alitalo K: Lymphangiogenesis and cancer metastasis. *Nat Rev Cancer* 2002;2:573-583.
- 43 Duff SE, Li C, Jeziorska M, Kumar S, Saunders MP, Sherlock D, O'Dwyer ST, Jayson GC: Vascular endothelial growth factors C and D and lymphangiogenesis in gastrointestinal tract malignancy. *Br J Cancer* 2003;89:426-430.
- 44 Karkkainen MJ, Petrova TV: Vascular endothelial growth factor receptors in the regulation of angiogenesis and lymphangiogenesis. *Oncogene* 2000;19:5598-5605.
- 45 Veikkola T, Karkkainen M, Claesson-Welsh L, Alitalo K: Regulation of angiogenesis via vascular endothelial growth factor receptors. *Cancer Res* 2000;60:203-212.
- 46 Juttner S, Wissmann C, Jons T, Vieth M, Hertel J, Gretschel S, Schlag PM, Kemmner W, Hocker M: Vascular endothelial growth factor-D and its receptor VEGFR-3: two novel independent prognostic markers in gastric adenocarcinoma. *J Clin Oncol* 2006;24:228-240.
- 47 Onogawa S, Kitadai Y, Tanaka S, Kuwai T, Kimura S, Chayama K: Expression of VEGF-C and VEGF-D at the invasive edge correlates with lymph node metastasis and prognosis of patients with colorectal carcinoma. *Cancer Sci* 2004;95:32-39.
- 48 Weigand M, Hantel P, Kreienberg R, Waltenberger J: Autocrine vascular endothelial growth factor signalling in breast cancer. Evidence from cell lines and primary breast cancer cultures in vitro. *Angiogenesis* 2005;8:197-204.
- 49 Kulke MH, Lenz HJ, Meropol NJ, Posey J, Ryan DP, Picus J, Bergsland E, Stuart K, Tye L, Huang X, Li JZ, Baum CM, Fuchs CS: Activity of sunitinib in patients with advanced neuroendocrine tumors. *J Clin Oncol* 2008;26:3403-3410.
- 50 Roskoski R Jr: Vascular endothelial growth factor (VEGF) signaling in tumor progression. *Crit Rev Oncol Hematol* 2007;62:179-213.
- 51 Lee S, Chen TT, Barber CL, Jordan MC, Murdock J, Desai S, Ferrara N, Nagy A, Roos KP, Iruela-Arispe ML: Autocrine VEGF signaling is required for vascular homeostasis. *Cell* 2007;130:691-703.
- 52 Folkman J: Angiogenesis. *Annu Rev Med* 2006;57:1-18.
- 53 Zetter BR: Angiogenesis and tumor metastasis. *Annu Rev Med* 1998;49:407-424.
- 54 Poncet G, Villaume K, Walter T, Pourreyron C, Theillaumas A, Lepinasse F, Hervieu V, Cordier-Bussat M, Scaoze JY, Roche C: Angiogenesis and tumor progression in neuroendocrine digestive tumors. *J Surg Res* 2009;154:68-77.
- 55 Takahashi Y, Kishima-Fukasawa Y, Kobayashi N, Sano T, Kosuge T, Nimura Y, Kanai Y, Hiraoka N: Prognostic value of tumor architecture, tumor-associated vascular characteristics, and expression of angiogenic molecules in pancreatic endocrine tumors. *Clin Cancer Res* 2007;13:187-196.
- 56 Sundar SS, Ganesan TS: Role of lymphangiogenesis in cancer. *J Clin Oncol* 2007;25:4298-4307.
- 57 Choi JH, Oh YH, Park YW, Baik HK, Lee YY, Kim IS: Correlation of vascular endothelial growth factor-D expression and VEGFR-3-positive vessel density with lymph node metastasis in gastric carcinoma. *J Korean Med Sci* 2008;23:592-597.
- 58 Gu Y, Qi X, Guo S: Lymphangiogenesis induced by VEGF-C and VEGF-D promotes metastasis and a poor outcome in breast carcinoma: a retrospective study of 61 cases. *Clin Exp Metastasis* 2008;25:717-725.
- 59 Zhang B, Zhao WH, Zhou WY, Yu WS, Yu JM, Li S: Expression of vascular endothelial growth factors-C and -D correlate with evidence of lymphangiogenesis and angiogenesis in pancreatic adenocarcinoma. *Cancer Detect Prev* 2007;31:436-442.
- 60 Volland P, Besig S, Rad R, Braun T, Baur DM, Perren A, Langer R, Hofler H, Prinz C: Correlation of matrix metalloproteinases and tissue inhibitors of matrix metalloproteinase expression in ileal carcinoids, lymph nodes and liver metastasis with prognosis and survival. *Neuroendocrinology* 2009;89:66-78.
- 61 Kulke MH, Freed E, Chiang DY, Phillips J, Zahrieh D, Glickman JN, Shivdasani RA: High-resolution analysis of genetic alterations in small bowel carcinoid tumors reveals areas of recurrent amplification and loss. *Genes Chromosomes Cancer* 2008;47:591-603.