

# Reversible Foetal Cerebral Ventriculomegaly and Cardiomyopathy under Chemotherapy for Maternal AML

Anne K. Baumgärtner R. Oberhoffer Volker R. Jacobs E. Ostermayer H. Menzel M. Voigt  
K.T.M. Schneider S. Pildner von Steinburg

Abteilung Perinatalmedizin, Frauenklinik rechts der Isar der Technischen Universität München, Germany

## Key Words

AML · Chemotherapy in pregnancy · Ventriculomegaly · Hydrocephalus · Cardiac impairment

## Summary

**Background:** Leukaemia in pregnancy is a rare complication demanding a multidisciplinary approach and careful management to handle potential complications and cope with ethical dilemmas. **Patient and Methods:** We report on a patient with acute myeloid leukaemia (AML) relapse in 22 weeks of gestation who received chemotherapy with cytarabine and mitoxantrone, as well as fludarabine, cytarabine, idarubicin, and gemtuzumab-ozogamicin. We describe findings on regular ultrasound examinations and successful management of complications. **Results:** The foetus developed signs of anthracycline-induced cardiomyopathy, transient cerebral ventriculomegaly, anaemia, and intrauterine growth restriction. The child was delivered by Caesarean section at 33 + 1 weeks of gestation. The newborn showed no congenital malformations. **Conclusion:** This case report confirms that chemotherapy for treatment of AML can be applied in the second trimester of pregnancy under close and careful maternal and foetal monitoring.

## Schlüsselwörter

AML · Chemotherapie in der Schwangerschaft · Ventriculomegalie · Hydrocephalus · Kardiale Beeinträchtigung

## Zusammenfassung

**Hintergrund:** Leukämie während der Schwangerschaft ist eine seltene Komplikation, die der interdisziplinären Zusammenarbeit der Therapeuten bedarf, um Komplikationen zu meistern und ethische Konflikte zu lösen. **Patientin und Methoden:** Wir berichten über eine Patientin mit einem Rezidiv einer akuten myeloischen Leukämie (AML) in der 22. Schwangerschaftswoche, die Chemotherapien mit Cytarabin und Mitoxantrone sowie Fludarabin, Cytarabin, Idarubicin und Gemtuzumab-Ozogamicin erhielt. Wir beschreiben die Befunde der fetalen Ultraschalluntersuchungen und berichten über die erfolgreiche Behandlung von Komplikationen. **Ergebnisse:** Der Fetus entwickelte Zeichen einer anthracyclinbedingten Kardiomyopathie, vorübergehender Ventriculomegalie, Anämie und intrauteriner Wachstumsretardierung. Die Entbindung erfolgte per Kaiserschnitt in 33 + 1 Schwangerschaftswochen. Das Neugeborene zeigte keine Fehlbildungen. **Schlussfolgerungen:** Dieser Fallbericht zeigt, dass eine chemotherapeutische Behandlung der AML im zweiten Trimenon bei sorgfältiger fetaler und maternaler Überwachung möglich ist.

## Introduction

Leukaemia in pregnancy is rare, with an incidence of about 1 case in 75,000–100,000 pregnancies, with two-thirds of the newly diagnosed leukaemias being acute myeloid leukaemia (AML) cases [1, 2]. Clinical dilemmas arise from the fact that concern and care for maternal health and prognosis can stand in direct

contrast to foetal wellbeing and integrity. Pregnancy might be complicated by the course of the maternal disease itself due to haematological complications such as anaemia, thrombotic events or infection as a result of immunodeficiency, as well as by the potential teratogenic effects of cytostatic drugs. Moreover, metastatic spread to placenta and foetus has been described in the literature as a rare complication [2].

## Case Report

A 31-year-old IX-gravid VI-parous woman was diagnosed with AML, type FAB M5b, in 37 weeks of gestation. Past obstetric history included five spontaneous deliveries, one intrauterine foetal death, and two elective abortions. After delivery, she received chemotherapy with two courses of cytarabine 100 mg/m<sup>2</sup> days (d)1–7, idarubicin 12 mg/m<sup>2</sup> d1, 3, 5 and etoposide 100 mg/m<sup>2</sup> d1–3, and three courses of high-dose cytarabine. The patient had a history of chronic hepatitis B and developed heparin-induced thrombocytopenia type I (HIT) as well as human leukocyte antigen (HLA)-specific antibodies against thrombocytes in the course of multiple transfusions.

One year after initial diagnosis, the amenorrhoeic patient relapsed and was simultaneously found to be pregnant at 22 weeks of gestation. The parents opted for continuation of the pregnancy. Chemotherapy was therefore initiated in 22 + 2 weeks of gestation with cytarabine 2 × 1 g/m<sup>2</sup> d1–3 and mitoxantrone 10 mg/m<sup>2</sup> d2–3 (HAM-protocol), which resulted in remission. The mother was in a very poor clinical state during chemotherapy, suffering from herpes simplex laryngitis with neutropenic fever and showed massive hyperbilirubinaemia of toxic origin (serum bilirubin 15 mg/dl). The patient relapsed in 26 + 0 weeks of gestation and salvage treatment with cytarabine 1000 mg/m<sup>2</sup> d2–6, idarubicin 10 mg/m<sup>2</sup> d2–4, fludarabine 30 mg/m<sup>2</sup> d2–6 and gemtuzumab-ozogamicin 3 mg/m<sup>2</sup> d1 (Go-Flag-Ida) was initiated in 28 + 0 gestational weeks, again complicated by neutropenic fever of unknown origin.

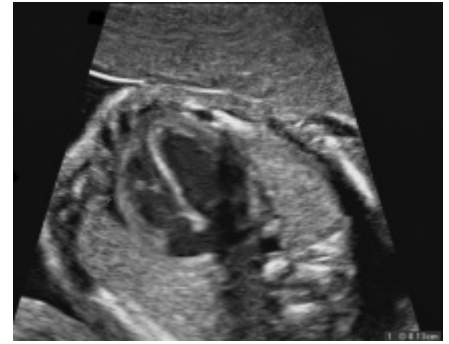
An initial anomaly scan including foetal echocardiography and Doppler ultrasound found a male foetus appropriate for the gestational age and detected no abnormalities. In 23 + 0 weeks of gestation the interventricular septum showed hyperechogenicity; there were mild pericardial effusions (diastolic diameter 1.3 mm) and isolated supraventricular extrasystoles (fig. 1) without underlying structural foetal heart anomaly. At 24 + 0 weeks of gestation, the pericardial effusion was slightly progressive with a diastolic diameter of 4 mm. In 32 + 0 gestational weeks the foetal heart was dilated with a cardiothoracic ratio (CTR) of 0.49 (normal 0.3), showed myocardial hypertrophy (wall thickness 4.5 mm) and dilated coronary arteries (1 mm in diameter). Doppler flow measurements showed a brain sparing effect, and the middle cerebral artery (MCA) peak systolic flow was above 1.5 multiples of the median (MOM) as a hint for foetal anaemia [3].

In 24 + 0 gestational weeks, the foetus was found to be small for the gestational age, with normal Doppler exams, and mild foetal anaemia was detected with MCA peak systolic velocity above 1.5 MOM. The MCA peak systolic velocity remained stable and was normalized at 26 + 2 weeks of gestation. At 26 + 2 gestational weeks, the foetus showed cerebral ventriculomegaly (diameters of the posterior and anterior horns of the lateral ventricle of 16.1 and 8.6 mm, respectively) without signs of cerebral haemorrhage. Ventricular diameters decreased slowly and showed only mild dilatation in 30 + 0 weeks of gestation (9.6 and 3.5 mm, respectively) (fig. 2A and B). Invasive procedures like chorocentesis were impossible due to poor maternal clinical state and thrombocytopenia. TORCH serology (toxoplasmosis, other, rubella, cytomegalovirus (CMV), herpes simplex) was normal.

Even with deteriorating foetal state in 32 + 0 gestational weeks, the timing of delivery was crucial since the mother showed refractory thrombocytopenia (30,000/μl under repletion with HLA-matched thrombocytes) with impaired platelet function (bleeding time > 25 min). Nevertheless, a Caesarean section was performed with simultaneous tubal ligation on patient demand after application of respiratory distress syndrome (RDS) prophylaxis at 33 + 1 gestational weeks under transfusion of fresh frozen plasma and platelets.

The viable male neonate weighed 1695 g, corresponding to the 19th percentile, with Apgar scores of 8 and 9 at 5 and 10 min, respectively, and an arterial umbilical cord pH of 7.27. Requiring intermittent bag mask ventilation immediately after delivery, the newborn adapted fast and was

**Fig. 1.** Fetal echocardiography in 23 + 0 gestational weeks shows first signs of cardiomyopathy with hyperechogenicity of the interventricular septum and mild pericardial effusion (1.3 mm).



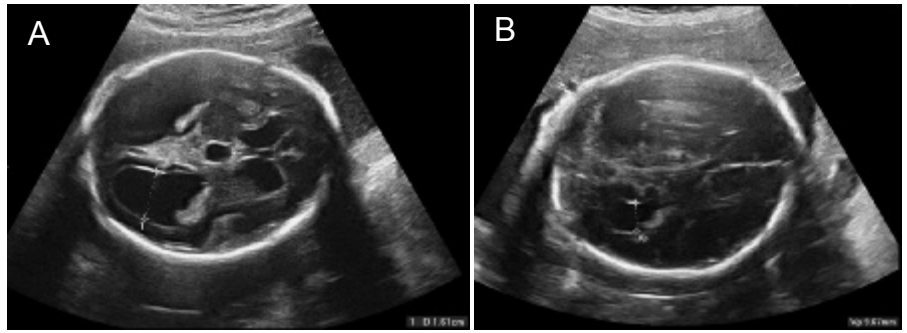
admitted to the neonatal intermediate care unit. Blood count showed anaemia (haemoglobin 10.2 g/dl, reticulocytes 10%) and leukocytes and thrombocytes within normal limits. Even though the mother had a total bilirubin level of 16.2 mg/dl (normal range < 1.2 mg/dl) on the day of delivery, the newborn had normal bilirubin levels. Transcranial ultrasound and echocardiography detected no abnormalities and there were no clinical signs of dysmorphism. Follow-up examinations after 6 months found no residual signs of cardiomyopathy or hydrocephalus. Histologic examination of the placenta revealed signs of placental insufficiency, but no metastatic disease. Postoperative recovery of the mother was complicated by fungal sepsis with *Candida* and ovarian vein thrombosis. She later underwent haploidentical allogeneic stem cell transplantation following reduced intensity conditioning, but unfortunately passed away 8 months after delivery secondary to CMV pneumonia.

## Discussion

Despite conflicting data, course and prognosis of acute leukaemia seem not to be influenced by pregnancy [1]. Apart from application in the first trimester when the foetus is most vulnerable due to organogenesis, chemotherapy seems to be safe in the final two trimesters of pregnancy [4]. However, there is only little data consisting of case reports and retrospective analyses with small numbers of patients, different cytotoxic agents and numerous individual courses of disease [1, 5]. A query at the national German reference bureau of teratology found a majority of successful pregnancy outcomes after chemotherapy for leukaemia, an increased rate of preterm deliveries and stillbirths, intermittent neonatal pancytopenia and foetal growth restriction as the most common complications. Reynoso et al. [5] reported on the outcome of infants exposed to chemotherapy in utero, finding a transient cytopenia rate of 33% after exposure within 4 weeks before delivery and one single case with congenital malformations and secondary malignancies, but no other permanent impairments.

The British guidelines for the treatment of AML in pregnancy recommend the offer of medical abortion in the first trimester, but regard chemotherapy in the second and third trimester as safe for the foetus [4]. Treatment should be started without delay to avoid negative influence on maternal prognosis [6].

In our patient there were signs of foetal cardiomyopathy, noted in the first six days after the application of cytarabine and mi-



**Fig. 2.** Transient cerebral ventriculomegaly. Diameter of the posterior horn of the lateral ventricle in 26 + 2: 16.1 mm (A) and 30 + 0 gestational weeks: 96.7 mm (B).

toxantrone, consisting of hyperechogenicity of the ventricular septum and mild pericardial effusion as well as the presence of isolated extrasystoles. These findings persisted and deteriorated after the application of the second-line treatment with idarubicin, cytarabin, fludarabine and gemtuzumab-ozogamicin. Cytarabine is commonly used in the treatment of leukaemias in combination with other cytotoxic agents. Case reports found no major effect in most fetuses exposed; however, limb malformations after first-trimester exposure, transient cytopenia, intrauterine foetal death (IUFD), intrauterine growth restriction (IUGR) and neonatal death have been described [6]. Anthracyclines cause cardiac side effects in children and adults even years after chemotherapy. Reynoso et al. [7] reported one case of IUFD after exposure to a combination chemotherapy with idarubicin and mitoxantrone; however, there are no publications concerning foetal cardiac effects of mitoxantrone, which was administered initially to our patient [7]. Idarubicine has proven less cardiotoxic and more efficient in the adult leukaemia patient than other anthracyclines; however, due to higher lipid solubility there might be facilitated placental transfer of the drug [8]. There are two case reports on reversible foetal right ventricular dilatation and atrial/ventricular septum defects after exposure to idarubicin in combination with all-trans-retinoic acid or cytarabine [8, 9]. Associated minor skeletal malformations in one of those cases cannot be fully explained by exposure to the agents in the second trimester alone. In one case, idarubicin led to acute cardiac failure, whereas there was no effect whatsoever in another [10, 11]. Meyer-Wittkopf et al. [12] studied the effects of the anthracycline doxorubicin on the foetal heart by serial echocardiography measuring the ventricular shortening fraction and biometry of the ventricular cavities. They found no adverse effects neither in utero nor within the 2-year postnatal follow-up period. There is no published data of effects on the foetus of either gemtuzumab-ozogamicin or fludarabine.

Foetal cardiac impairment might also have been the result of foetal anaemia rather than a direct cardiotoxic effect of the cytostatic drugs alone. This would be supported by the fact that first signs of cardiomyopathy were present 6 days after initiation of chemotherapy and had deteriorated on day 11, when anaemia was diagnosed for the first time. The cardiac situation remained stable, but worsened again significantly 4 weeks after

the second course of chemotherapy, again simultaneously with anaemia and additional brain sparing effect.

All reviews on chemotherapy in pregnancy describe cytopenia as a potential side effect. Morishita et al. [13] monitored foetal haematologic effects of maternal chemotherapy with behenoyl cytarabine, daunorubicin, 6-mercaptopurin and prednisolone for AML type FAB M2 via serial umbilical cord sampling [13]. They found preservation of foetal haematopoiesis against maternal chemotherapy-induced anaemia. In our case, umbilical blood sampling was not possible due to poor maternal clinical state. In summary, the foetal cardiac findings in our patient could be well explained by the direct cardiotoxic effect of anthracyclines and other cytostatic agents given in combination. However, anaemia might also have contributed to high cardiac output failure, resulting in sonographic signs of cardiac decompensation with brain sparing effect and preferential myocardial perfusion. Pericardial effusion, supraventricular extrasystoles and septal hyperechogenicity, which were found in 23 + 0 gestational weeks, are signs well known for anthracycline-induced cardiomyopathy in postnatal life. Myocardial hypertrophy and right-sided congestive heart failure could be interpreted as reactions to foetal anaemia.

The aetiology of the transient cerebral ventriculomegaly in our case remains unclear. No published data exists in the literature on hydrocephalus or ventriculomegaly as specific potential side effects of cytostatic agents. Although there were no signs of intracerebral haemorrhage, we suspected occult bleeding as a result of foetal thrombocytopenia mediated by maternal antibodies or the cytostatic agents themselves. The mother had acquired immunoglobulin G-type HLA-specific antibodies against platelets secondary to multiple transfusions under her previous chemotherapy. Her husband was confirmed to have two of the HLA types that she formed antibodies against, so potential inheritance to the foetus might have caused incompatibility resulting in foetal thrombopenic haemorrhage.

Even though in our case histologic examination of the placenta showed no metastatic disease, metastatic spread to foetus or placenta has been described. Pavlidis [2] reported 58 cases from the literature of maternal cancers metastatic to the products of conception, 11 of which were lymphomas or leukaemias, thus being the second largest group of malignancies metastasizing to the placenta.

## Conclusions

This case report confirms that chemotherapy for treatment of AML can be applied in the second trimester of pregnancy and requires close interdisciplinary maternal and foetal monitoring.

However, the long-term outcome of children exposed to chemotherapy in utero has to be further investigated. A multidisciplinary approach and care for the patient are essential to handle the medical complications and to solve ethical conflicts arising from the differing medical interests of mother and foetus.

## References

- 1 Chelghoum Y, Vey N, Raffoux E, Huguot F, Pigneux A, Witz B, Pautas C, de Botton S, Gyotat D, Lioure B, Fegueux N, Garban F, Saad H, Thomas X: Acute leukemia during pregnancy. A report on 37 patients and a review of the literature. *Cancer* 2005;104:110–117.
- 2 Pavlidis NA: Coexistence of pregnancy and malignancy. *Oncologist* 2002;7:279–287.
- 3 Mari G, Deter RL, Carpenter RL, Rahman F, Zimmerman R, Moise KJ, Jr, Dorman KF, Ludomirsky A, Gonzalez R, Gomez R, Oz U, Detti L, Copel JA, Bahado-Singh R, Berry S, Martinez-Poyer J, Blackwell SC: Noninvasive diagnosis by Doppler ultrasonography of fetal anemia due to maternal red-cell alloimmunization. Collaborative Group for Doppler Assessment of the Blood Velocity in Anemic Fetuses. *N Engl J Med* 2000;342:9–14.
- 4 British Committee for Standards in Haematology, Milligan DW, Grimwade D, Cullis JO, Bond L, Swirsky D, Craddock C, Kell J, Homewood J, Campbell K, McGinley S, Wheatley K, Jackson G: Guidelines on the management of acute myeloid leukaemia in adults. *Br J Haematol* 2006; 135:450–474.
- 5 Reynoso EE, Shepherd FA, Messner HA, Farquharson HA, Garvex MB, Baker MA: Acute leukemia during pregnancy: the Toronto Leukemia Study Group experience with long-term follow-up of children exposed in utero to chemotherapeutic agents. *J Clin Oncol* 1987;5:1098–1106.
- 6 Cardonick E, Iacobucci A: Use of chemotherapy during human pregnancy. *Lancet Oncol* 2004;5:283–291.
- 7 Reynoso EE, Huerta F: Acute leukemia and pregnancy. Fatal fetal outcome after exposure to idarubicin during the second trimester. *Acta Oncol* 1994;33:709–710.
- 8 Niedermeier DM, Frei-Lahr DA, Hall PD: Treatment of acute myeloid leukemia during the second and third trimesters of pregnancy. *Pharmacotherapy* 2005;25:1134–1140.
- 9 Siu BL, Alonzo MR, Vargo TA, Fenrich AL: Transient dilated cardiomyopathy in a newborn exposed to idarubicin and all-trans-retinoic acid (ATRA) early in the second trimester of pregnancy. *Int J Gynecol Cancer* 2002;12:399–402.
- 10 Ahtari C, Hohlfeld P: Cardiotoxic transplacental effect of idarubicin administered during the second trimester of pregnancy. *Am J Obstet Gynecol* 2000;183:511–512.
- 11 Claahsen HL, Semmekrot BA, van Dongen PW, Mattijssen V: Successful fetal outcome after exposure to idarubicin and cytosine-arabioside during the second trimester of pregnancy. A case report. *Am J Perinatol* 1998;15:295–297.
- 12 Meyer-Wittkopf M, Barth H, Emons G, Schmidt S: Fetal cardiac effects of doxorubicin therapy for carcinoma of the breast during pregnancy: case report and review of the literature. *Ultrasound Obstet Gynecol* 2001;18:62–66.
- 13 Morishita S, Imai A, Kawabata I, Tamaya T: Acute myelogenous leukemia in pregnancy: fetal blood sampling and early effects of chemotherapy. *Int J Gynaecol Obstet* 1994;44:273–277.