


# Early Postoperative Detection of Tissue Necrosis in Amputation Stumps With Indocyanine Green Fluorescence Angiography

Vascular and Endovascular Surgery  
44(4) 269-273  
© The Author(s) 2010  
Reprints and permission:  
sagepub.com/journalsPermissions.nav  
DOI: 10.1177/1538574410362109  
http://ves.sagepub.com  


Alexander Zimmermann, MD,<sup>1</sup> Casper Roenneberg, MD,<sup>1</sup>  
Heiko Wendorff, MD,<sup>1</sup> Thomas Holzbach, MD,<sup>2</sup>  
Riccardo E. Giunta, MD,<sup>2</sup> and Hans-Henning Eckstein, MD<sup>1</sup>

## Abstract

**Objective:** Amputations of the lower extremity due to irreversible ischemic tissue loss are performed as distally as possible. Therefore, oftentimes wound-healing disorders develop, requiring additional surgical treatment. **Methods:** The amputations stumps of 10 patients with irreversible ischemic tissue loss due to arteriosclerosis were investigated within 72 hours postoperatively with indocyanine green (ICG) fluorescence. **Results:** For 6 of the investigated stumps, no perfusion deficit could be seen through fluorescence angiography. All stumps displayed primary healing. In the fluorescence angiography of 3 amputations, stump perfusions deficits predicted later tissue necrosis and had to be amputated again in a second operation. One amputation wound showed a small ICG perfusion deficit that represented a blood clot. **Conclusion:** Indocyanine green fluorescence angiography allows a perfusion analysis of amputation stumps and therefore a prediction of the expected tissue necrosis. This tool may allow reliable prediction of amputation level.

## Keywords

amputation, second-look surgery, arteriosclerosis, peripheral arterial occlusive disease, indocyanine green, fluorescence angiography

## Introduction

Due to a rising number of patients with risk factors for arteriosclerosis, such as tobacco consumption, diabetes, increased age, and hypercholesterolemia, peripheral arterial occlusive disease (PAOD) of the lower extremity requiring treatment is increasingly frequent.<sup>1,2</sup> Thus, severe or critical limb ischemia (CLI) is estimated to affect 50 to 100 per 100 000 individuals every year. Even though a revascularization is attempted in only about one half of these patients, the high morbidity and mortality of this disease result in high utilization of health-care and social-care resources.<sup>3</sup> The prognosis of this patient population is fatal; in one study, within one year after primary diagnosis of CLI about 25% had died, 25% were treated successfully, 20% were alive with a lingering CLI, and 30% were alive with an amputated lower extremity.<sup>3</sup> Due to the enormous advances in medical, surgical, and endovascular therapies, modern revascularization techniques led to a decrease in amputation rates while older techniques did not.<sup>4,5</sup>

Among diabetic patients in Germany, about 40 000 amputations are performed, half of which are major amputations. According to 1 study, half of the patients with a major amputation below the knee did not show any sign or symptom of an

ischemia of the lower extremity over the 6 months immediately prior to the study.<sup>6</sup> The rate of below- and above-the-knee amputations is nearly the same. The prognosis for patients amputated below the knee is even worse in comparison to patients with a CLI. Only 40% of these patients retain full mobility; 30% died, 15% receive a contralateral amputation, and 15% were amputated above the knee. This last point is due to the fact that only 60% of below-the-knee amputations will display primary wound healing. Of the remaining patients, 10% die perioperatively, 15% need an amputation above the knee and 15% exhibit delayed wound healing.<sup>3</sup>

<sup>1</sup> Clinic of Vascular Surgery, Klinikum rechts der Isar, Technische Universität München, Munich, Germany

<sup>2</sup> Department of Plastic Surgery and Hand Surgery, Klinikum rechts der Isar, Technische Universität München, Munich, Germany

## Corresponding Author:

Univ.-Prof. Dr. H.-H. Eckstein, Clinic of Vascular Surgery, Klinikum rechts der Isar der Technischen Universität München, Ismaninger Str. 22, 80538 Munich, Germany.

Email: hheckstein@web.de

As patients with CLI oftentimes have a multiplicity of comorbidities like coronary heart or cerebrovascular disease, additional needless operations should be avoided.<sup>7</sup> Therefore, it would be an improvement to predict the perfect amputation level, or rather the level of tissue necrosis expected soon after amputation. This issue was first explored with transcutaneous oxygen pressure (tcPO<sub>2</sub>) measurements. Nevertheless, findings in the literature are controversial.<sup>8,9</sup>

Indocyanine green (ICG) fluorescence angiography is used for tissue perfusion in a lot of different medical fields. Since the 1970s, ICG has been used for measuring retinal microcirculation<sup>10</sup>; today, it is also used in liver, cardiac, and plastic surgery.<sup>11-16</sup>

Because of this broad field of successful application areas, we tried for the first time to predict the degree of tissue necrosis after amputation due to CLI with ICG fluorescence angiography at an early postoperative time point.

## Patients and Methods

Indocyanine green is a water-soluble tricarbo-cyanine dye that binds to plasma proteins and globulins. Thus, it is confined to the intravascular space with minimal leakage from abnormal or fenestrated vessels. Elimination of ICG from the blood is only via the liver; as there is no entero-hepatic circulation, its half-life is approximately 3 minutes.

Indocyanine green has an absorption spectrum of 600 to 900 nm and can be activated by a near-infrared laser with a wavelength of 780 nm, providing a penetration of approximately 3 mm into tissue.<sup>11,17</sup> Thus, ICG localized in the subdermal microvasculature can be used as an index of tissue perfusion.

A total of 10 patients with a major limb amputation due to ischemic gangrene, with no possibility for revascularisation, were examined 72 hours postoperatively. Level of amputation (below the knee or above the knee) was ascertained by the vascular status determined by angiography. The lowest possible but reasonable level was chosen by consensus of at least 2 consultants of vascular surgery. The perfusion of the amputation stump was evaluated with laser-induced ICG-fluorescence angiography. The approval of the Medical Ethics Committee was obtained prior to the study. Patients with liver failure or history of allergic reactions to ICG or iodide were excluded from the study.

Each patient was injected intravenously with a single dose of 0.5 mg/kg ICG (ICG-Pulsion, Pulsion Medical Systems AG, Munich, Germany) using a peripheral venous line in the cubital fossa. The perfusion of amputation stumps was measured with the IC-View-System (Pulsion Medical Systems) consisting of a digital video camcorder and a near-infrared light. Measurements were made at a distance of 40 to 100 cm from the amputation stumps to be recorded. The recorded perfusion video was transferred to a computer and data analysis was performed with the aid of the IC-Calcs-Software (Pulsion Medical Systems). Perfusion was analyzed qualitatively in "perfusion" and "no-perfusion" conditions

**Table 1.** Demographic and Clinical Characteristics of the Study Population

Characteristic	n (%)
Median age	71 years
Male/Female	6/4 (60%/40%)
Smoking	5 (50%)
Diabetes	6 (60%)
Hypertension	10 (100%)
Hyperlipidemia	5 (50%)

and was correlated with postoperative results. The postoperative course of wound healing was classified as "primary healing" or "need for reoperation," according to the clinical findings.

## Results

From January 1, 2009 to June 30, 2009, 10 patients were evaluated with laser-induced ICG-fluorescence angiography. Demographic and clinical characteristics of this study population are reported in Table 1. Evaluation of stump perfusion by ICG angiography was possible in all cases. No side effects, such as hemodynamic instability, nausea, or allergic reactions occurred.

Of the 10 amputations, 3 were above knee level and showed no perfusion deficit ("perfusion") in the ICG angiography (Figure 1). All of them healed without any wound-healing disorder ("primary healing").

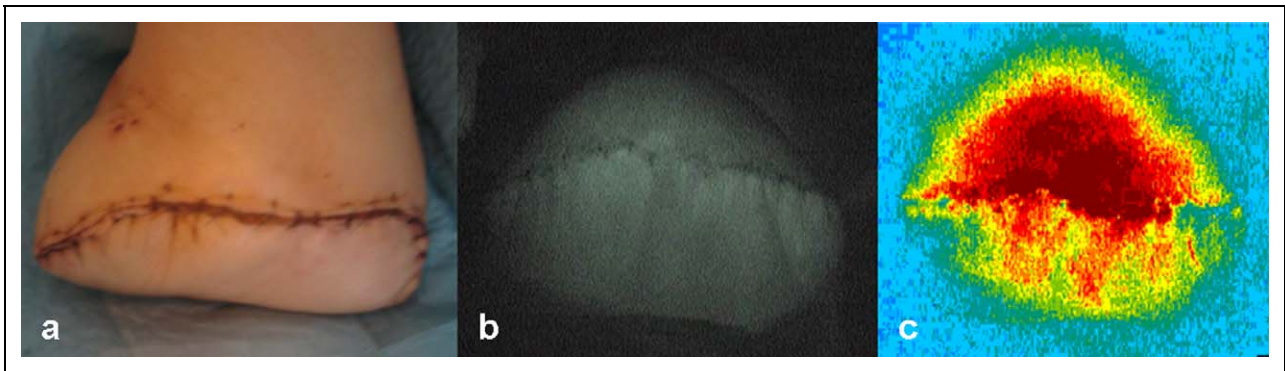
The remaining 7 amputations were below knee level. Three of these 7 amputations stumps similarly showed no ICG perfusion deficit ("perfusion") and healed without any abnormalities ("primary healing"). One stump presented with a small perfusion deficit of the fluorescence angiography ("no-perfusion") in the wound area, which represented a blood clot and not a dermal necrosis (Figure 2). However, healing took place uneventfully ("primary healing").

Three of the stumps had a substantial perfusion deficit ("no-perfusion") in the early postoperative ICG angiography. All 3 cases developed distinct wound-healing disorders and tissue necrosis and had to be amputated above the knee level in a second operation ("need for reoperation"). Afterward, there were no further complications in wound healing.

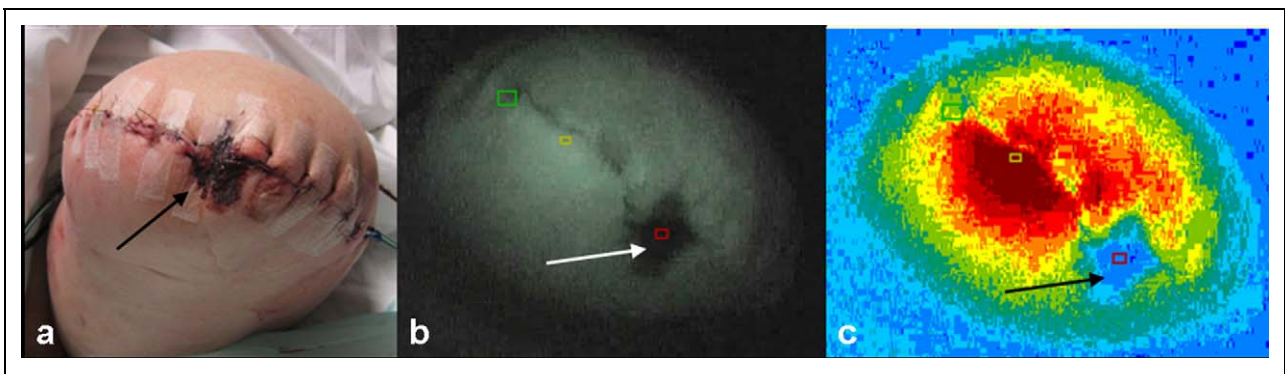
## Discussion

Evaluation of amputation level for patients with CLI is important. An amputation that is overly proximal would limit the opportunity for fast and functional prosthesis supply. However, an overly distal amputation may lead to a wound-healing disorder and a second operation or even re-amputation.<sup>9</sup> This is all the more important as these patients oftentimes face serious comorbidities.

Several attempts have been made to find a diagnostic method for predicting the most distal level of amputation possible, while avoiding the possibility of wound-healing disorders. The most promising technique appeared to be tcPO<sub>2</sub>



**Figure 1.** Early postoperative picture of an amputation stump (A) without any perfusion deficit in the indocyanine green (ICG) angiography (B) and subsequent primary wound healing. False color presentation of the ICG angiography.



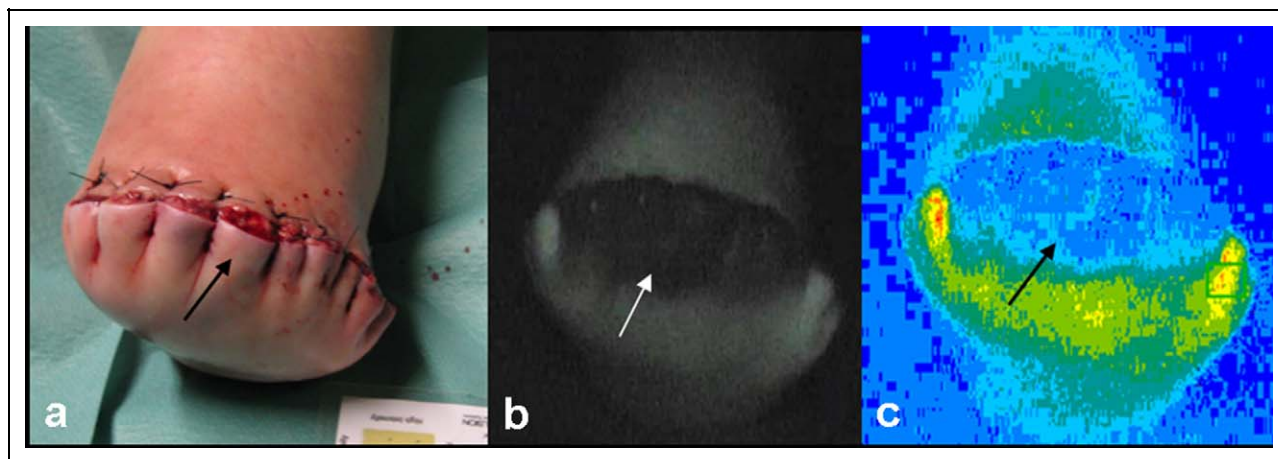
**Figure 2.** Early postoperative picture of an amputation stump (A) with a small perfusion deficit (arrow) in the indocyanine green (ICG) angiography (B) and subsequent primary wound healing. False color presentation of the ICG angiography.

measurement. The first studies investigating this technique reported on cut-off values, below which undisturbed wound healing in amputations could not take place. Subsequent articles could not confirm these results and the benefit of  $tcPO_2$  measurement for amputation level determination was disputed.<sup>8,9</sup> Another approach is contrast-enhanced ultrasound (CEU), which has promise as an index of tissue perfusion. Even the degree of vascular collateralization seems to be illustrated by CEU.<sup>18-20</sup>

To date, no valid techniques for routine use in the clinic have been established for determination of tissue perfusion. Ankle-brachial pressure index (ABI) has been, historically, one of the most significant markers for the severity of PAOD that can be applied with a high diagnostic value and at low cost. However, the impact of collateralization on tissue perfusion is not considered in the ABI, and local perfusion changes cannot be displayed.

Indocyanine green fluorescence angiography is repeatedly reported to provide an accurate assessment of tissue perfusion. It has been used for years to measure liver blood flow, cardiac output, and for ophthalmic angiography.<sup>21-23</sup> Furthermore, a series of successful studies of ICG angiography have been reported for evaluation of flap perfusion and as a predictor of flap necrosis.<sup>11,15-17</sup>

Due to these encouraging results, we tried to use this technique for evaluation of early postoperative amputation stump perfusion. Primary wound healing was achieved in all above-the-knee amputations. This was predicted for all cases by the ICG angiography, as no perfusion deficit was observed (Figure 1). Likewise, all wound-healing disorders in below-the-knee amputations could be predicted with this technique. In the early postoperative period, invisible and visible tissue perfusion disorders could be detected by ICG perfusion gaps (Figure 3). Depending on the extend of these ICG perfusion gaps, the surgeon can decide whether an amputation to a higher level is required or an attempt of reamputation at the same level is possible. One particularity in ICG angiography is shown in Figure 2. The marked ICG gap (white arrow) is not caused by a tissue perfusion deficit but rather by a blood clot as the near-infrared laser (780 nm) provides maximal penetration of light into the tissue of approximately 3 mm.<sup>11,17</sup> In contrast, the strip plaster did not interfere with angiography quality. Therefore, the wound and the surrounding skin should be cleaned to obtain the best possible outcome. The limited penetration depth seems to be one of the limitations of this technique, as deeper perfusion conditions cannot be determined. However, skin perfusion serves as a kind of indicator for PAOD, because necrosis or ulcerations occur first at the skin level. In addition changes



**Figure 3.** Early postoperative picture of an amputation stump (A) with a large perfusion deficit (arrow) in the indocyanine green (ICG) angiography (B), subsequent wound-healing disorder and the need for secondary amputation. False color presentation of the ICG angiography.

in tissue perfusion due to a higher or lower cardiac output can result in different ICG angiography findings, whereas a better blood oxygenation, for example caused by a supplementation oxygen delivery, does not.

In this limited study, it was possible to develop a prediction tool for amputation stump wound-healing disorders and necrosis during the early postoperative period. This technique needs further evaluation but seems to be promising with regard to predicting amputation levels. In this study, the best point of time for postoperative ICG angiography seemed to be on the first day after amputation, as the dimension of perfusion changes of the skin can already be evaluated. However in the future, ICG angiography should be evaluated intraoperatively to determine whether perfusion deficits can be seen at this early time point, as was observed in the context of plastic surgery for flap viability.<sup>17</sup> If this is feasible, amputation levels could be selected to be as distal as possible and can be adjusted during the same operation. This would determine the ideal amputation level, as in every case the approach would continue until no perfusion deficit could be seen. Therefore, a high chance for primary wound healing can be obtained without losing any healthy tissue. While in this study the presented method was only used for quality measurements, ICG angiography can also provide a numerical quantification.<sup>11</sup> This could allow a preoperative determination of the correct amputation level but will require further research.

#### Acknowledgment

The authors would like to thank Dr Oliver Goedje MD, PhD, FCCP, representative of Pulsion Medical Systems AG, Munich, Germany, for his support of our research project.

#### Declaration of Conflicting Interests

The authors declared no conflicts of interest with respect to the authorship and/or publication of this article.

#### Funding

The authors received no financial support for the research and/or authorship of this article.

#### Reference

1. Burns P, Gough S, Bradbury AW. Management of peripheral arterial disease in primary care. *BMJ*. 2003;326(7389):584-588.
2. Zimmermann A, Reeps C, Hartl F, Ockert S, Eckstein HH. The diabetic foot. *Chirurg*. 2009;80(5):430-436.
3. Norgren L, Hiatt WR, Dormandy JA, Nehler MR, Harris KA, Fowkes FG. Inter-society consensus for the management of peripheral arterial disease (TASC II). *J Vasc Surg*. 2007;45(suppl S):S5-S67.
4. Adam DJ, Beard JD, Cleveland T, et al. Bypass versus angioplasty in severe ischaemia of the leg (BASIL): multicentre, randomised controlled trial. *Lancet*. 2005;366(9501):1925-1934.
5. Tunis SR, Bass EB, Steinberg EP. The use of angioplasty, bypass surgery, and amputation in the management of peripheral vascular disease. *N Engl J Med*. 1991;325(8):556-562.
6. Dormandy J, Belcher G, Broos P, et al. Prospective study of 713 below-knee amputations for ischaemia and the effect of a prostacyclin analogue on healing. Hawaii Study Group. *Br J Surg*. 1994; 81(1):33-37.
7. Bhatt DL, Steg PG, Ohman EM, et al. International prevalence, recognition, and treatment of cardiovascular risk factors in outpatients with atherothrombosis. *JAMA*. 2006;295(2):180-189.
8. Keyzer-Dekker CM, Moerman E, Leijdekkers VJ, Vahl AC. Can transcutaneous oxygen tension measurement determine re-amputation levels? *J Wound Care*. 2006;15(1):27-30.
9. Poredos P, Rakovec S, Guzic-Salobir B. Determination of amputation level in ischaemic limbs using tcPO<sub>2</sub> measurement. *Vasa*. 2005;34(2):108-112.
10. Flower RW. Injection technique for indocyanine green and sodium fluorescein dye angiography of the eye. *Invest Ophthalmol*. 1973;12(12):881-895.

11. Giunta RE, Holzbach T, Taskov C, et al. Prediction of flap necrosis with laser induced indocyanine green fluorescence in a rat model. *Br J Plast Surg.* 2005;58(5):695-701.
12. Iijima T, Aoyagi T, Iwao Y, et al. Cardiac output and circulating blood volume analysis by pulse dye-densitometry. *J Clin Monit.* 1997;13(2):81-89.
13. Lamby P, Prantl L, Gais S, et al. Evaluation of the vascular integrity of free flaps based on microcirculation imaging techniques. *Clin Hemorheol Microcirc.* 2008;39(1-4):253-263.
14. Okochi O, Kaneko T, Sugimoto H, Inoue S, Takeda S, Nakao A. ICG pulse spectrophotometry for perioperative liver function in hepatectomy. *J Surg Res.* 2002;103(1):109-113.
15. Prantl L, Schmitt S, Geis S, et al. Contrast harmonic ultrasound and indocyanine-green fluorescence video angiography for evaluation of dermal and subdermal microcirculation in free parascapular flaps. *Clin Hemorheol Microcirc.* 2008;38(2):105-118.
16. Prantl L, Schmitt S, Gais S, et al. Contrast harmonic ultrasound and indocyanine-green fluorescence video angiography for evaluation of dermal and subdermal microcirculation in free parascapular flaps. *Clin Hemorheol Microcirc.* 2008;38(1):31-44.
17. Holm C, Mayr M, Hofter E, Becker A, Pfeiffer UJ, Muhlbauer W. Intraoperative evaluation of skin-flap viability using laser-induced fluorescence of indocyanine green. *Br J Plast Surg.* 2002;55(8):635-644.
18. Duerschmied D, Olson L, Olschewski M, et al. Contrast ultrasound perfusion imaging of lower extremities in peripheral arterial disease: a novel diagnostic method. *Eur Heart J.* 2006;27(3):310-315.
19. Duerschmied D, Zhou Q, Rink E, et al. Simplified contrast ultrasound accurately reveals muscle perfusion deficits and reflects collateralization in PAD. *Atherosclerosis.* 2009;202(2):505-512.
20. Prantl L, Schreml S, Walter M, et al. Evaluation of microcirculation of free flaps of the lower leg by contrast harmonic imaging (CHI) with time intensity curve (TIC) analysis. *Clin Hemorheol Microcirc.* 2008;39(1-4):343-350.
21. FOX IJ, EH WOOD. Applications of dilution curves recorded from the right side of the heart or venous circulation with the aid of a new indicator dye. *Proc Staff Meet Mayo Clin.* 1957;32(19):541-550.
22. Mandell MS, Wachs M, Niemann CU, Henthorn TK. Elimination of indocyanine green in the perioperative evaluation of donor liver function. *Anesth Analg.* 2002;95(5):1182-1184, table.
23. Kogure K, David NJ, Yamanouchi U, Choromokos E. Infrared absorption angiography of the fundus circulation. *Arch Ophthalmol.* 1970;83(2):209-214.