

## CARDIOVASCULAR FLASHLIGHT

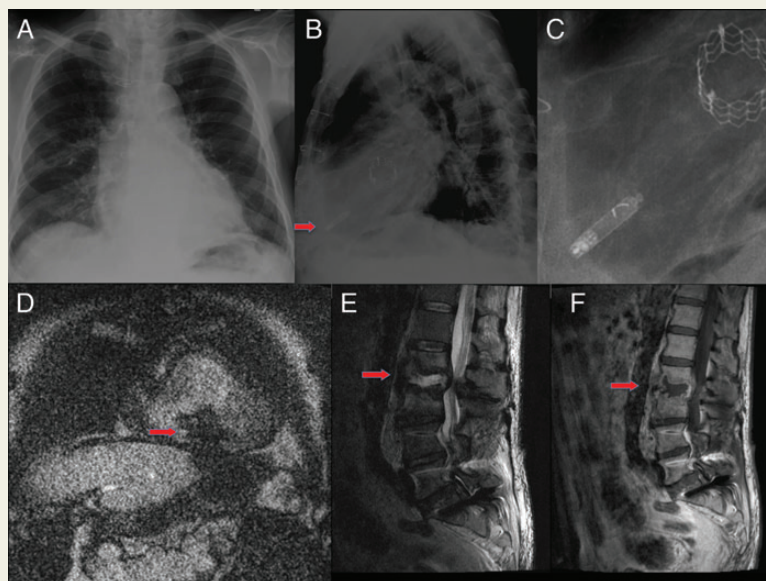
doi:10.1093/eurheartj/ehv360  
Online publish-ahead-of-print 10 August 2015**Magnetic resonance imaging at 1.5-T in a patient with implantable leadless pacemaker**Romy Ubrich<sup>1</sup>, Kornelia Kreiser<sup>2</sup>, Daniel Sinnecker<sup>1</sup>, and Simon Schneider<sup>1\*</sup><sup>1</sup>Medizinische Klinik und Poliklinik I, Klinikum rechts der Isar, Technische Universität München, Ismaninger Str.22, Munich 81675, Germany; and <sup>2</sup>Abteilung für Neuroradiologie, Klinikum rechts der Isar, Technische Universität München, Ismaninger Str.22, Munich 81675, Germany\*Corresponding author. Tel: +49 89 4140 2947, Fax: +49 89 4140 4901, Email: [simon-schneider@tum.de](mailto:simon-schneider@tum.de)

Here we report the case of a 67-year-old man who presented to the emergency department with back-pain and paralysis. Magnetic resonance imaging (MRI) of the spine was indicated to evaluate further treatment. Twelve months before, the patient had a leadless pacemaker (St Jude Medical S1DLCP, VVI00) implanted because of bradycardiac atrial fibrillation (*Panels A and B*). At the time of presentation, heart rate upon inhibition of the pacemaker was 52 min.

After weighing potential risks and benefits, MRI was performed under continuous patient monitoring with electrocardiography and pulse oximetry (*Panel D*). A 1.5 Tesla scanner was used with a maximal specific absorption rate of 1.55 W/kg averaged over 10 s. The device was programmed to V00 mode (basic rate 75 bpm, maximized output of 5.00 V, pulse duration 1.0 ms).

No clinical adverse events occurred during the MRI and a follow-up of 15 days. The pacemaker was tested just before the MRI, immediately afterwards and after 15 days. Lead impedance and pacing threshold were stable at 340–360  $\Omega$  and 0.5 mV, respectively. Battery voltage was stable (initially >3.30 V, 3.29 V after 15 days). There was a slight decrease in R wave sensing from initially 9.5 to 9.0 mV immediately after MRI and 8.5 mV after 15 days (a reduction of <10%). A chest X-ray showed no signs of device dislodgement (*Panel C*). MR-imaging revealed vertebral discitis (L2/3) (*Panels E and F*) resulted in the treatment decision to surgical intervention.

To our knowledge, this is the first report of a patient with leadless pacing system who safely underwent MRI.



Published on behalf of the European Society of Cardiology. All rights reserved. © The Author 2015. For permissions please email: [journals.permissions@oup.com](mailto:journals.permissions@oup.com).