

Preoperative motor mapping by navigated transcranial magnetic brain stimulation improves outcome for motor eloquent lesions

Sandro M. Krieg, Jamil Sabih, Lucia Bulubasova, Thomas Obermueller, Chiara Negwer, Insa Janssen, Ehab Shiban, Bernhard Meyer, and Florian Ringel

Department of Neurosurgery (S.M.K., J.S., L.B., T.O., C.N., I.J., E.S., B.M., F.R.); TUM-Neuroimaging Center, Klinikum rechts der Isar, TU München, Germany (S.M.K., J.S., L.B., T.O.)

Corresponding Author: Sandro M. Krieg, MD, Department of Neurosurgery, Klinikum rechts der Isar, Technische Universität München, Ismaninger Str. 22, 81675 Munich, Germany (sandro.krieg@lrz.tum.de).

Ethics committee registration number: 2793/10

Background. Navigated transcranial magnetic stimulation (nTMS) has been proven to influence surgical indication and planning. Yet there is still no clear evidence how these additional preoperative functional data influence the clinical course and outcome. Thus, this study aimed to compare patients with motor eloquently located supratentorial lesions investigated with or without preoperative nTMS in terms of clinical outcome parameters.

Methods. A prospectively enrolled cohort of 100 patients with supratentorial lesions located in motor eloquent areas was investigated by preoperative nTMS (2010–2013) and matched with a control of 100 patients who were operated on without nTMS data (2006–2010) by a matched pair analysis.

Results. Patients in the nTMS group showed a significantly lower rate of residual tumor on postoperative MRI (OR 0.3828; 95% CI 0.2062–0.7107). Twelve percent of patients in the nTMS and 1% of patients in the non-nTMS group improved while 75% and 81% of the nTMS and non-nTMS groups, respectively, remained unchanged and 13% and 18% of patients in the nTMS and non-nTMS groups, respectively, deteriorated in postoperative motor function on long-term follow-up ($P = .0057$). Moreover, the nTMS group showed smaller craniotomies (nTMS 22.4 ± 8.3 cm²; non-nTMS 26.7 ± 11.3 cm²; $P = .0023$).

Conclusions. This work increases the level of evidence for preoperative motor mapping by nTMS for rolandic lesions in a group comparison study. We therefore strongly advocate nTMS to become increasingly used for these lesions. However, a randomized trial on the comparison with the gold standard of intraoperative mapping seems mandatory.

Keywords: brain tumor, matched pair, preoperative mapping, rolandic region, transcranial magnetic stimulation.

In surgical neurooncology the extent of resection (EOR) correlates directly with survival for most supratentorial tumors and therefore has to be the surgical aim in most patients.^{1–3} Yet, resection of motor eloquently located lesions remains a challenge in neurosurgery as it can only be safely achieved through a multimodal setup including neuronavigation and intraoperative neuromonitoring. While continuous motor evoked potential (MEP) monitoring and subcortical electrical stimulation are well-established techniques to monitor functional integrity of the motor strip and corticospinal tract, navigated transcranial magnetic brain stimulation (nTMS) was recently shown to functionally identify the motor cortex prior to surgery.^{4,5} It was also shown to be superior to other non-invasive techniques, such as functional magnetic resonance imaging (fMRI) and

magnetoencephalography (MEG).^{5,6} Moreover, it was repeatedly shown that nTMS correlates well with intraoperative direct cortical stimulation (DCS) and is a highly valuable tool for surgical planning.^{4,5}

Yet, although its influence on surgical indication, planning, and approach was proven and examined in two previous studies, there is still no clear evidence how the preoperative availability of these additional functional data actually influences the clinical course and outcome of our patients.

Thus, this study aimed to compare a prospectively enrolled cohort of patients with motor eloquently located supratentorial lesions investigated by preoperative nTMS with a historic control group who were operated on without nTMS data by a matched pair analysis.

Received 20 November 2013; accepted 11 January 2014

© The Author(s) 2014. Published by Oxford University Press on behalf of the Society for Neuro-Oncology. All rights reserved.

For permissions, please e-mail: journals.permissions@oup.com.

Materials and methods

Patients

Topographic association between tumor and rolandic cortex and therefore indication for nTMS and intraoperative neuromonitoring (IOM) was assessed by magnetic resonance imaging (MRI) for all patients. Between 2010 and 2013 100 consecutive patients with motor eloquently located supratentorial lesions underwent craniotomy in our department after receiving nTMS motor mapping. Moreover, this prospectively enrolled cohort was match with a historic control operated on from 2006 to 2010 in our department with the same distribution of tumor types. Matching was performed for tumor location, preoperative paresis, and histology out of a cohort of 218 patients. The characteristics of both groups are outlined in Table 1. Data analysis was performed blinded to the assigned group.

Mean follow-up in terms of clinical evaluation in the outpatient department was 9.4 ± 8.7 months (median 7.1 months, range 0.2–27.2 months) in the nTMS and 16.0 ± 20.9 months (median 6.2 months, range 0.1–79.4 months) in the non-nTMS group.

Clinical assessment

All patients were evaluated for muscle strength, coordination, sensory function, and cranial nerve function according to a standardized protocol that was established 2006 in our department. Clinical assessment was performed blinded to the nTMS data. After surgery, neurological status was routinely assessed after awakening from anesthesia and daily from the first postoperative day until discharge, again at 6–8 weeks postoperatively, and during follow-ups on a regular basis every 3–12 months depending on tumor type. Any new surgery-related paresis was

differentiated between permanent and temporary. A new permanent paresis was defined as a new or aggravated paresis due to surgery that did not return to the preoperative status during follow-up. A temporary paresis was defined as a new or aggravated postoperative paresis, which disappeared at least during the regular 8-week follow-up interval. However, every patient who presented with a new paresis directly after anesthesia underwent a postoperative computed tomography (CT) scan to exclude secondary hemorrhage.

Ethical standard

The study is in accordance with ethical standards of the Declaration of Helsinki and was approved by the local institutional review board (registration number: 2793/10). Informed consent was obtained prior to every nTMS examination.

Magnetic resonance imaging

Pre- and postoperative MRI scans were performed on all patients using a 3 Tesla MR scanner in combination with an 8-channel phased array head coil (Achieva 3T, Philips Medical Systems, The Netherlands B.V.) for contrast-enhanced 3D gradient echo sequence, T2 FLAIR, and diffusion tensor imaging (DTI). The contrast-enhanced 3D gradient echo sequence dataset was transferred to the nTMS system (eXimia 3.2 and eXimia 4.3, Nexstim Oy, Helsinki, Finland). Each patient also underwent a MRI scan the day after surgery to evaluate the EOR, including T1 sequences with and without contrast enhancement, T2 FLAIR, and diffusion-weighted imaging (DWI) to detect any postoperative ischemic events. During follow-up, MRI scans were also performed on a regular basis every 3–12 months depending on tumor entity and current oncological therapy. Follow-up MRI scans were reviewed for recurrent tumors because the neurological status during follow-up was only considered during progression-free survival.

For final analysis, all MRI scans performed in our center are evaluated in an imaging meeting including board certified neuroradiologists and neurosurgeons.

For this study, we also analyzed the extent of craniotomy by postoperative MRI or CT scans in all 200 patients in order to achieve the most exact data. Since all craniotomies are performed rectangular (parallel to the sagittal suture) in our department, we measured anterior-posterior (ap) and lateral direction as well as the area of the craniotomy as the product of both values.

Navigated transcranial magnetic stimulation

Transcranial magnetic stimulation (TMS) is used since 1985 to elicit MEP, especially in the neurological diagnostic routine, by inducing an electric field within the motor cortex, which causes neuronal depolarization and therefore an action potential.⁷ This action potential is then transmitted to the muscles and can be measured as MEP. In the last years we are now also able to navigate the TMS coil and therefore its site of cortical stimulation.⁸ For visualization of the stimulated cortical spots, a 3D gradient echo sequence is used. The applied nTMS systems (eXimia 3.2 and eXimia 4.3, Nexstim Oy, Helsinki, Finland) both used a biphasic figure-8 TMS coil with a 50 mm radius as the magnetic stimulator,

Table 1. Patient data

	nTMS	non-nTMS	P value
age	53.1 ± 15.7	55.5 ± 17.1	$P = .3025$
gender			$P = .3809$
male	59%	66%	
female	41%	34%	
preoperative paresis			$P = .2710$
none	66%	73%	
mild	24%	15%	
severe	10%	12%	
Histology			$P = .9996$
astrocytoma II	17%	15%	
astrocytoma III	12%	14%	
glioblastoma	37%	37%	
metastasis	24%	24%	
AVM	3%	3%	
cavernoma	3%	3%	
other	4%	4%	

Detailed overview on age, gender, preoperative neurological status, and histology of the nTMS compared to the non-nTMS group. Preoperative paresis: none = no paresis, mild = BMRC grade of muscle strength $\geq 4/5$, severe = BMRC grade of muscle strength $\leq 3/5$, histology: AVM = arteriovenous malformation.

which is attached to an infrared tracking system (Polaris Spectra, Waterloo, Ontario, Canada) as reported earlier.^{4,5,9} One day prior to surgery, all enrolled patients of the nTMS group underwent primary motor cortex mapping by a protocol described previously by an examiner with high experience in nTMS.^{5,9} Briefly, resting motor threshold (rMT) was determined and mapping was performed using 110% rMT for the upper extremity and 130% for the lower extremity.⁵ The mapping was started at the lateral part of the hand knob and was performed in 3–5 mm steps perpendicular to the sulci until stimulation did not elicit any further MEP in any direction. All cortical spots at which a MEP was evoked were evaluated as positive motor mapping points representing the cortical representation of the mapped muscles.

Positive motor mapping points were then exported from the nTMS system via the DICOM standard.

nTMS data within intraoperative neuronavigation

During surgery, neuronavigation was used (Vector Vision 2[®], Vector Vision Sky[®], or Curve; BrainLAB AG, Feldkirchen, Germany) in both groups. In the nTMS group, the motor cortex as outlined by nTMS was visualized by the neuronavigation system. To achieve this, the nTMS motor areas were exported as DICOM files by the nTMS system and imported to the neuronavigation planning unit (BrainLAB iPlan[®] Net Cranial 3.0.1; BrainLAB AG, Feldkirchen, Germany). The data set of nTMS-positive motor areas was fused to a continuous sagittal image set of a T1-weighted 3D gradient echo sequence as well as T2 FLAIR, and positron emission tomography (PET) if necessary. After fusion the nTMS-positive motor areas were then defined as objects by simple auto segmentation and available as 3D objects within the intraoperative neuronavigation as described earlier.¹⁰ The additional implementation of nTMS data into the neuronavigation planning took about 2–5 min per patient.

Figure 1 illustrates the visualization of preoperative nTMS mapping data and its intraoperative use by the neuronavigation system.

Surgical technique

All 200 lesions were resected by monopolar direct cortical stimulation for monitoring of MEPs as IOM as described in earlier reports.^{11,12} Surgical technique did not vary between groups.

Statistical analysis

For testing the distribution of several attributes, a Chi-square or Fisher Exact test was performed. Differences between the 2 groups were tested using the Mann-Whitney-Wilcoxon test for multiple comparisons on ranks for independent samples for non-parametric and *t*-test for parametric distribution. All results are presented as mean ± standard deviation (SD) and as odds ratios (OR) with 95% confidence intervals (CI) (GraphPad Prism 5.0c, La Jolla, CA, USA). The level of significance was 0.05 (two-sided) for each statistical test.

Role of the funding source

The study was completely financed by institutional grants through the Department of Neurosurgery. The corresponding

author has full access to all the data in the study and has final responsibility for the decision to submit for publication.

Results

Preoperative nTMS mapping

Preoperative mapping of the primary motor cortex was performed in all 100 consecutive patients of the nTMS group. There were no patients who were not able to perform nTMS. The mean rMT was $34.5\% \pm 9.3\%$ maximum stimulator output. All 100 patients were asked about their experience of nTMS: 6 patients described their experience of nTMS mapping as unpleasant, and no patient found it painful.

Influence on surgery

Craniotomy size

Craniotomy extension in the ap direction for nTMS was 4.9 ± 0.9 cm (median 5.0 cm, range 3.0–7.6 cm) and 5.4 ± 1.5 cm (median 5.0 cm, range 1.0–10.6 cm) for non-TMS patients ($P = .0023$; Fig. 2A). Lateral craniotomy extension was 4.5 ± 1.1 cm (median 4.0 cm, range 3.0–9.0 cm) for the nTMS and 4.8 ± 1.1 cm (median 4.0 cm, range 1.0–8.0 cm) for the non-TMS group ($P = .0471$; Fig. 2B). Overall size of the bone flap was 22.4 ± 8.3 cm² (median 20.0 cm², range 9.0–54.0 cm²) for the nTMS and 26.7 ± 11.3 cm² (median 25.0 cm², range 4.0–64.0 cm²) for the non-TMS group ($P = .0023$; Fig. 2C).

Duration of surgery

Duration of surgery was 196.2 ± 57.5 min (median 196.0 min, range 67.0–403.0 min) for nTMS and 189.4 ± 59.8 min (median 177.5 min, range 72.0–401.0 min) for non-nTMS patients ($P = .4134$).

General motor outcome

Sixteen patients (16%) in the nTMS group and 15 patients (15%) in the non-nTMS group suffered from a new surgery-related transient paresis with no statistically significant difference (OR 1.079; CI 0.5016–2.323). Moreover, 13 patients (13%) in the nTMS group and 18 patients (18%) in the non-nTMS group suffered from a new permanent paresis on long-term follow-up (OR 0.6807; CI 0.3137–1.477).

When also including neurological improvement in the analysis, 12 patients (12%) in the nTMS group and 1 patient (1%) in the non-nTMS group improved while 75 patients (75%) in the nTMS group and 81 patients (81%) in the non-nTMS group remained unchanged and 13 patients (13%) in the nTMS group and 18 patients (18%) in the non-nTMS group presented with decreased postoperative motor function on long-term follow-up ($P = .0057$; Fig. 3).

Permanent surgery-related deficit depending on preoperative paresis

Regarding the rate of preoperative pareses and their effect on outcome, we found 34 patients (34%) with preoperative paresis in the nTMS and 27 patients (27%) in the non-nTMS group. On long-term

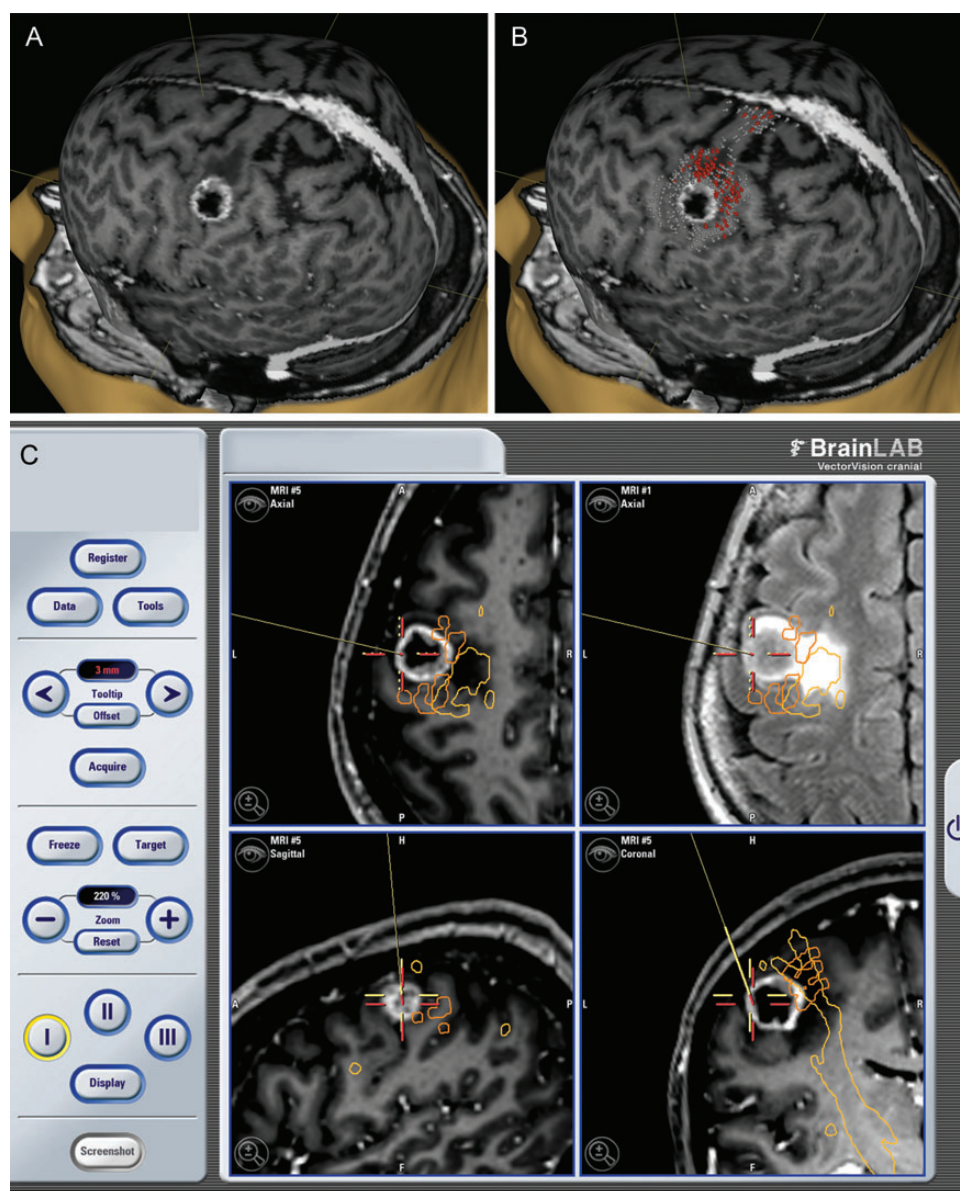


Fig. 1. Illustration of nTMS data within the neuronavigation. These MRI reconstructions show a glioblastoma WHO grade 4 within the hand knob of the left primary motor cortex. The preoperative 3D reconstructions show the tumor location without (A) and with nTMS data (B). Grey = mapped cortical regions with negative MEP answers; red = positive MEP answers representing the functional motor cortex of this patient. The intraoperative screenshot (C) illustrates how preoperative nTMS mapping data for the functional motor cortex is implemented in the neuronavigation system in order to provide optimum visualization for the surgeon during surgery. The pointer (red cross) is at the tumor. Orange = nTMS data for the motor cortex (analogue to the red areas in B); yellow = corticospinal tract visualized by DTI fibre tracking.

follow-up, 4 patients (11.8%) in the nTMS group with preoperative paresis deteriorated, compared to 9 patients (13.6%) without preoperative paresis. Eighteen patients (52.9%) with paresis and 57 patients (86.4%) without paresis remained unchanged and 12 patients (35.3%) with preoperative paresis showed improved motor function on long-term follow-up ($P < .0001$).

Concerning long-term follow-up of the non-nTMS group, there was no significant correlation between preoperative and new paresis. Two patients (7.4%) with preoperative paresis deteriorated, compared to 16 patients (21.9%) without preoperative paresis.

Twenty-four patients (88.9%) with and 57 patients (78.1%) without preoperative paresis remained unchanged and 1 patient (3.7%) with preoperative paresis showed improved motor function on long-term follow-up ($P = .0709$; Fig. 4).

Permanent surgery-related deficit depending on tumor type or location

Tumor type was not associated with a higher rate of permanently new paresis per se ($P = .2199$). At both groups, there was also no

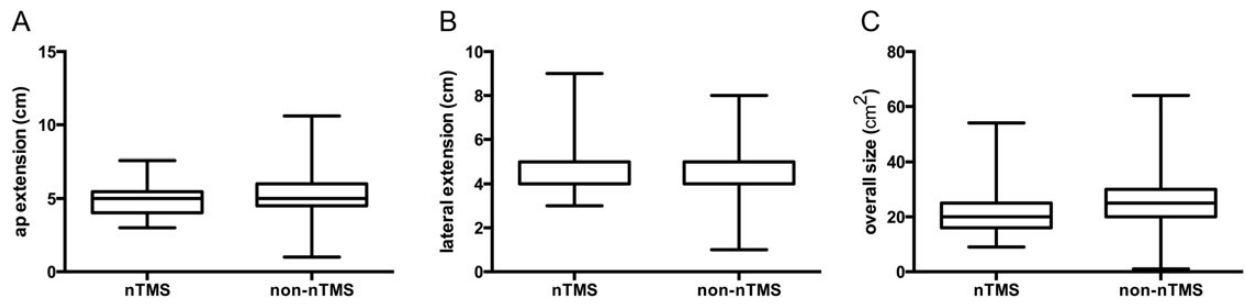


Fig. 2. Size of craniotomy. Boxplot of craniotomy extension for the nTMS compared to the non-nTMS group with median, min- and max-whiskers, and quartile-boxes for the anterior-posterior direction (A), lateral direction (B), and overall size of the craniotomy (C).

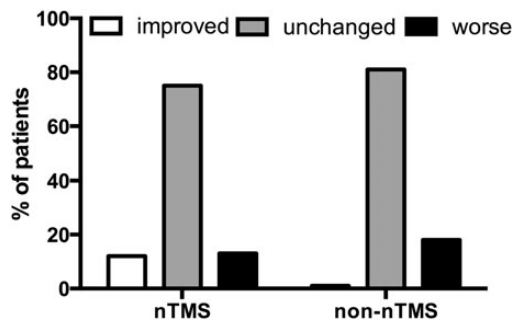


Fig. 3. General motor outcome. Bar chart comparing the percentage of patients who had been afflicted with a transient paresis to the percentage of patients who developed a new permanent paresis on long-term follow-up for the nTMS group in comparison to the non-nTMS group.

significant relationship in either the nTMS ($P = .0509$) or in the non-nTMS group ($P = .1747$; Fig. 5). Tumor location, even within the precentral gyrus, was not associated with a higher rate of permanently new paresis in the nTMS ($P = .9237$) and non-TMS group ($P = .7022$; Fig. 6).

Residual tumor, extent of resection, and permanent surgery-related deficit

The nTMS group showed a significantly lower rate of residual tumor. Twenty-two patients (22%) in the nTMS group and 42 patients (42.4%) in the non-nTMS group had residual tumor tissue on postoperative MRI scans (OR 0.3828; CI 0.2062–0.7107). Unexpected residual was observed in 9 patients (9%) in the nTMS group and 32 patients (32.3%) in the non-nTMS group on postoperative MRI scans (OR 0.2071; CI 0.09265–0.4628). However, concerning EOR and its relation to surgery-related permanent paresis, there was no significant difference in either groups (nTMS: OR 1.035; CI 0.2052–5.221; non-nTMS: OR 2.143; CI 0.4966–9.246; Table 2).

Discussion

In neurosurgery it is very difficult to provide a sufficient degree of evidence for technical advances. Besides studies on 5-aminolevulinic acid, DCS, and intraoperative MRI, this is another study actually providing evidence for the usefulness of a new technique in surgical neurooncology.^{13–15}

Preoperative identification of motor areas by nTMS was reported to be helpful in surgical planning for motor eloquent tumors.^{5,16} Nonetheless, clear data on the actual influence of nTMS motor mapping on the clinical outcome were not available up to now. Thus, this study was performed to increase the level of evidence for this new technique, which might have a severe impact on neurosurgery in the future.

Surgery-related pareses

The central finding of the present study is that nTMS actually lowers the risk for surgery-related paresis ($P = .0057$; Fig. 3). Yet, mean follow-up was different in both groups due to the earlier date of surgery in the non-nTMS group. However, follow-up of the nTMS group is still long enough to exclude further motor recovery and finally define these pareses as permanent. Thus, this difference does not bias our results.

Apart from the study of Duffau et al. on the impact of IOM for glioma resection, this is only the second study proving that an additional *neurophysiological* technique reduces deficit rates in patients with motor eloquent lesions.¹⁴

The comparably high rate of new surgery-related pareses in both groups must be attributed to the strict rules of our data analysis. Even slight changes in motor function were evaluated as surgery-related paresis.

Craniotomy

Navigated TMS might reduce the required size of craniotomy most likely due to the absent necessity to perform extensive intraoperative mapping when the motor cortex is already outlined on the neuronavigation. Thus, the surgeon can just confirm nTMS data by circumscribed DCS mapping but does not have to do a large craniotomy exposing the whole brain area where the surgeon suspects the motor cortex to be.⁵

However, when regarding the small mean difference of both groups it might not be clinically relevant, but when regarding the range of both groups, a difference is 3 cm and the difference for the overall size is 10 cm². Thus, this difference might only be relevant in selected cases.

Residual tumor

The nTMS group showed a significantly lower rate of residual tumor on postoperative MRI and therefore a higher rate of gross total resection (GTR). This is somehow surprising as we considered the

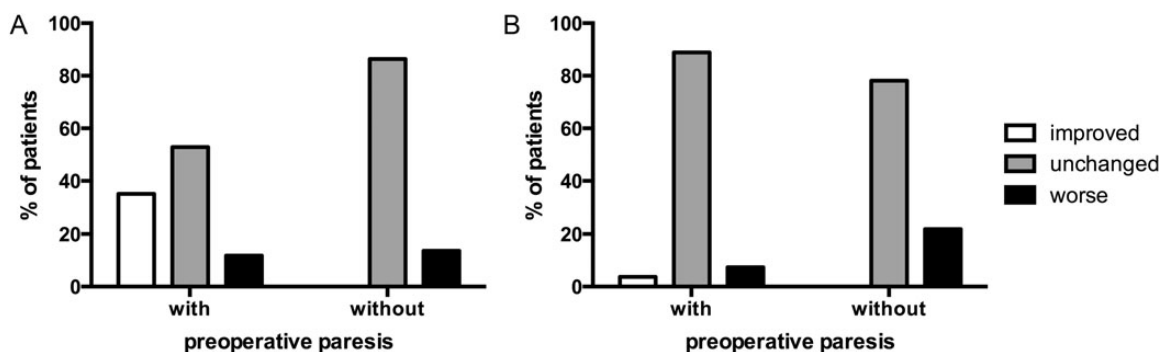


Fig. 4. Permanent surgery-related deficit depending on preoperative paresis. Bar chart comparing the percentage of patients with and without a preoperative paresis in both the nTMS (A) and the non-nTMS group (B), which can be improved, unchanged, or deteriorated on long-term follow-up compared to the preoperative state.

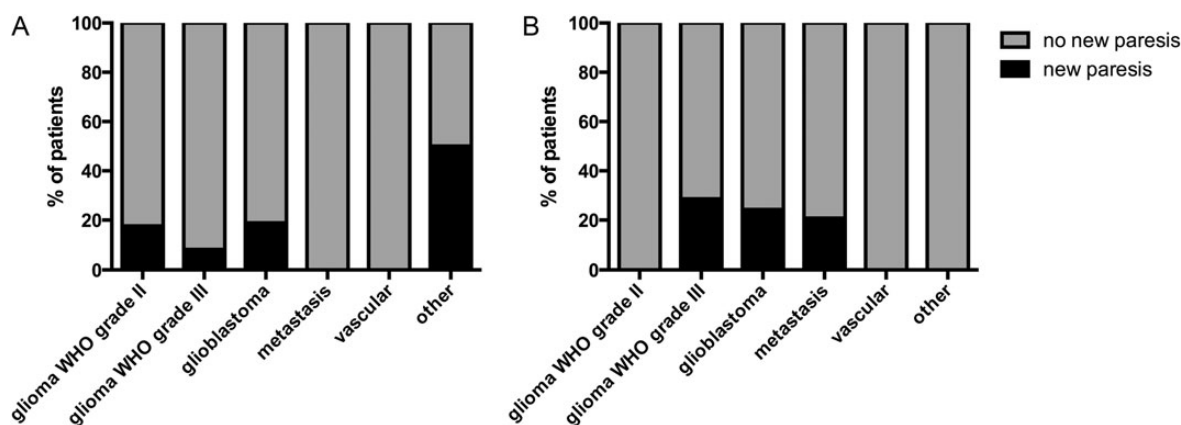


Fig. 5. Permanent surgery-related deficit depending on lesion type. Bar chart comparing the percentage of patients with a new paresis to the percentage of patients with no new paresis on long-term follow-up for both the nTMS (A) and non-nTMS (B), with each bar illustrating a specific lesion type.

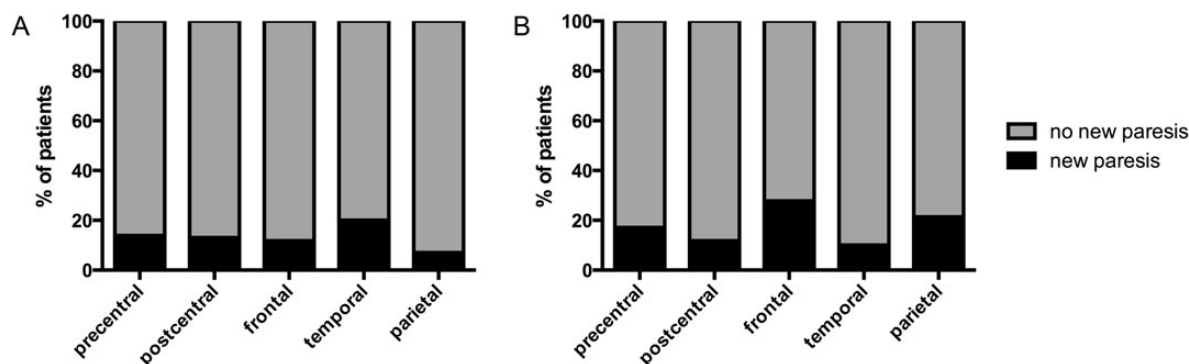


Fig. 6. Permanent surgery-related deficit depending on lesion location. Bar chart comparing the percentage of patients with a new paresis to the percentage of patients with no new paresis on long-term follow-up for both the nTMS (A) and non-nTMS (B), with each bar illustrating a specific lesion location.

continuous visualization of the motor eloquent cortex on the neuronavigation system to cause a more defensive resection and therefore at least comparable resection rates. On the other hand, this visualization is also able to increase the surgeons' confidence

in the anatomy therefore causing more radical resection as also reported by IOM investigations.^{5,14,16} Duffau et al. not only reported an increased extent of resection but also a lower surgery-related morbidity, which is highly comparable to our results.¹⁴ With regard

to EOR, we observed a generally high rate of subtotal resection (STR), which can also be attributed to the firm rules of our data analysis. Every suspected residuum was evaluated as STR.

Tumor location

In terms of tumor location, we were not able to show any significant difference in surgery-related pareses within each group. However, we observed that nTMS patients suffered from fewer pareses when frontal or parietal lesions were resected (Fig. 6).

Table 2. Extent of resection and surgery-related new permanent paresis

	nTMS		non-nTMS	
	STR	GTR	STR	GTR
New permanent paresis	13.3%	12.9%	27.3%	16.7%
No new permanent paresis	86.7%	87.1%	63.7%	83.3%

Detailed overview on the percentage of patients with and without new permanent paresis divided into patients receiving subtotal (STR) or gross total resection (GTR) for both the nTMS and non-nTMS groups.

Table 3. Prior nTMS studies on brain tumor patients

Reference	Title	Study Subject
Krings et al., 1997	Stereotactic transcranial magnetic stimulation: correlation with direct cortical stimulation	Comparison with DCS
Macdonell et al., 1999	Motor cortex localization using functional MRI and transcranial magnetic stimulation	Comparison with fMRI
Picht et al., 2009	Navigated transcranial magnetic stimulation for preoperative functional diagnostics in brain tumor surgery	Comparison with DCS
Kantelhardt et al., 2010	Robot-assisted image-guided transcranial magnetic stimulation for somatotopic mapping of the motor cortex: a clinical pilot study	Comparison with DCS & fMRI
Picht et al., 2011	Preoperative functional mapping for rolandic brain tumor surgery: comparison of navigated transcranial magnetic stimulation to direct cortical stimulation	Comparison with DCS
Forster et al., 2011	Navigated transcranial magnetic stimulation and functional magnetic resonance imaging – advanced adjuncts in preoperative planning for central region tumors	Comparison with DCS & fMRI
Krieg et al., 2012	Utility of preoperative navigated brain stimulation for surgery in central region tumors	Comparison with DCS & fMRI; influence on decision making
Frey et al., 2012	A new approach for corticospinal tract reconstruction based on navigated transcranial stimulation and standardized fractional anisotropy values	nTMS-based DTI fiber tracking
Krieg et al., 2012	Diffusion Tensor Imaging Fiber Tracking Using Navigated Brain Stimulation – a feasibility study	nTMS-based DTI fiber tracking
Paiva et al., 2012	Cortical mapping with navigated transcranial magnetic stimulation in low-grade glioma surgery	Comparison with DCS
Tarapore et al., 2012	Preoperative multimodal mapping: a comparison of magnetoencephalography imaging, navigated transcranial magnetic stimulation, and direct cortical stimulation	Comparison with DCS & MEG
Picht et al., 2012	Assessment of the influence of navigated transcranial magnetic stimulation on surgical planning for tumors in or near the motor cortex	Influence on decision making
Krieg et al., 2013	Presurgical navigated transcranial magnetic stimulation for recurrent glioma of the motor cortex	Comparison with DCS & fMRI in recurrent glioma
Sollmann et al., 2013	Inter- and intraobserver variability in motor mapping of the hotspot for the abductor pollicis brevis muscle	Retest reliability
Picht et al., 2013	The preoperative use of navigated transcranial magnetic stimulation facilitates early resection of suspected low-grade gliomas in the motor cortex	Influence on decision making

This table provides a condensed overview of previous studies, which are strongly related to the topic of our current study.

This might be due to the better visualization of the motor cortex when surgery is performed on lesions directly adjacent to the motor cortex. In contrast, we observed 3 patients in the nTMS group with a paresis after temporoparietal tumor resection. Yet, these patients all suffered from secondary hemorrhage (2 patients) or ischemia (1 patient) as the cause of new surgery-related paresis.

Further mapping techniques

Other methods of non-invasive cortical motor mapping are MEG and fMRI. Compared MEG, fMRI is broadly available. Some studies were able to show a rather good correlation of fMRI and DCS by showing that fMRI was able to identify the correct gyrus at least.^{5,9,17-19} However, fMRI does not measure electrophysiological function but increased metabolism as surrogate parameter of neurological activation. Yet, metabolism can change due to ischemia, edema, or tumor infiltration independently of brain function.²⁰ Therefore, various studies proved that fMRI lacks sufficient sensitivity and specificity to identify eloquent brain function in the vicinity of intracerebral lesions; therefore, it should not be used for surgical planning.²¹⁻²⁴ MEG was actually shown to correlate with nTMS.^{25,26} Yet, due to the high costs, its

distribution and availability are very limited despite its valuable characteristics as a non-invasive mapping technique. In contrast, nTMS with comparably easy and cheap availability represents a remarkable option for non-invasive mapping because it is also based on MEPs via neuronal activation and therefore has a close relationship to DCS, which is widely used by neurosurgeons.^{27–31} Navigated TMS, in contrast, can be performed in an awake patient and it allows surgical planning already at the state of indication or craniotomy (Fig. 2).

Limitations of nTMS

The precision of motor mapping by nTMS can be impaired by various confounding factors, such as the definition of rMT, registration errors, navigation errors, and brain shift after durotomy.^{32,33} Nevertheless, brain shift does not impair the practical use of nTMS: data is mainly used to get an initial impression of the anatomic correlations between function and tumor prior to surgery or at least prior to craniotomy. Moreover, implementation of nTMS into the neuronavigation has its second main value by identifying the precentral gyrus directly after durotomy, which can then be identified visually for the remaining time of surgery. Thus, in our experience, brain shift does not interfere severely with the intraoperative applicability of nTMS data.

Future impact of nTMS on neurosurgery

Preoperative nTMS mapping allows us to inform each patient individually of possible transient postoperative paresis, as we know exactly how close the rolandic region is to the intended resection border in every single case. Thus, we are able to assess operative risks for permanent paresis more precisely and we can use these data to prepare the patient preoperatively. Hence, nTMS data have also influence that cannot be measured by simple outcome studies but may lead to better prepared patients and thus improve patients' satisfaction. Nonetheless, clinical patient outcome is the most essential parameter in evaluating the worth of a new technique.

Research in context

Systematic review

Literature review was performed on medline by searching for all neurosurgical applications of nTMS. Data was weighted according to the type of trial. Yet, no study design other than simple cohort studies was observed (Table 3). Data on changes in surgical indication were recently published and show that the functional nTMS data have a considerable influence on indication and surgical planning.^{5,34} Due to the design, this study did not investigate the changes in indication for surgery, which will be another key application of nTMS in the future in order to detect potential tumor-induced plastic reshaping of the motor cortex as already described.^{35–37}

Interpretation

This work increases the level of evidence for preoperative motor mapping by nTMS for rolandic lesions in a group comparison study.

In order to increase generalisability of the results, all 100 consecutive patients were enrolled into the analysis without focusing on one specific subgroup of lesions.

Therefore, this work greatly improves the level of evidence for this new modality and we strongly advocate nTMS to become increasingly used for these lesions. Yet, a randomized trial on the comparison with the gold standard of intraoperative mapping seems mandatory to gain level I evidence for this modality. Nonetheless, we have to keep in mind that we even do not have level I evidence for intraoperative mapping by DCS although it is seen as standard of care in most countries. Up to now, the best available level of evidence for DCS is also provided by a matched pair analysis with a historic control group.¹⁴

Funding

The study was completely financed by institutional grants through the Department of Neurosurgery.

Conflicts of interest statement. None declared.

References

1. Stummer W, Reulen HJ, Meinel T, et al. Extent of resection and survival in glioblastoma multiforme: identification of and adjustment for bias. *Neurosurgery*. 2008;62(3):564–576.
2. Capelle L, Fontaine D, Mandonnet E, et al. Spontaneous and therapeutic prognostic factors in adult hemispheric World Health Organization Grade II gliomas: a series of 1097 cases: clinical article. *J Neurosurg*. 2013;118(6):1157–1168.
3. Jakola AS, Myrmet KS, Kloster R, et al. Comparison of a strategy favoring early surgical resection vs a strategy favoring watchful waiting in low-grade gliomas. *JAMA*. 2012;308(18):1881–1888.
4. Picht T, Mularski S, Kuehn B, et al. Navigated transcranial magnetic stimulation for preoperative functional diagnostics in brain tumor surgery. *Neurosurgery*. 2009;65(6 Suppl):93–98.
5. Krieg SM, Shiban E, Buchmann N, et al. Utility of presurgical navigated transcranial magnetic brain stimulation for the resection of tumors in eloquent motor areas. *J Neurosurg*. 2012;116(5):994–1001.
6. Tarapore PE, Tate MC, Findlay AM, et al. Preoperative multimodal motor mapping: a comparison of magnetoencephalography imaging, navigated transcranial magnetic stimulation, and direct cortical stimulation. *J Neurosurg*. 2012;117(2):354–362.
7. Barker AT, Jalinin R, Freeston IL. Non-invasive magnetic stimulation of human motor cortex. *Lancet*. 1985;1(8437):1106–1107.
8. Ilmoniemi RJ, Ruohonen J, Karhu J. Transcranial magnetic stimulation—a new tool for functional imaging of the brain. *Crit Rev Biomed Eng*. 1999;27(3–5):241–284.
9. Krieg SM, Shiban E, Buchmann N, et al. Presurgical navigated transcranial magnetic brain stimulation for recurrent gliomas in motor eloquent areas. *Clin Neurophysiol*. 2013;124(3):522–527.
10. Krieg SM, Buchmann NH, Gempt J, et al. Diffusion tensor imaging fiber tracking using navigated brain stimulation—a feasibility study. *Acta Neurochir (Wien)*. 2012;154(3):555–563.
11. Krieg SM, Shiban E, Droese D, et al. Predictive value and safety of intraoperative neurophysiological monitoring with motor evoked potentials in glioma surgery. *Neurosurgery*. 2012;70(5):1060–1071.
12. Krieg SM, Schaffner M, Shiban E, et al. Reliability of intraoperative neurophysiological monitoring using motor evoked potentials

- during resection of metastases in motor-eloquent brain regions. *J Neurosurg*. 2013;118(6):1269–1278.
13. Stummer W, Pichlmeier U, Meinel T, et al. Fluorescence-guided surgery with 5-aminolevulinic acid for resection of malignant glioma: a randomised controlled multicentre phase III trial. *Lancet Oncol*. 2006;7(5):392–401.
 14. Duffau H, Lopes M, Arthuis F, et al. Contribution of intraoperative electrical stimulations in surgery of low grade gliomas: a comparative study between two series without (1985–96) and with (1996–2003) functional mapping in the same institution. *J Neurol Neurosurg Psychiatry*. 2005;76(6):845–851.
 15. Senft C, Bink A, Franz K, et al. Intraoperative MRI guidance and extent of resection in glioma surgery: a randomised, controlled trial. *Lancet Oncol*. 2011;12(11):997–1003.
 16. Picht T, Schulz J, Hanna M, et al. Assessment of the influence of navigated transcranial magnetic stimulation on surgical planning for tumors in or near the motor cortex. *Neurosurgery*. 2012;70(5):1248–1257.
 17. Roux FE, Boulanouar K, Lotterie JA, et al. Language functional magnetic resonance imaging in preoperative assessment of language areas: correlation with direct cortical stimulation. *Neurosurgery*. 2003;52(6):1335–1345; discussion 1345–1337.
 18. Yetkin FZ, Mueller WM, Morris GL, et al. Functional MR activation correlated with intraoperative cortical mapping. *AJNR Am J Neuroradiol*. 1997;18(7):1311–1315.
 19. FitzGerald DB, Cosgrove GR, Ronner S, et al. Location of language in the cortex: a comparison between functional MR imaging and electrocortical stimulation. *AJNR Am J Neuroradiol*. 1997;18(8):1529–1539.
 20. Sollmann N, Picht T, Makela JP, et al. Navigated transcranial magnetic stimulation for preoperative language mapping in a patient with a left frontoopercular glioblastoma. *J Neurosurg*. 2013;118(1):175–179.
 21. Rutten GJ, Ramsey NF. The role of functional magnetic resonance imaging in brain surgery. *Neurosurg Focus*. 2010;28(2):E4.
 22. Lehericy S, Duffau H, Cornu P, et al. Correspondence between functional magnetic resonance imaging somatotopy and individual brain anatomy of the central region: comparison with intraoperative stimulation in patients with brain tumors. *J Neurosurg*. 2000;92(4):589–598.
 23. Hou BL, Bradbury M, Peck KK, et al. Effect of brain tumor neovasculature defined by rCBV on BOLD fMRI activation volume in the primary motor cortex. *Neuroimage*. 2006;32(2):489–497.
 24. Krishnan R, Raabe A, Hatttingen E, et al. Functional magnetic resonance imaging-integrated neuronavigation: correlation between lesion-to-motor cortex distance and outcome. *Neurosurgery*. 2004;55(4):904–914; discussion 914–905.
 25. Vitikainen AM, Lioumis P, Paetau R, et al. Combined use of non-invasive techniques for improved functional localization for a selected group of epilepsy surgery candidates. *Neuroimage*. 2009;45(2):342–348.
 26. Tarapore PE, Tate MC, Findlay AM, et al. Preoperative multimodal motor mapping: a comparison of magnetoencephalography imaging, navigated transcranial magnetic stimulation, and direct cortical stimulation. *J Neurosurg*. 2012;117(2):354–362.
 27. Berger MS, Ojemann GA, Lettich E. Neurophysiological monitoring during astrocytoma surgery. *Neurosurg Clin N Am*. 1990;1(1):65–80.
 28. Sanai N, Berger MS. Mapping the horizon: techniques to optimize tumor resection before and during surgery. *Clin Neurosurg*. 2008;55:14–19.
 29. Kombos T, Suess O, Funk T, et al. Intra-operative mapping of the motor cortex during surgery in and around the motor cortex. *Acta Neurochir (Wien)*. 2000;142(3):263–268.
 30. Suess O, Suess S, Brock M, et al. Intraoperative electrocortical stimulation of Brodmann area 4: a 10-year analysis of 255 cases. *Head Face Med*. 2006;2:20.
 31. Neuloh G, Pechstein U, Cedzich C, et al. Motor evoked potential monitoring with supratentorial surgery. *Neurosurgery*. 2007;61(1 Suppl):337–346.
 32. Suess O, Suess S, Mularski S, et al. [Evaluation of a DC pulsed magnetic tracking system in neurosurgical navigation: technique, accuracies, and influencing factors]. *Biomed Tech (Berl)*. 2007;52(3):223–233.
 33. Hastreiter P, Rezk-Salama C, Soza G, et al. Strategies for brain shift evaluation. *Med Image Anal*. 2004;8(4):447–464.
 34. Picht T, Schulz J, Hanna M, et al. Assessment of the influence of navigated transcranial magnetic stimulation on surgical planning for tumors in or near the motor cortex. *Neurosurgery*. 2012;70(5):1248–1256; discussion 1256–1247.
 35. Duffau H. New concepts in surgery of WHO grade II gliomas: functional brain mapping, connectionism and plasticity--a review. *J Neurooncol*. 2006;79(1):77–115.
 36. Robles SG, Gatignol P, Lehericy S, et al. Long-term brain plasticity allowing a multistage surgical approach to World Health Organization Grade II gliomas in eloquent areas. *J Neurosurg*. 2008;109(4):615–624.
 37. Ius T, Angelini E, Thiebaut de Schotten M, et al. Evidence for potentials and limitations of brain plasticity using an atlas of functional resectability of WHO grade II gliomas: Towards a “minimal common brain”. *Neuroimage*. 2011;56(3):992–1000.