

Middle ear of human and pig: a comparison of structures and mechanics

Marc Hoffstetter^{1,*}, Florian Lugauer¹, Subir Kundu¹, Sabine Wacker¹, Héctor Perea-Saveedra¹, Tomas Lenarz², Patrick Hoffstetter³, Andreas G. Schreyer³ and Erich Wintermantel¹

¹ Department and Chair for Medical Engineering, Technische Universität München, Munich, Germany

² Department of Otolaryngology, Medical University of Hannover, Hannover, Germany

³ Department of Radiology, University Hospital Regensburg, Regensburg, Germany

Abstract

Introduction: Animal studies are an essential method to evaluate implants for the middle ear prior to clinical studies. New Zealand rabbits, guinea pigs and chinchillas are, among other small mammals, well established animal models, but their auditory system is significantly smaller compared to human. Hence, the suitability of the domestic pig (*sus scrofa domesticus*) as a new animal model for research on the middle ear (ME), that would match the human in size, was investigated.

Methods: Thirty halved pig heads were obtained from the butcher and each middle ear was dissected. Using a digital light microscope, several anatomical magnitudes were determined for 24 specimens, namely the planar projected area of the tympanic membrane (TM), in relation to the stapes footplate as well as the dimensions and weight of the ossicles, in order to determine the effective lever ratios. Using normal and micro computed tomography (CT), six porcine temporal bones were scanned and the geometric data obtained were transferred into a finite element model (FEM) simulation of the porcine middle ear. The transfer function was determined and compared to those from humans determined by measurements and simulations, respectively.

Results: The anatomy investigated presented itself as highly comparable to that of the human. Differing from literature, no fourth ossicle could be found. The porcine dimensions and lever ratios determined match the humans far better than those of all established animal models. The obtained transfer function was congruent to the human one. This underlines the suitability of the pig as an animal model for middle ear implants.

Keywords: FEM; human; lever ratio; middle ear; pig; transfer function.

Introduction

Rabbits [32, 33], guinea pigs [13, 30] and chinchillas [3, 5, 12] are, among other small mammals, well established animal models for investigations on the middle ear (ME) and its implants. Prostheses have to be scaled down to fit into the cavity of the animal ME. This procedure may lead to distorted acoustical behavior due to scaling-effects (differing surface/volume ratio and mass of implant) [6] and requires additional effort to downsize the implants. Hence, an animal model, matching the human in size, would be of interest. As a consequence, the suitability of the common domestic pig (*sus scrofa domestica*) as an animal model for investigations on the ME should be analyzed more thoroughly. Up to date, the pig is used for investigations upon skin [23, 24], inflammatory processes within the ME [18, 31], morphology of the inner ear [21] and is proposed as an object for surgical training in otology [14, 15]. An additional comparison of the human and porcine ME structures and bio-mechanics shall substantiate the common pig as an animal model for ME surgery and implants.

Materials and methods

Thirty halved heads from common domestic pigs (*sus scrofa domestica*, “German Landrace”) were obtained from the butcher (Hans Ritter GmbH, Munich, Germany) and dissected within 12 h post mortem. The specimens were randomly chosen, disregarding sex or weight of the animals which could be considered as full-grown and mature for slaughter (90 kg ± 5 kg). The heads were cleaved and the brains removed by the butchery. As inspected by an official veterinarian, the specimens could be obtained as normal foodstuff without any further controls or permission by an ethics committee or any other authority.

Preparation

After first inspection for cracks within the skull, or anatomical disorders, each head was dissected in order to obtain a cube of 4 × 4 × 5 cm, containing the entire tympanic cavity with its internal structures. Tools for this first step included scalpels to cut soft tissue and a hacksaw to cleave bony structures. A standard procedure could be established. Using a hand drill MicroMot 50 E (Proxxon, Niersbach, Germany) with flexible shaft and several types of cutters, at 24 of the initial 30 specimens the cartilaginous and bony structures of

*Corresponding author: Marc Hoffstetter, Department and Chair for Medical Engineering, Technische Universität München, Munich, Germany
Phone: +49 (0)89 28916715
Fax: +49 (0)89 28916702
E-mail: marc.hoffstetter@mytum.de

the external auditory canal were removed until the tympanic membrane (TM) could be seen over its entire planar latitude. This second step of dissection had to be carried out very accurately to avoid damage of the delicate structures of the TM and ossicular chain. After removing the TM using a sickle-shaped scalpel, the ossicles were removed with normal tweezers and stored in a solution of 70% (by weight) ethanol (VWR International GmbH, Darmstadt, Germany) and purified water at 4 to 8°C until further measurements.

Tympanic membrane

Before removing the TM, it was inspected using a digital light microscope VHX 500 with an objective VH-Z20 (Keyence Corporation, Osaka, Japan). The planar projected area of the TM, semi-major and semi-minor axes were determined with the measurement tool included in the microscopes software. By inscribing a polygon in the digital image along the boundary of the TM, the area could be calculated automatically (Figure 1A). This procedure was repeated five times and the average value was registered. Based upon the microscopes depth of field (5 mm at magnification $\times 20$, 1 mm at $\times 100$), the maximal error of measurement ΔA_{err} due to tilt of the specimen could be calculated and was less than 10%.

Ossicles

All ossicles were weighed with an analytical balance L230S (Sartorius, Göttingen, Germany) with an accuracy of 0.1 mg and observed under the digital light microscope. The main intention of further investigations was to determine the lever ratio between the malleus and the incus and the aerial ratio between the TM and the stapedial base. In the absence of established methods of measurement for porcine ossicles, those common for human ones were used as far as available and reasonable.

Determined were length of the manubrium according to Nomura et al. [26] and the effective lever, assuming the center of ratio during oscillation to be in the head (Figure 1B). The finding of Masali [22], that for human ossicles the effective lever of the malleus and length of the manubrium are identical, was not transferred to the pig. Thus, for the porcine malleus, a circle was constructed, matching its head. The distance of its centre to the umbo along the axis of the manubrium was taken as the effective lever. Height and width of the incus and its effective lever were determined according to Nomura et al. [26] (Figure 1C). Dimensions of the stapes were determined according to Farahani and Nooranipour [9], namely height and width as well as the angle between both crura (Figure 1D). Not a single stapes could be dissected entirely, as all footplates stayed affixed in the oval window (OW) when removing the stapes. The planar projected area of the OW was measured and taken as the area of the stapedial base (Figure 1E).

FEM simulation

Five of the porcine temporal bones, still containing the ossicles and the TM, were used to perform imaging using CT in

the same way as is customary when examining humans (bone window). These scans, using a Somatom Sensation 16 (Siemens Health Care, Erlangen, Germany), were carried out for preliminary testing and to compare the imaging with those from human temporal bones. Another specimen, still containing all structures of the ME, was scanned using micro computed tomography (μ -CT) with a TomoCheck® (Werth Messtechnik GmbH, Gießen, Germany) with a voxel-size of 24 μ m (edge length). The obtained data were segmented using Amira 5 (Visage Imaging, Carlsbad, CA, USA) to obtain a computer aided design (CAD) model of the ME structures. All dimensions of the virtual ME were compared to those measured at the real ones. Using Catia V5R18 (Dassault Systèmes, Vélizy-Villacoublay, France) and Ansys Workbench 11 (Ansys Inc., Canonsburg, PA, USA) an FEM model was created, consisting of the TM, malleus, incus and stapes. The external auditory canal, and pneumatized structures of the ME were neglected, a common for these types of models [10, 11, 16]. Incudo-malleolar (IM) joint, incudo-stapedial (IS) joint, all ligaments and muscles, ligamentum annulare and the inner ear were implemented congruent to the human ME model established by Hoffstetter et al. [16]. As no values for pigs were available in literature, material properties were taken from established FEM simulations for the human ME [10, 11, 16]. As the boundary condition, a fixed bearing was applied to the border of the TM, representing the annulus fibrocartilaginous, and to the ends of all ligaments and muscles. For more details on the FEM model set up please refer to [16]. The porcine FEM model was excited with a sinusoidal sound pressure level (SPL) of 90 dB over a frequency range of 0.1 Hz to 10 kHz (Figure 2) applied to the TM. According to literature, for an SPL up to 90 dB, linear material properties can be assumed [7, 10, 34, 36]. As transfer function (TF) the peak amplitude of the piston-like motion of the stapes footplate depending on the frequency was determined.

Results

The ME anatomy of the pig ear appeared highly similar to the human. The standard procedure established enabled dissection of the porcine middle in a reproducible manner.

TM and ossicles

By outer appearance, the TM greatly resembled the human eardrum. The same was observed for the ossicles. Only the incus appeared smaller in relation to the malleus and featured a more bulky shape than in humans. Striking was the similarity of the stapes. A fourth ossicle, as described by some authors [8, 25], named *os lenticulare* and located between stapes and incus, fixed via ligaments to the latter, could not be observed. The values obtained from measurements were compared to those from pigs, rabbits, guinea pigs, chinchillas and humans, taken from literature [10, 17, 19, 22, 26, 27, 29, 31, 37, 38] (Table 1). For those values that influence the lever ratio and the aerial ratio, the aberration to humans as reference is given in percent. Thereby the minimum distance between the ranges of values was considered.




Figure 1 Light microscope image of the measurement of ossicles. (A) Tympanic membrane: determined were semi-major (SMA_{TM}) and semi-minor axes (SMI_{TM}) as well as the planar projected area A_{TM} . (B) Malleus: determined were length of the manubrium L_M according to Nomura et al. [26] and its effective lever EL_M , assuming the center of rotation during oscillation to be in the head. (C) Incus: determined were height H_I and width W_I and its effective lever EL_I according to Nomura. (D) Stapes: determined were height H_S , width W_S and the angle α_s between both crura according to Farahani and Nooranipour [9]. (E) Oval window: a single stapes could not be dissected entirely. Thus, semi-major (SMA_{OW}) and semi-minor axes (SMI_{OW}) as well as the planar projected area A_{OW} of the oval window, were determined the same way as the TM and these values were taken as data for the stapes footplate.

FEM simulation

The CT images of the porcine ME were highly similar to comparable human ones. The structures of the auditory system such as ossicles, TM or the helical cochlea, could be seen clearly and in the same quality as when examining a human. The results obtained by μ CT imaging featured con-

gruent results but with a resolution significantly increased. The CAD model of the ME, built by segmentation of the μ CT raw data, showed an ossicular chain and a TM congruent to the findings during preparation. All values of the model were compared to those determined by measurement and found to be within the dispersion of values. The TF determined, displayed in Figure 3, was compared to those of

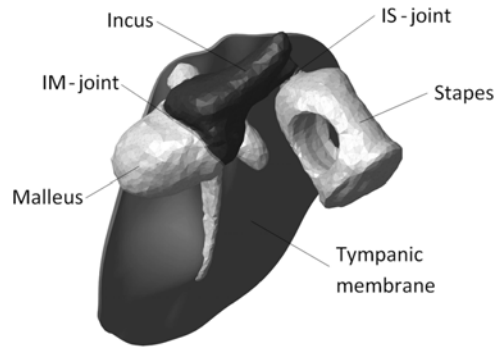


Figure 2 Illustration of the porcine FEM middle ear model established. Ligaments, muscles and inner ear are not displayed. The lateral surface of the TM was excited with a SPL of 90 dB over a frequency range of 0.1 to 10 kHz. As result, the transfer function, namely the peak amplitude of displacement of the stapes depending on frequency, was determined.

the human derived from both simulations and measurements [1, 10, 11, 16, 35, 36].

Discussion

The outer appearance of the porcine auditory system significantly differs from that of the human. Eye-catching is the significantly longer outer ear canal and the differing arrangement and spatial orientation of the auricle, external acoustic meatus and tympanic cavity as described by Gurr et al. [14] and Pracy et al. [31].

TM and ossicles

The anatomy of the porcine ME cavity highly resembled that of the human. This finding is congruent to the results of Pracy et al. [31] and Gurr et al. [14, 15]. Porcine TM and stapes are particularly comparable to the human ones. No findings suggested that the proposal of Gurr et al. [14], to use the porcine temporal bone as an object for surgical training, be rejected.

The fact that all stapedia bases stayed affixed in the oval window, might indicate that the porcine stapes superstructure is significantly more delicate, or that the porcine annular ligament is stiffer than the human one. The latter would have a significant impact on the comparability of human and porcine sound conduction. Although FEM simulation did not indicate such a correlation, this topic should be analyzed in more detail.

The finding that no *os lenticulares* could be found, might be explained by the similarity of the bony and cartilaginous structures of the porcine ossicular chain. According to Ellenberger and Baum [8], Nickel et al. [25] and Nußhag [28], this fourth ossicle is firmly attached to the incus by cartilage and small ligaments. More details about this structure in pigs could not be found in literature. It is possible that these two ossicles cannot be distinguished, or even show rigid bonding, as is reported for the malleus and incus in guinea pigs by

Amin and Tucker [2] or in the chinchilla by Vrettakos et al. [37] who examined five animals. The topic of a fourth ossicle within the human ME has been discussed for more than two hundred years. In a comprehensive study, Chien et al. [4] analyzed this structure in humans and found signs that indicate a bony connection, ergo three ossicles, as well as signs that indicate more cartilaginous bonding, suggesting four ossicles. The resolution of the μ Ct used was not fine enough to sufficiently distinguish between cartilage and bone and thus the CAD data used for FEM simulation could not elucidate this issue. The use of advanced techniques for imaging could solve this problem.

The dimensions of the ossicles determined are comparable to the values determined by Pracy et al. [31], but slightly smaller. This may be due to different breeds being used for investigations. Unfortunately, Pracy did not specify the breed.

Among all established animal models used for investigations on the ME, only the TM of the chinchilla (100%) meets the area of the human eardrum, just as the porcine does (99%). The porcine area ratio (152%) and lever ratio (114%), however, are closer to those of the human than those of the chinchilla (156% and 200%, respectively), as determined by Vrettakos et al. [37]. According to Nummela [27], the rabbit features an area ratio highly comparable to human (91.3%) but the TM only features approximately half the size (56%). Masali [22] suggested that for investigations on all mammals, the length of the manubrium should be taken as the effective lever of the malleus. Regarding the significantly longer neck of the porcine malleus compared to that of the human, this suggestion is questionable. Following Masali's proposal, the lever ratio measured would have been decreased by approximately 20% and then match the human one (100%). This may substantiate the idea presented that the center of rotation is located within the head of the malleus, although shifting depending on frequency. This method to determine the effective lever can easily be transferred to all mammals and may display reality in a better way. When comparing the lever ratios, it is important to remember that these are not fixed but highly dependent on the exciting frequency. This fact was not considered when determining the lever ratio. As the measurements were performed according to established data, a comparison to them is reasonable.

It may be concluded that, concerning its dimensions, lever ratio and area ratio of the porcine ME are more similar to the human ones than those from established animal models. As the porcine lever ratio and area of the TM are congruent to those of humans, the pig appears to be a suitable animal model for investigations on ME implants. A more detailed analysis of the porcine ME is encouraged.

Simulation

Human and porcine ME can hardly be distinguished using standard CT. The surrounding structures, however, show significant differences. Contrary to humans, the hypotympanon in pigs is locular and called *cellulae tympanicae* – no mastoid process can be found. These results are congruent to the findings of Pracy et al. [31], who performed comparable

Table 1 Results from measurements of the porcine middle ear structures were compared to values for pigs, rabbits, guinea pigs, chinchillas and humans taken from literature [10, 17, 19, 22, 26, 27, 29, 31, 37, 38] as far as available. For those values that influence the lever ratio and aerial ratio, the aberrations from humans as reference are given as a percentage. Thereby the minimum distance between the ranges of values was considered.

	Pig (measurement)	Pig (literature) [27, 31]	Rabbit (lit.) [27]	Guinea pig (lit.) [17, 27]	Chinchilla (lit.) [27, 37]	Human (lit.) [10, 19, 22, 26, 27, 29, 38]
Area TM and OW						
TM area (mm ²)	44.49 (± 3.37) (99%)	45–62.1 (100%)	28.2 (56%)	23.9 (47.8%)	55.64–56.3 (100%)	50–88 (100%)
TM semi-major axis (mm)	11.6 (± 1.36)	9.5	n.a.	n.a.	8.53–8.96	7.5–9
TM semi-minor axis (mm)	9.86 (± 1.24)	8.24	n.a.	n.a.	8.0–8.32	7.5–9
OW area (mm ²)	1.24 (± 0.13) (47%)	1.81 (69%)	1.34 (51%)	0.81 (31%)	1.55 (59%)	2.65–3.75
OW semi-major axis (mm)	1.7 (± 0.1)	1.8	1.52	1.52	2.19	2.3–3.0
OW semi-minor axis (mm)	1.0 (± 0.1)	1.28	1.12	0.68	0.78–0.93	1.08–1.66
Aerial ratio	35:1 (152%)	29.6:1 (128%)	21:1 (91.3%)	29.5:1 (128%)	35.9:1 (156%)	17–23:1
Ossicles						
Malleus, length (mm)	4.8 (± 0.4)	4.0	n.a.	n.a.	n.a.	4.4–5.8
Malleus effective lever (mm)	4.9 (± 1.4)	7.0	n.a.	n.a.	4.5	n.a.
Malleus weight (mg)	10.7 (± 1.0)	9.43	2.82	3.13	6.6–7.13	22–32
Incus width (mm)	3.12 (± 0.15)	n.a.	n.a.	n.a.	n.a.	4.99–5.0
Incus effective lever (mm)	3.05 (± 0.14)	2.0	n.a.	n.a.	1.58	4.36–7
Incus weight (mg)	5.8 (± 0.5)	5.18	2.10	1.76	4.19–5.2	27.39–33.6
Lever ratio	1.6:1 (114%)	3.5:1 (250%)	n.a.	n.a.	2.84:1 (200%)	1.3:1–1.4:1
Malleus and incus weight (mg)	16.4 (± 1.3)	16.61	4.92	4.89	11.8 ($\pm ?$)	50.4–62.1
Stapes height (mm)	2.16 (± 0.14)	2.0	n.a.	n.a.	n.a.	2.61–3.32
Stapes width (mm)	2.05 (± 0.14)	n.a.	n.a.	n.a.	n.a.	2.30–3.03
Stapes angle (°)	32 (± 2.0)	n.a.	n.a.	n.a.	n.a.	20
Stapes weight (mg)	1.0 (± 0.4) (33%)	1.23 (41%)	0.39 (13%)	0.35 (11.6%)	0.4–0.435 (14.5%)	3

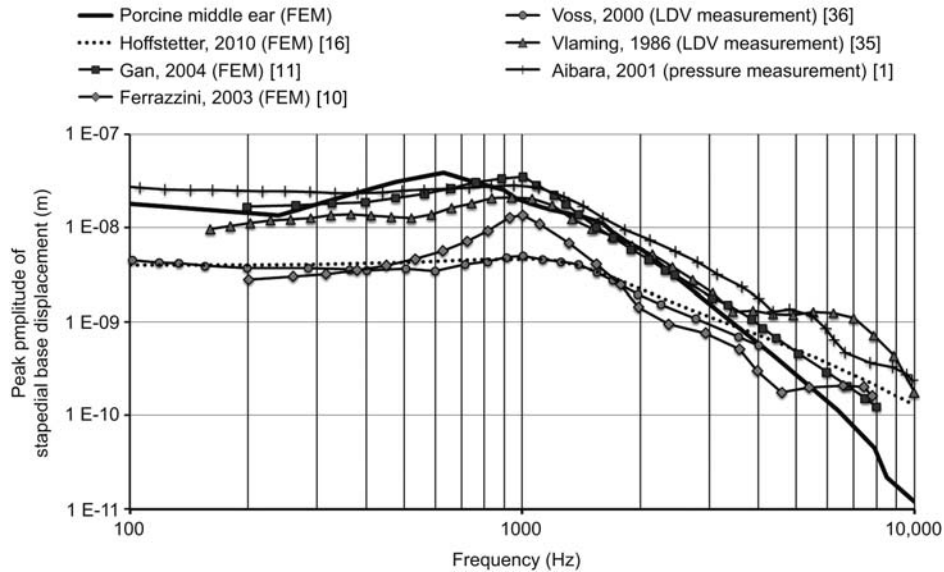


Figure 3 Stapedial base displacement (piston like motion) at 90 dB SPL at the TM of the porcine FEM middle ear model established. The curve is in high accordance with those determined for the human by measurements and simulations [1, 10, 11, 16, 35, 36] (all curves normalized to a SPL of 90 dB).

scans. In terms of imaging by CT, porcine and human ossicular chain, TM and cochlea can be considered as equivalent.

Investigations on the mechanics of the porcine ME, as demanded by Gurr et al. [14], were carried out by an established tool, an FEM simulation [10, 11, 16]. All dimensions of the model presented were within the dispersion of values resulting from measurement. This can be considered as representative of all of the pigs investigated. The TF of the pig is comparable to that of the human, determined by simulation and measurement, respectively. This may indicate that the mechanics of the porcine ME are comparable to those of the human middle ear.

Outlook

For the first time, the porcine ME was investigated with the focus on its biomechanics. Although the results must be considered as preliminary results, the findings indicate that the dimensions and kinematics of the TM and ossicular chain in humans and pigs are highly comparable. More detailed investigations of the suitability of the domestic pig as an animal model for investigations on the ME appear worthwhile.

The results indicate that the porcine lever ratios match human lever ratios. Additional investigations on the spatial orientation of the ossicles, however, are necessary. These include measurements of the distance of the umbo to the stapes head and base, as well as the angles between the axis normal to the TM, the axis along the umbo and the axis normal to the stapedial base. These data are essentially to evaluate the comparability of human and porcine ME, however, limited results are available for established animal models.

The quality of the FEM model presented is not fully resolved. It is possible that the material properties of the porcine ME structures differ significantly from the human ones used for simulation. The TF of the model established could be cross-checked by measurements, as done by Kurokawa and Goode [20] or Voss and Goode [36], using a laser doppler vibrometer. The fundamental suitability of human material properties might then be proved or disproved.

A more thorough investigation of the joints between the ossicles might be useful and may suggest that the porcine ME could become an object of investigation to elucidate the functionality of these structures in humans. These easily obtainable samples could be used to increase the knowledge of the functionality of the human ossicular chain.

Acknowledgements

The authors wish to thank all colleagues and collaborators who helped to generate these results. Special thanks are dedicated to Prof. Feuerbach, chair of the department for radiology at the University Hospital Regensburg and to Mr. Ebert and Mr. Kestel from Scholz-HTIK Ltd. in Kronach for providing the opportunity to perform micro computer tomography.

References

- [1] Aibara R, Welsh JT, Puria S. Human middle-ear sound transfer function and cochlea input impedance. *Hearing Res* 2000; 152: 100–109.
- [2] Amin S, Tucker AS. Joint formation in the middle ear: lessons from the mouse and guinea pig. *Dev Dyn* 2006; 235: 1326–1333.

- [3] Bakaletz LO. Chinchilla as a robust, reproducible and polymicrobial model of otitis media and its prevention. *Expert Rev Vaccines* 2009; 8: 1063–1082.
- [4] Chien W, Northrop C, Levine S, et al. Anatomy of the distal incus in humans. *JARO* 2009; 10: 485–496.
- [5] Downey T. AlloDerm tympanoplasty of tympanic membrane perforations. *Am J Otolaryngol* 2003; 24: 6–13.
- [6] Dym LC. Principles of mathematical modelling. 2nd ed. Burlington: Elsevier Academic Press 2004.
- [7] Eiber A, Breuninger C. Nonlinear properties of the middle ear: some influences on hearing and diagnosis. *Proceedings of the Middle Ear Mechanics in Research and Otology*, Matsuyama, Ehime, Japan, 2003.
- [8] Ellenberger W, Baum H. *Handbuch der vergleichenden Anatomie der Haustiere*. 18th ed. Stuttgart: Springer-Verlag 1974.
- [9] Farahani RM, Nooranipour M. Anatomy and anthropometry of human stapes. *Am J Otolaryngol* 2006; 29: 42–47.
- [10] Ferrazzini M. Virtual middle ear: a dynamic mathematical model based on the finite element method. Swiss Federal Institute of Technology, Zurich, 2003.
- [11] Gan RZ, Feng B, Sun Q. Three-dimensional finite element modeling of human ear for sound transmission. *Ann Biomed Eng* 2004; 32: 847–859.
- [12] Giebink GS. Otitis media: the chinchilla model. *Microb drug resist* 1999; 5: 57–72.
- [13] Goksu N, Haziroglu R, Kemaloglu Y, Karademir N, Bayramoglu I, Akyildiz N. Anatomy of the guinea pig temporal bone. *Ann Otol Rhinol Laryngol* 1992; 101: 699–704.
- [14] Gurr A, Kevenhörster K, Stark T, Pearson M, Dazert S. The common pig: a possible model for teaching ear surgery. *Eur Arch Otorhinolaryngol* 2009; 267: 213–217.
- [15] Gurr A, Stark T, Probst G, Dazert S. The temporal bone of lamb and pig as an alternative in ENT-education. *Laryngo Rhino Otologie* 2009; 89: 17–24.
- [16] Hoffstetter M, Schardt F, Lenarz T, Wacker S, Wintermantel E. Parameter study on a FEM middle ear model. *Biomed Eng* 2010; 1: 19–26.
- [17] Holz K. Vergleichende anatomische und topographische Studie über das Mittelohr der Säugetiere. *Anat Embryol* 1931; 94: 757–791.
- [18] Ikarashi F, Nakano Y, Okura T. The relationship between the degree of chronic middle ear inflammation and tympanic bulla pneumatization in the pig as animal model. *Oto Rhino Laryngol* 1994; 251: 100–104.
- [19] Kirikae I. *The structure and function of the middle ear*. 1st ed. Tokyo: The University of Tokyo Press 1960.
- [20] Kurokawa H, Goode RL. Sound pressure gain produced by the human middle ear. *Otolaryngol Head Neck Surg* 1995; 113: 349–355.
- [21] Lovell JM, Harper GM. The morphology of the inner ear from the domestic pig (*Sus scrofa*). *J Microsc* 2007; 228: 345–357.
- [22] Masali M. The ear ossicles and the evolution of the primate ear: a biomechanical approach. *J Hum Evol* 1992; 7: 1–5.
- [23] Meingassner JG, Grassberger M, Fahrngruber H, Moore HD, Schuurmann H, Stütz H. A novel anti-inflammatory drug, SDZ ASM 981, for the topical and oral treatment of skin diseases: in vivo pharmacology. *Br J Dermatol* 1997; 137: 568–576.
- [24] Meyer W. Bemerkungen zur Eignung der Schweinehaut als biologisches Modell für die Haut des Menschen. *Hautarzt* 1996; 47: 178–182.
- [25] Nickel R, Schummer A, Seiferle E. *Nervensystem, Sinnesorgane, Endokrine Drüsen*. 4 ed. IV. Stuttgart: Parey 2004.
- [26] Nomura Y, Hiriade F, Harada T. *New atlas of otology*. 1st ed. Tokyo: Springer Verlag 1992.
- [27] Nummela S. Scaling of the mammalian middle ear. *Hear Res* 1995; 85: 18–30.
- [28] Nußbarg W. *Lehrbuch der Anatomie und Physiologie der Haustiere*. 1st ed. Leipzig: S. Hirtzel Verlag 1962.
- [29] Park K, Lee JH, Cho MJ, Won YY, Baek MH. Three-dimensional micro-CT images for human ossicles. In: Gyo K, Wada H, editors. *Middle ear mechanics in research and otology*. Singapore: World Scientific 2003; 260–270.
- [30] Petrova P, Freeman S, Sohmer H. The effects of positive and negative middle ear pressures on auditory threshold. *Otol Neurotol* 2006; 27: 734–738.
- [31] Pracy JP, White A, Mustafa Y. The comparative anatomy of the pig middle ear cavity. *J Anat* 1998; 192: 359–368.
- [32] Schwager K. Titan als Gehörknöchelchenersatzmaterial. In vivo-Untersuchungen im Mittelohr des Kaninchens und Untersuchungen zur Proteinadsorption am Implantatmaterial, Medizinische Fakultät, Julius-Maximilian-Universität, Würzburg, 1998.
- [33] Stieve M, Hedrich HJ, Battmer RD, Behrens P, Müller P, Lenarz T. Experimental middle ear surgery in rabbits: a new approach for reconstructing the ossicular chain. *Lab Animal* 2009; 43: 198–204.
- [34] Stuhlmann O. The nonlinear transmission characteristics of the auditory ossicle. *J Acoust Soc Am* 1937; 9: 119–128.
- [35] Vlaming MSMG, Feenstra L. Studies on the mechanics of the normal human middle ear. *Clin Otolaryngol* 1986; 11: 353–363.
- [36] Voss SE, Rosowski JJ, Saumlil N. Acoustic responses of the human middle ear. *Hear Res* 2000; 150: 43–69.
- [37] Vrettakos PA, Dear SP, Saunders JC. Middle ear structure in the chinchilla. *Am J Otolaryngol* 1988; 9: 58–67.
- [38] Wever EG, Lawrence M. *Physiological acoustics*. Princeton: Princeton University Press 1954.

Received April 13, 2010; accepted April 7, 2011