

Mammary analogue secretory carcinoma of salivary glands: diagnostic pitfall with distinct immunohistochemical profile and molecular features

Oliver Bissinger,¹ Carolin Götz,¹ Andreas Kolk,¹ Henning A. Bier,² Abbas Agaimy,³ Henning Frenzel,⁴ Sven Perner,^{5,6} Julika Ribbat-Idel,^{5,6} Klaus Dietrich Wolff,¹ Wilko Weichert,⁷ Caroline Mogler⁷

¹Department of Oral- and Maxillofacial Surgery, Klinikum rechts der Isar der Technischen Universität München;

²Department of Otolaryngology, Klinikum rechts der Isar der Technischen Universität München;

³Institute of Pathology, Erlangen University; ⁴Department of Otolaryngology, Luebeck University Hospital; ⁵Department of Pathology, University Medical Center Schleswig-Holstein, Campus Luebeck and Research Center Borstel; ⁶Leibniz Center for Medicine and Biosciences; ⁷Institute of Pathology, Technische Universität München, Germany

Abstract

Mammary analogue secretory carcinoma (MASC) is a newly defined entity among salivary gland malignancies which has just been established in the 4th edition of the WHO classification of head and neck tumors. MASC (synonym: secretory carcinoma) are characterized by a specific rearrangement of the *ETV6* gene locus. Here, we present a series of 3 MASC cases including clinical data with follow-up for up to 26 months. All tumours immunohistochemically displayed strong positivity for cytokeratin 7, and mammaglobin, focal positivity for S100, cytokeratin 5/6 and muc-4. In contrast, immunohistochemical stainings against cytokeratin 14, hormone receptors, Her2/neu, androgen receptor and prostate-specific antigen were consistently negative. FISH analysis showed translocation of the *ETV6* gene locus in the majority of tumour cell nuclei. During clinical follow-up, no local relapse or metastasis was detected. As these carcinomas are clinically and radiologically indistinguishable from other salivary gland tumours and as therapeutic approaches and prognosis might differ, we need to be able to diagnose MASC correctly.

Introduction

The first description of mammary analogue secretory carcinoma (MASC) was published by Skalova *et al.* in 2010.¹ Since then, more than 70 additional cases have been reported,² often in small series of 10 cases or fewer.^{3,4} MASC are mostly located in the parotid region but can appear in any location of the head and neck region.⁵ Patients at all age are affected, including children and young adults.⁶⁻¹⁰ MASC are considered to be of low-grade malignancy; however, high-grade transformation and aggressive clinical behaviour has been described.^{3,6,11,12} The prognostic impact of MASC is not clear as yet, although evidence exists that MASC has a comparable prognosis to other (low-grade) salivary gland tumours.^{1,13} MASC are mostly small tumours measuring typically only a few centimeters in diameter.⁵ Clinical/radiological characteristics include their description as solitary tumour masses with a partially cystic architecture and clear defined margins, comparable with secretory carcinomas in the breast.¹⁴ Histological misinterpretation of MASC as pleomorphic adenoma, mucoepidermoid carcinomas, adenocarcinoma not other specific (NOS), low-grade salivary duct carcinomas or acinic cell carcinomas (ACC) is common and can lead to wrong therapeutic approaches.^{2,5,15} A distinct genetic alteration, the *ETV6-NTRK3* gene fusion with translocation t(12;15)(p13;q25),^{15,16} has been described for MASC by analogy to the genetic profile of secretory breast carcinoma;^{17,18} however, *ETV6* rearrangement with fusion partners other than *NTRK3* have recently been reported.¹⁹ These translocations are typically not present in other salivary gland neoplasms and might help to find the correct diagnosis.^{15,20} This study includes three cases with detailed immunohistochemical characterization and a discussion of differential diagnosis to avoid MASC being a diagnostic pitfall, especially in small biopsies of salivary gland tumours.

Materials and Methods

Patient samples and clinical data

Three patients with primary diagnosis of MASC were included. For this study, diagnosis of MASC was reviewed by independent consultant pathologists, all expert in salivary gland pathology. The study was approved by the local ethics committee (no. 212108) in accordance with the Declaration of Helsinki. Informed consent was obtained from all patients.

Correspondence: Carolin Mogler, Institute of Pathology, Technical University Munich, Trogerstraße 18, 81675 München, Germany. Tel: +49.8941.404166 - Fax: +49.8941.406160. E-mail: carolin.mogler@tum.de

Key words: mammary analogue secretory carcinoma; salivary gland carcinomas; mammaglobin; ETV-6.

Contributions: OB and CG contributed equally.

Conflict of interest: the authors declare no potential conflict of interest.

Received for publication: 27 March 2017.

Revision received: 27 July 2017.

Accepted for publication: 17 August 2017.

This work is licensed under a Creative Commons Attribution NonCommercial 4.0 License (CC BY-NC 4.0).

©Copyright O. Bissinger *et al.*, 2017
Licensee PAGEPress, Italy
Rare Tumors 2017; 9:7162
doi:10.4081/rt.2017.7162

Immunohistochemistry

Immunohistochemistry was performed on 3 µm sections derived from formalin-fixed paraffin-embedded (FFPE) samples. Samples were immunohistochemically stained by using the Ventana Benchmark system (Roche, Basel, Switzerland) according to the manufacturer's protocol. Antibodies against cytokeratin 5/6 (CK5/6; 1:50, Dako; Hamburg, Germany), cytokeratin 7 (CK7; 1:150, Zytovision, Bremerhaven, Germany), cytokeratin 14 (CK14; 1:300, DC Systems, Hamburg, Germany), p53 (1:200; Dako, Hamburg, Germany), S100 (1:6000, Dako, Hamburg, Germany), estrogen receptor and progesterone receptor (each 1:20, DC Systems, Hamburg, Germany), Her2/neu (1:300, Dako, Hamburg, Germany), mammaglobin (1:100, Menarini Diagnostics, Berlin, Germany), muc 4 (1:300, Santa Cruz, Heidelberg, Germany), prostate-specific antigen (PSA; 1:3000, Dako, Hamburg, Germany), androgen receptor (AR; 1:1; CellMarque, Darmstadt, Germany) and Ki67/MIB-1 (1:50, Dako, Hamburg, Germany) were applied.

Fluorescence *in situ* hybridization

For fluorescence *in situ* hybridization (FISH), the *ETV6* Dual Color Breakapart probe (Zytovision, Bremerhaven, Germany) was used according to the manufacturer's protocol. Hybridized slides were examined with an Zeiss AxioScope fluores-

cence microscope via a 10× and 63× oil objective. One hundred randomly selected non-overlapping tumour cell nuclei were examined for the presence of colocalized (yellow) or translocated (green and red) signals.

Results

Clinical data and follow-up data

This study includes three cases of MASC treated at the Klinikum rechts der Isar (Munich, Germany) and the Department of Otolaryngology (Lübeck Germany), including two male and one female patient (Table 1). The age of patients ranged from 34 to 74 years. Tumours were either located in the parotid region (2 cases: C2 and C3) or in the mouth floor (C1) arising from the minor salivary glands. Interestingly, one case of parotid MASC was located close to an additional pleomorphic adenoma (C2). Clinical symptoms were variable, mainly depending on the tumour location. Both parotid cases presented with (painless or painful) swelling and tumour history of up to one year. The mucosal-associated tumour nodule at the floor of the mouth caused increasing pain and was therefore resected one month after the onset of pain. All tumours were small (ranging from 0.8 cm to 2.2 cm, all pT1) and clinically sharply demarcated. Tumours were radically resected and, in two cases, additional neck dissection of the ipsilateral levels (for C1: levels I-III, for C3: levels I-IV) was performed. No adjuvant therapy was applied. Follow-up was carried out for all patients and, to date (up to 26 months),

no loco-regional recurrence or metastases have occurred.

Histopathological, immunohistochemical and molecular profile of Mammary analogue secretory carcinoma

All three tumours displayed a characteristic morphological pattern: well-circumscribed, at least partially encapsulated tumour nodules consisting of epithelial nests arranged in tubular and tubulocystic, papillary and cribriform structures with sometimes intermingled foamy histiocytes and abundant intraluminal (Alcian-PAS-positive) secretory material (Figure 1). Tumour cells showed low cellular pleomorphism, a moderate cell size with a mostly polygonal shape, eosinophilic cytoplasm and oval to round nuclei with focally vacuolated karyoplasma. No or only very few typical mitosis were seen. Necrotic areas were not detectable. Diastase-resistant PAS-positive granula were absent. Immunohistochemically (Figure 1), all tumors displayed strong staining for CK7 and moderate to strong positivity for S100 and mammaglobin (Figure 1). Focal positivity for CK5/6 in all cases and moderate to strong positivity for muc-4 in two cases were additionally detected. The prolifera-

tion rate was calculated up to 10% (C1: 5%, C2: 10%, C3: 5%). In contrast, CK14, hormone receptors (estrogen and progesterone receptor), Her2/neu, p53, prostate-specific antigen (PSA) and androgen receptor (AR) were consistently negative in all three cases (Supplementary Figure S1). All three cases showed translocation of the ETV6 gene locus in up to 60% of tumour cell nuclei (Supplementary Figure S1). A complete overview of the staining profile of each MASC case can be found in Supplementary Table S1.

Discussion

MASC of the salivary gland is a recently described, distinct, new entity that has just been established in the new WHO classification of head and neck tumors (4th edition, 2017). We present three cases of MASC harbouring the typical ETV6 rearrangement and showing a homogeneous immunohistochemical profile including strong positivity for CK7, S100, partially for muc-4 and mammaglobin.²¹ Interestingly, as previously described in the literature,^{21,22} no expression of hormone receptors [estrogen (ER) and progesterone (PR) receptor] or Her2/neu was detectable;

Table 1. Clinical data of mammary analogue secretory carcinoma patients.

Case	Gender	Age	Localization	Size, cm	T-stage	N-stage	Recurrence
1	M	34	Mouth floor	0.8	pT1	pN0	No
2	F	74	Parotid region	2.2	pT1	cN0	No
3	M	37	Parotid region	1.5	pT1	pN0	No

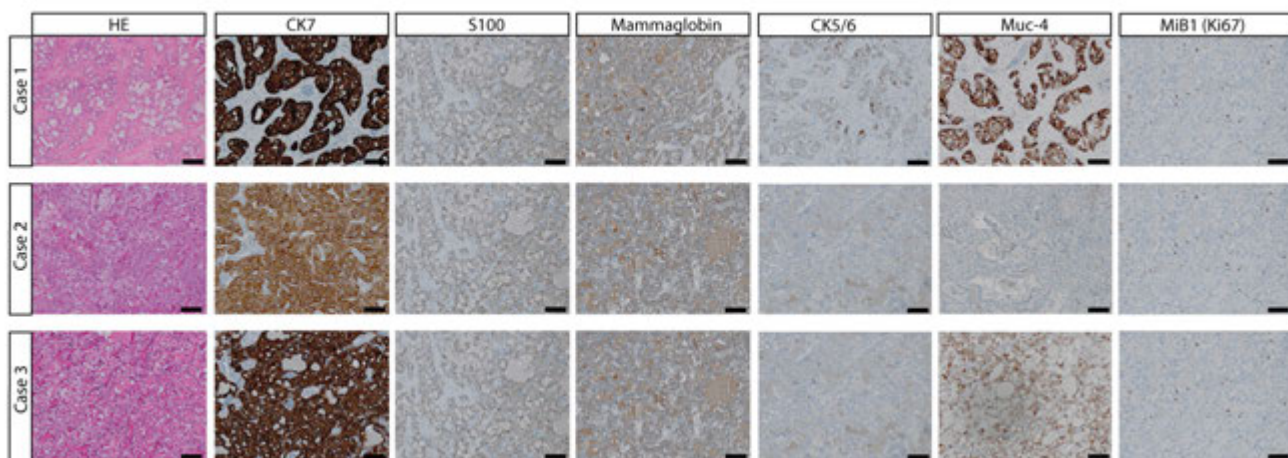


Figure 1. Haematoxylin and eosin staining and relevant immunohistochemical markers in mammary analogue secretory carcinoma. Scale bars: 100 µm.

Her2/neu overexpression (or Her2/neu gene amplification) is a potential therapeutic option that has been subject of controversial discussion in secretory mammary carcinoma, which is the counterpart of MASC in the breast.^{23,24} The focal positivity of CK5/6 of MASC combined with its negativity for hormone receptors and Her2/neu might therefore point to its more basal-like phenotype. Because of its eosinophilic, partially cystic appearance with the formation of glandular and tubular structures, MASC might easily be misinterpreted, especially in small biopsies.²⁵ As main differential diagnostic considerations include benign and malignant salivary gland neoplasms with various grade of malignancy, it is essential to consider the right diagnosis already in small biopsies. Among the most common salivary gland neoplasms that simulates MASC especially pleomorphic adenoma, mucoepidermoid carcinoma, acinus cell carcinoma, salivary duct carcinoma and adenocarcinoma not other specified are found.^{15,26,27} MASC can easily mimic pleomorphic adenoma (PA) both clinically and histologically. Main causes for misleading diagnosis of PA are i) often sharply demarcated growth pattern of MASC and ii) histologically tubulocystic appearance as well as diffuse S100 positivity. However, PA can be securely ruled out by staining for mammaglobin and/or muc-4, as pleomorphic adenomas are reported to be negative for these markers.²⁸ Mucoepidermoid carcinoma offers some potential for misdiagnosis, as MASC can focally be positive for CK5/6 and therefore mimic typical squamoid nests of mucoepidermoid carcinoma. However, mucoocytes as a key finding in mucoepidermoid carcinomas are not present in MASC. In addition, the majority of mucoepidermoid carcinomas harbour the specific translocation of the mastermind-like2 (MAML2) gene locus.^{29,30} Acinus cell carcinoma, probably the most common misdiagnosis of MASC, is characterized by diastase PAS-resistant zymogen granula and an immunohistochemical profile that includes negative immunohistochemical staining for mammaglobin and S100.^{2,31} Cases of MASC with a more apocrine appearance can be separated from salivary duct carcinoma by the immunohistochemical staining of androgen receptor, PSA and Her2/neu.³²⁻³⁵ Finally, the diagnosis of adenocarcinoma not other specified (adenocarcinoma NOS) should be a diagnosis of exclusion and considered carefully as these tumours are high-grade neoplasms and diagnosis at biopsy therefore might provoke a more aggressive therapeutic approach.^{5,36,37}

However, if the immunohistochemical

profile is inconsistent, FISH analysis for the rearrangement of the ETV6 gene locus will help to diagnose MASC correctly. According to literature, ETV translocation to date seems to be specific for MASC,³⁸ approximately 70% to 100% (as reported in our three cases) of MASC show typical ETV6 translocation.³⁸⁻⁴¹ Interestingly, one of our cases (C2) showed a neighbouring pleomorphic adenoma, a finding that is not unknown for MASC,²⁶ and so clinicians should be aware that multinodular lesions in salivary glands might harbour two different entities.

Conclusions

In conclusion, MASC is an important molecularly defined entity of the salivary gland with low-grade malignant potential in the majority of cases reported to date. Correct diagnosis is essential for appropriate treatment and will help to provide better information about this new type of potentially low-grade malignant salivary gland neoplasm.

References

- Skalova A, Vanecek T, Sima R, et al. Mammary analogue secretory carcinoma of salivary glands, containing the ETV6-NTRK3 fusion gene: a hitherto undescribed salivary gland tumor entity. *Am J Surg Pathol* 2010;34:599-608.
- Bishop JA, Yonescu R, Batista D, et al. Most nonparotid acinic cell carcinomas represent mammary analog secretory carcinomas. *Am J Surg Pathol* 2013;37:1053-7.
- Hindocha N, Wilson MH, Pring M, et al. Mammary analogue secretory carcinoma of the salivary glands: a diagnostic dilemma. *Br J Oral Maxillofac Surg* 2017;55:290-2.
- Serrano-Arevalo ML, Mosqueda-Taylor A, Dominguez-Malagon H, Michal M. Mammary analogue secretory carcinoma (MASC) of salivary gland in four Mexican patients. *Med Oral Patol Oral Cir Bucal* 2015;20:e23-9.
- Bishop JA. Unmasking MASC: bringing to light the unique morphologic, immunohistochemical and genetic features of the newly recognized mammary analogue secretory carcinoma of salivary glands. *Head Neck Pathol* 2013;7:35-9.
- Din NU, Fatima S, Kayani N. Mammary analogue secretory carcinoma of salivary glands: a clinicopathologic study of 11 cases. *Ann Diagnost*

Pathol 2016;22:49-53.

- Hwang MJ, Wu PR, Chen CM, et al. A rare malignancy of the parotid gland in a 13-year-old Taiwanese boy: case report of a mammary analogue secretory carcinoma of the salivary gland with molecular study. *Med Mol Morphol* 2014;47:57-61.
- Quattlebaum SC, Roby B, Dishop MK, et al. A pediatric case of mammary analogue secretory carcinoma within the parotid. *Am J Otolaryngol* 2015;36:741-3.
- Rastatter JC, Jatana KR, Jennings LJ, Melin-Aldana H. Mammary analogue secretory carcinoma of the parotid gland in a pediatric patient. *Otolaryngol Head Neck Surg* 2012;146:514-5.
- Woo J, Seethala RR, Sirintrapun SJ. Mammary analogue secretory carcinoma of the parotid gland as a secondary malignancy in a childhood survivor of atypical teratoid rhabdoid tumor. *Head Neck Pathol* 2014;8:194-7.
- Skalova A, Vanecek T, Majewska H, et al. Mammary analogue secretory carcinoma of salivary glands with high-grade transformation: report of 3 cases with the ETV6-NTRK3 gene fusion and analysis of TP53, beta-catenin, EGFR, and CCND1 genes. *Am J Surg Pathol* 2014;38:23-33.
- Hindocha N, Wilson MH, Pring M, et al. Mammary analogue secretory carcinoma of the salivary glands: a diagnostic dilemma. *Br J Oral Maxillofac Surg* 2017;55:290-2.
- Chiosea SI, Griffith C, Assaad A, Seethala RR. Clinicopathological characterization of mammary analogue secretory carcinoma of salivary glands. *Histopathology* 2012;61:387-94.
- Bishop JA, Yonescu R, Batista DA, et al. Cytopathologic features of mammary analogue secretory carcinoma. *Cancer Cytopathol* 2013;121:228-33.
- Stevens TM, Kovalovsky AO, Velosa C, et al. Mammary analog secretory carcinoma, low-grade salivary duct carcinoma, and mimickers: a comparative study. *Modern Pathol* 2015;28:1084-100.
- Marchio C, Irvani M, Natrajan R, et al. Mixed micropapillary-ductal carcinomas of the breast: a genomic and immunohistochemical analysis of morphologically distinct components. *J Pathol* 2009;218:301-15.
- Majewska H, Skalova A, Stodulski D, et al. Mammary analogue secretory carcinoma of salivary glands: a new entity associated with ETV6 gene rearrangement. *Virchows Arch* 2015;466:245-54.

18. Tognon C, Knezevich SR, Huntsman D, et al. Expression of the ETV6-NTRK3 gene fusion as a primary event in human secretory breast carcinoma. *Cancer Cell* 2002;2:367-76.
19. Skalova A, Vanecek T, Simpson RH, et al. Mammary Analogue secretory carcinoma of salivary glands: molecular analysis of 25 ETV6 gene rearranged tumors with lack of detection of classical ETV6-NTRK3 fusion transcript by standard RT-PCR: report of 4 cases harboring ETV6-X gene fusion. *Am J Surg Pathol* 2016;40:3-13.
20. Simpson RH, Skalova A, Di Palma S, Leivo I. Recent advances in the diagnostic pathology of salivary carcinomas. *Virchows Arch* 2014;465:371-84.
21. Shah AA, Wenig BM, LeGallo RD, et al. Morphology in conjunction with immunohistochemistry is sufficient for the diagnosis of mammary analogue secretory carcinoma. *Head Neck Pathol* 2015;9:85-95.
22. Jung MJ, Song JS, Kim SY, et al. Finding and characterizing mammary analogue secretory carcinoma of the salivary gland. *Korean J Pathol* 2013;47:36-43.
23. Jacob JD, Hodge C, Franko J, et al. Rare breast cancer: 246 invasive secretory carcinomas from the National Cancer Data Base. *J Surg Oncol* 2016;113:721-5.
24. Lae M, Freneaux P, Sastre-Garau X, et al. Secretory breast carcinomas with ETV6-NTRK3 fusion gene belong to the basal-like carcinoma spectrum. *Modern Pathol* 2009;22:291-8.
25. Oza N, Sanghvi K, Shet T, et al. Mammary analogue secretory carcinoma of parotid: Is preoperative cytological diagnosis possible? *Diagn Cytopathol* 2016;44:519-25.
26. Petersson F, Michal M, Kazakov DV, et al. A new hitherto unreported histopathologic manifestation of mammary analogue secretory carcinoma: "masked MASC" associated with low-grade mucinous adenocarcinoma and low-grade in situ carcinoma components. *Appl Immunohistochem Mol Morphol* 2016;24:e80-5.
27. Skalova A, Michal M, Simpson RH. Newly described salivary gland tumors. *Modern Pathol* 2017;30:S27-S43.
28. Hamada T, Matsukita S, Goto M, et al. Mucin expression in pleomorphic adenoma of salivary gland: a potential role for MUC1 as a marker to predict recurrence. *J Clin Pathol* 2004;57:813-21.
29. Noda H, Okumura Y, Nakayama T, et al. Clinicopathological significance of MAML2 gene split in mucoepidermoid carcinoma. *Cancer Sci* 2013;104:85-92.
30. Okumura Y, Miyabe S, Nakayama T, et al. Impact of CRTC1/3-MAML2 fusions on histological classification and prognosis of mucoepidermoid carcinoma. *Histopathology* 2011;59:90-7.
31. Chiosea SI, Griffith C, Assaad A, Seethala RR. The profile of acinic cell carcinoma after recognition of mammary analog secretory carcinoma. *Am J Surg Pathol* 2012;36:343-50.
32. Butler RT, Spector ME, Thomas D, et al. An immunohistochemical panel for reliable differentiation of salivary duct carcinoma and mucoepidermoid carcinoma. *Head Neck Pathol* 2014;8:133-40.
33. Masubuchi T, Tada Y, Maruya S, et al. Clinicopathological significance of androgen receptor, HER2, Ki-67 and EGFR expressions in salivary duct carcinoma. *Int J Clin Oncol* 2015;20:35-44.
34. Fan CY, Wang J, Barnes EL. Expression of androgen receptor and prostatic specific markers in salivary duct carcinoma: an immunohistochemical analysis of 13 cases and review of the literature. *Am J Surg Pathol* 2000;24:579-86.
35. Udager AM, Chiosea SI. Salivary duct carcinoma: an update on morphologic mimics and diagnostic use of androgen receptor immunohistochemistry. *Head Neck Pathol*. 2017 [Epub ahead of print].
36. Eppsteiner RW, Fowlkes JW, Anderson CM, et al. Aggressive salivary malignancies at early stage: outcomes and implications for treatment. *Ann Otol Rhinol Laryngol* 2017;126:525-9.
37. Huang AT, Tang C, Bell D, et al. Prognostic factors in adenocarcinoma of the salivary glands. *Oral Oncol* 2015;51:610-5.
38. Stevens TM, Parekh V. Mammary analogue secretory carcinoma. *Arch Pathol Lab Med* 2016;140:997-1001.
39. Khurram SA, Sultan-Khan J, Atkey N, Speight PM. Cytogenetic and immunohistochemical characterization of mammary analogue secretory carcinoma of salivary glands. *Oral surg Oral Med Oral Pathol Oral Radiol* 2016;122:731-42.
40. Ni H, Zhang XP, Wang XT, et al. Extended immunologic and genetic lineage of mammary analogue secretory carcinoma of salivary glands. *Human Pathol* 2016;58:97-104.
41. Said-Al-Naief N, Carlos R, Vance GH, et al. Combined DOG1 and mamoglobin immunohistochemistry is comparable to ETV6-breakapart Analysis for differentiating between papillary cystic variants of acinic cell carcinoma and mammary analogue secretory carcinoma. *Int J Surg Pathol* 2017;25:127-40.