

**CASE REPORT**

WILEY

Successful treatment of a paravalvular leak with balloon cracking and valve-in-valve TAVR

Hendrik Ruge MD^{1,2} | Magdalena Erlebach MD^{1,2} | Eveline Lieberknecht MD^{1,2} | Rüdiger Lange MD, PhD^{1,2}

¹Department of Cardiovascular Surgery, German Heart Center, TUM, INSURE (Institute for Translational Cardiac Surgery), Munich, Germany

²German Heart Center Munich, Department of Cardiovascular Surgery, TUM, Munich, Germany

Correspondence

Hendrik Ruge, Deutsches Herzzentrum München, Klinik für Herz- und Gefäßchirurgie, Lazarettstrasse 36, 80636 München/Germany, Email: ruge@dhm.mhn.de

Abstract

Transcatheter heart valve implantation into degenerated bioprosthetic valves (ViV-THV implantation) has become an established procedure for high risk patients. In general, paravalvular leak (PVL) is a contraindication for valve-in-valve-TAVR (ViV-TAVR). Herein, we report on a 81-year-old patient presenting with acute heart failure for a failing aortic bioprosthesis (Medtronic Mosaic 27 mm). Intraoperative transesophageal echocardiography during urgent ViV-TAVR revealed a PVL previously not detected. After transfemoral implantation of a 26 mm-Evolut-R, balloon-fracturing of the bioprosthetic ring was performed using a 24 mm True Dilatation balloon for treatment of the PVL. Afterward, left ventricular to aortic peak-to-peak pressure gradient measured 2–4mmHg. Transesophageal echocardiography merely revealed trace PVL. Aortic root angiography showed no PVL. At discharge, echocardiography measured a transprosthetic mean gradient of 5mmHg detecting no PVL. Intentional ring-fracturing of an aortic valve prostheses may prove not only to be effective in lowering transvalvular gradients after valve-in-valve-TAVR, but may also be a tool to treat PVL alongside degenerated surgical aortic bioprostheses in certain patients.

1 | INTRODUCTION

Transcatheter heart valve implantation into degenerated bioprosthetic aortic valves (ViV-THV implantation) has become an established procedure for high-risk patients. Stenosis and valvular regurgitation of a bioprosthesis can be successfully treated achieving good hemodynamic results. The presence of a significant paravalvular leak (PVL) alongside an aortic valve bioprosthesis is a contraindication for ViV-THV implantation. Herein, we report on an effective treatment of a PVL using ViV-THV implantation in combination with bioprosthetic ring fracturing.

2 | CASE REPORT

A 81-year-old male patient was referred by helicopter transfer for acute heart failure. He had undergone bioprosthetic aortic valve replacement with a Mosaic 27 mm valve (Medtronic, Minneapolis, MN) and LIMA>LAD bypass grafting in 2010. Echocardiography had proven an impaired left ventricular ejection fraction of 35% and degeneration of the aortic valve prosthesis revealing both stenosis and transprosthetic regurgitation (Figure 1a,b). Furthermore, echocardiography measured severe pulmonary hypertension with a systolic pulmonary artery pressure of 67 mmHg. Decision was made for

This is an open access article under the terms of the Creative Commons Attribution-NonCommercial License, which permits use, distribution and reproduction in any medium, provided the original work is properly cited and is not used for commercial purposes.

© 2019 The Authors. *Catheterization and Cardiovascular Interventions* published by Wiley Periodicals, Inc.

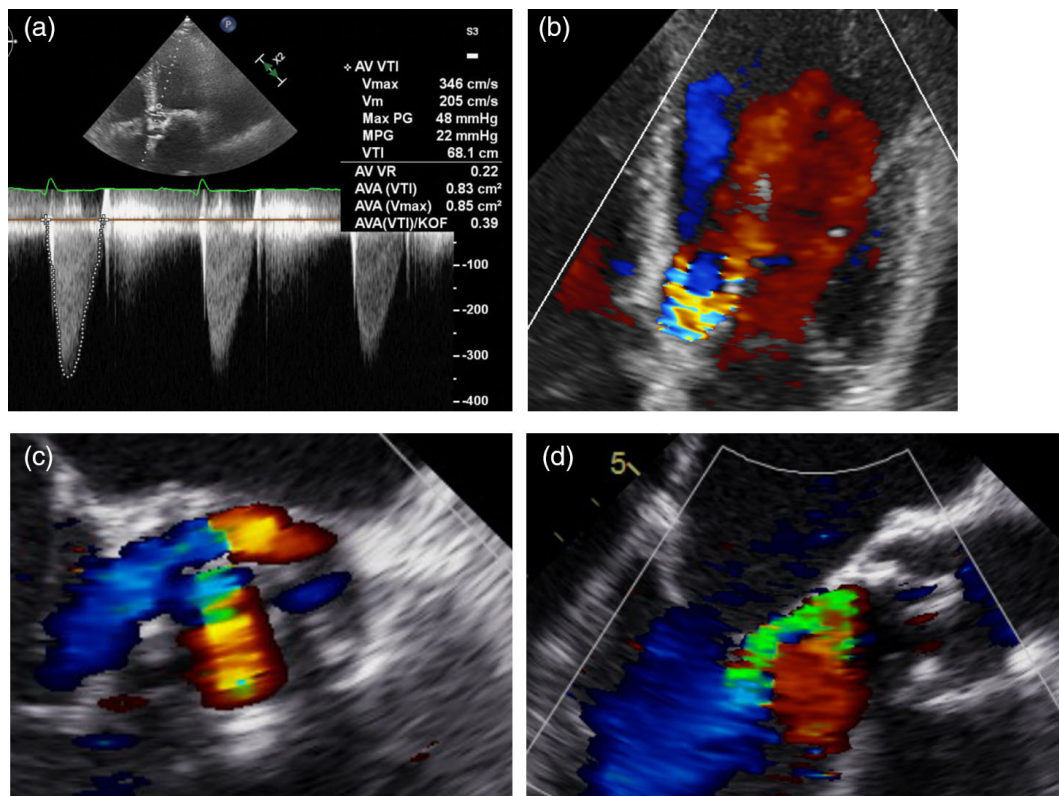


FIGURE 1 Transthoracic echocardiography revealing both prosthetic aortic valve stenosis and regurgitation (a, b). Intraoperative transesophageal echocardiography showed PVL alongside Mosaic prosthesis (c, d)

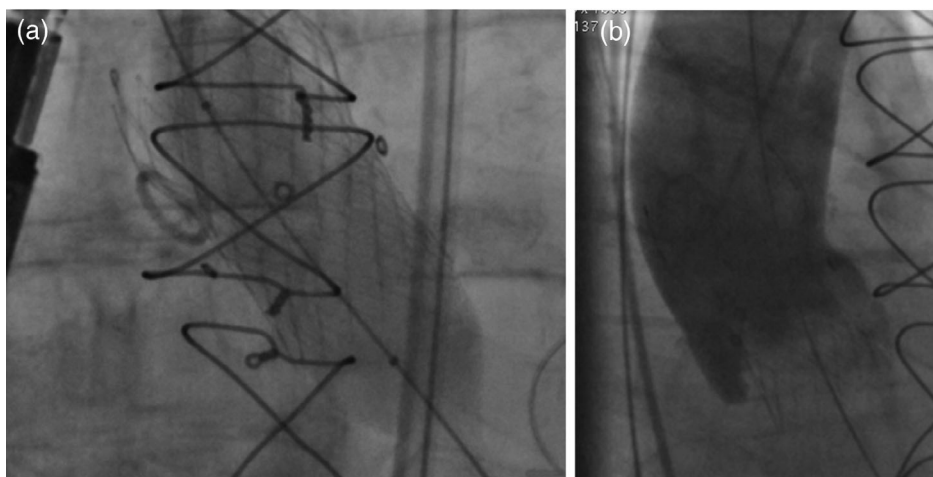


FIGURE 2 Following bioprosthetic ring fracturing (a) aortic root angiography excluded PVL (b)

ViV-THV implantation due to the acute heart failure, the severe pulmonary hypertension and a patent LIMA graft. The STS risk of mortality score was 1.7% and the logistic EuroSCORE was 17.8%. Preoperative computerized tomography measured a perimeter of 72 mm, an area of 405 mm² and 21 x 24 mm bioprosthetic ring inner-diameters. Neither the LVOT, nor the native anulus showed calcifications. In accordance to the CT measurements, the “Valve-in-Valve”-App indicates a true inner diameter of 22 mm for the 27 mm Mosaic valve. Following our institutional's protocol for

valve-in-valve interventions, a supraannular transcatheter heart valve was selected.

Intraoperative transesophageal echocardiography (TEE) newly revealed two PVLs alongside the bioprosthesis (Figure 1c,d). After reassessment of the patient's clinical situation and considering the new finding, we decided to continue with the interventional therapy and perform a bioprosthetic ring fracturing maneuver for PVL treatment. After transfemoral implantation of a 26 mm Evolut R (Medtronic, Minneapolis, MN), balloon valvuloplasty and cracking of

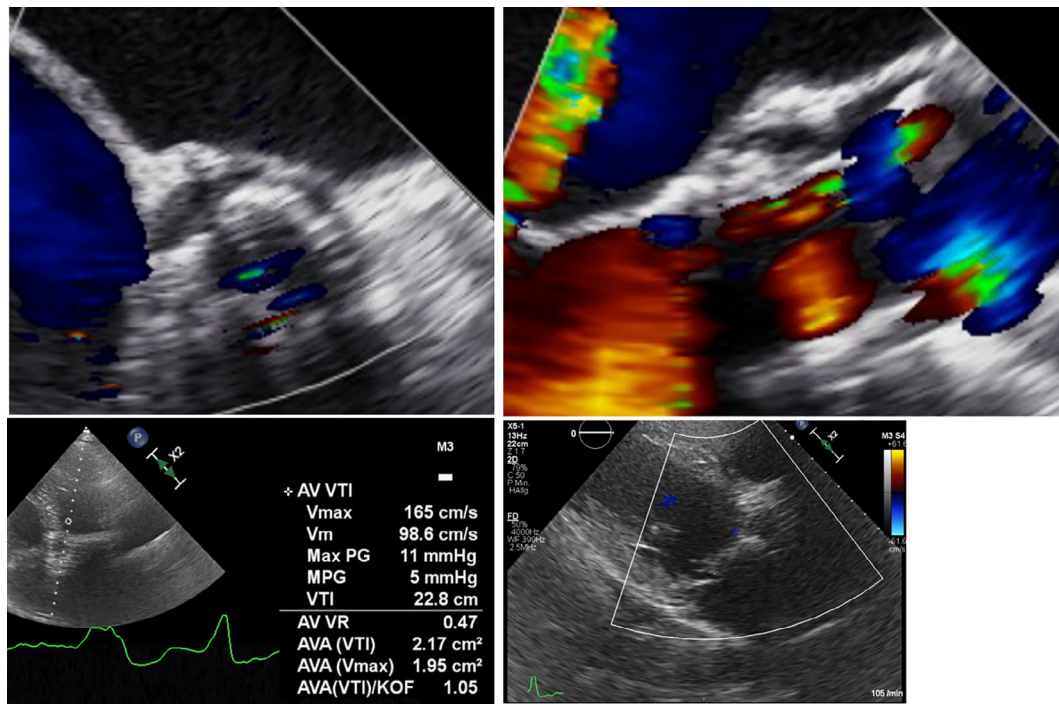


FIGURE 3 Intraoperative TEE merely showed trace PVL (a, b) after valve-in-valve-THV implantation. Transthoracic echocardiography measured 5 mmHg mean transprosthetic gradient without valvular or paravalvular regurgitation (c, d)

the bioprosthetic ring was performed using a 24 mm TRUE DILATION balloon (Bard Peripheral Vascular, Tempe, AZ). Without recording a baseline pressure gradient, a single inflator was used applying an inflation pressure above 15 atm (Video S1). A sudden pressure decrease indicated successful bioprosthetic ring fracturing (Figure 2a). Afterward, left ventricular to aortic peak-to-peak pressure gradient measured 2–4 mmHg. Transesophageal echocardiography revealed trace PVL (Figure 3a,b). Aortic root angiography showed no PVL (Figure 2b, Video S2). Echocardiography prior to discharge confirmed the intraoperative findings (Figure 3c,d).

3 | DISCUSSION

Valve-in-valve-THV implantation has become an established procedure for degeneration of aortic valve bioprostheses.¹ Currently, first small case series aim for lowering transvalvular gradients using balloon fracturing of small aortic bioprosthetic rings after valve-in-valve-THV implantation.^{2,3} In general, balloon fracturing of bioprosthetic rings is performed using noncompliant high-pressure balloons. The appropriate balloon size is usually slightly larger than the inner prosthetic ring diameter and can be determined from the computed tomography performed for procedural planning or supportive tools like the “Valve in Valve”-App. There is ongoing discussion on the timing of bioprosthetic ring fracturing. We favor to implant the THV into the aortic bioprosthesis followed by high-pressure balloon fracturing of the prosthetic ring. Thereby, severe aortic regurgitation with potential

hemodynamic instability is avoided. The influence on THV durability or leaflet damage following high pressure post-dilatation on the other hand remains unclear and has not been studied yet.

In general, patients suffering from degeneration of an aortic bioprosthesis and who show evidence of a PVL are candidates for surgical aortic valve replacement. The presence of two separate locations of PVL with each one rather small in dimension encouraged us in the urgent situation to use bioprosthetic ring fracturing not to primarily improve the transprosthetic gradient but to diminish or eliminate the paravalvular leakage. We agreed that a low implantation of the Evolut R prosthesis would not grant a supraannular leaflet position and thereby impair the hemodynamic outcome. Furthermore, we doubted that the radial forces even of a low implanted THV would seal the PVL without additional post-dilatation.

Addressing a PVL alongside an aortic bioprosthesis with valve-in-valve TAVR is reported only once using a Sapien XT valve (Edwards Lifesciences, Irvine, CA).⁴ To the best of the author's knowledge, this is the first report of successful treatment of a PVL alongside an aortic bioprosthesis using valve-in-valve-THV implantation with a self-expandable valve followed by bioprosthetic ring fracture.

4 | CONCLUSION

Intentional ring fracturing of aortic valve prostheses may prove not only to be effective in lowering transvalvular gradients after valve-in-valve-THV implantation. In selected patients it might be a tool to

treat paravalvular leaks alongside degenerated surgical aortic bioprostheses. At least two parameters have to be taken into account. First, the model of the aortic bioprosthesis determines if the ring can be fractured. Second, the PVL morphology and expansion will impact a successful PVL sealing using ViV-THV implantation followed by bioprosthetic ring fracturing. The effectiveness of this therapy and the determination of suitable pathologies have to be evaluated in further studies.

CONFLICT OF INTEREST

The authors declare no potential conflict of interest.

ORCID

Hendrik Ruge  <https://orcid.org/0000-0001-6886-3660>

REFERENCES

1. Bleiziffer S, Erlebach M, Simonato M, et al. Incidence, predictors and clinical outcomes of residual stenosis after aortic valve-in-valve. *Heart*. 2018;104(10):828-834.
2. Allen KB, Chhatriwalla AK, Cohen DJ, et al. Bioprosthetic valve fracture to facilitate transcatheter valve-in-valve implantation. *Ann Thorac Surg*. 2017;104(5):1501-1508.
3. Chhatriwalla AK, Allen KB, Saxon JT, et al. Bioprosthetic valve fracture improves the hemodynamic results of valve-in-valve transcatheter aortic valve replacement. *Circ Cardiovasc Interv*. 2017;10(7):e005216.
4. Loyalka P, Montgomery KB, Nguyen TC, Smalling RW, Howe M, Rajagopal K. Valve-in-valve transcatheter aortic valve implantation: a novel approach to treat paravalvular leak. *Ann Thorac Surg*. 2017;104(4):e325-e327.

SUPPORTING INFORMATION

Additional supporting information may be found online in the Supporting Information section at the end of this article.

How to cite this article: Ruge H, Erlebach M, Lieberknecht E, Lange R. Successful treatment of a paravalvular leak with balloon cracking and valve-in-valve TAVR. *Catheter Cardiovasc Interv*. 2020;95:859-862. <https://doi.org/10.1002/ccd.28644>