

Kinderklinik und Poliklinik der Technischen Universität München  
(Kommissarischer Direktor: Univ.-Prof. Dr. Dr. J. Peters)

Comparison and Classification of short rib polydactyly dysplasia group

Samir Jarrar

Vollständiger Abdruck der von der Fakultät für Medizin der Technischen Universität München zur Erlangung des akademischen Grades eines

Doktors der Medizin

genehmigten Dissertation.

Vorsitzender: Univ.-Prof. Dr. D. Neumeier

Prüfer der Dissertation:

1. Univ.-Prof. Dr. Dr. B. Pontz
2. Univ.-Prof. Dr. R.M. Oberhoffer

Die Dissertation wurde am ...30.07.2002.... bei der Technischen Universität München eingereicht und durch die Fakultät für Medizin am ...09.04.2003....angenommen.

## Comparison and Classification of short rib polydactyly dysplasia group

1.	Introduction	1
1.1.	SRP dysplasia group: descriptions and definitions	3
1.2.	Including criteria of SRP dysplasia group	4
1.3.	Incidence of SRP dysplasia group	5
2.	Is a diagnostic manual for the short rib polydactyly dysplasia group useful?	6
3.	Methods and materials	7
3.1.	Abbreviation	8
4.	Short rib polydactyly dysplasia group	
4.1.	SRPS Type 1 Saldino-Noonan	9
4.1.1.	Morphological aspects	9
4.1.2.	Description of radiologic findings	11
4.1.3.	Description of histological findings	13
4.2.	SRPS Type 2 Majewski	15
4.2.1.	Morphological aspects	15
4.2.2.	Description of radiologic findings	17
4.2.3.	Description of histological findings	18
4.2.4.	Overlapping with OFD syndrome	19
4.3.	SRPS Type 3 Verma-Naumoff	20
4.3.1.	Morphological aspects	20
4.3.2.	Description of radiologic findings	22
4.3.3.	Description of histological findings	23
4.4.	SRPS Type 4 Beemer-Langer	25
4.4.1.	Morphological aspects	25
4.4.2.	Description of radiologic findings	26
4.4.3.	Description of histological findings	27

4.5.	Asphyxiating thoracic dysplasia	28
4.5.1.	Morphological aspects	28
4.5.2.	Description of radiologic findings	30
4.5.3.	Description of histological findings	31
4.6.	Ellis van Creveld dysplasia	32
4.6.1.	Morphological aspects	32
4.6.2.	Description of radiologic findings	34
4.6.3.	Description of histological findings	35
5.	Discussion	36
5.1.	Differences and similarities of SRP dysplasia group	36
5.2.	Interpretation of clinical aspects	41
5.3.	Interpretation of genetic aspects	43
5.4.	Intrauterine sonographic diagnosis	45
5.5.	Classification of SRP dysplasia group	48
6.	Summary	49
7.	References	50
8.	Tables	62
9.	Curriculum vitae	65
10.	Acknowledgment	66

## 1. Introduction

Osteochondrodysplasias are hereditary dysfunctions of the enchondral ossification with a decreased longitudinal bone growth.

The short rib polydactyly dysplasia group is one aspect of lethal osteochondrodysplasias.

In the following thesis we order and classify the different types of SRP dysplasia group according to the International classification of osteochondrodysplasias, edited by the International Working group on bone dysplasias in 1992.

Osteochondrodysplasias is the subject for all kinds of skeletal diseases. The history of osteochondrodysplasias began with the first description of achondrogenesis by Parenti in 1936 (Parenti,1936), although the first cases of osteogenesis imperfecta had already been described by Vrolik in 1848.

Until recently, achondroplasia, formerly called chondrodystrophy, was the only diagnosis for all kinds of dwarfed newborns until thanatophoric dysplasia was first recognized as a separate entity (Maroteaux et al., 1967). Since then many different chondrodysplasias have been described.

The first classifications of osteochondrodysplasias was edited at the Paris classification of constitutional disorders of bone in 1972, and was first revised in 1983.

It was subjected to its 2nd revision by the international working group on bone dysplasias in Bad Honnef in 1991 (Beighton et al., 199 ).

Osteochondrodysplasias are divided in three main groups:

The first and most voluminous group is the one of "defects of the tubular (and flat) bones and/or axial skeleton".

The second group is the one of „disorganized development of cartilagenous and fibrous components of the skeleton“.

The last one is the group of „idiopathic osteolysis“.

The first group can be subdivided into non-lethal and lethal forms of Osteochondrodysplasias.

The short rib polydactyly dysplasia group is part of the first group and contains both forms: lethal forms like the short rib polydactyly syndromes type 1-4, and the sometimes non-lethal forms like Asphyxiating thoracic dysplasia and Ellis van Creveld syndrome.

Recently, this field became more and more confused by the recognitions of a large number of different symptoms, which has similar morphological aspects and differ only in minor conditions. These different symptoms, which contain a lot of the same conditions and a lot of different ones, cause many problems, raising questions of heterogeneity versus variability and nomenclature.

Different descriptions have been summarized under identical names and the same descriptions have been given different names. In the past decades modest but definite advances in the classification of neonatal osteochondrodysplasias have been made.

Thanks to common technologies such as radiology, and histology, it should be easier to differentiate between subtypes of one syndrome. Methods like genetic examinations, and molecular biology are still difficult to handle, and too expensive. The best advances could be made by simple comparison of literature. This way is today facilitated by modern communication methods like the Internet, that allow for a fast overview to literature. Therefore this is the way we compare the different types of short rib polydactyly dysplasia group.

In this work the subjects SRP syndrome and SRP dysplasia group are used as synonyms.

One of the problems of the classification of osteochondrodysplasias is the small number of cases and therefore the paucity of clinical material present at any one medical center, causing difficulties in ultimate classification.

## 1.1. SRP dysplasia group: descriptions and definitions

The short rib polydactyly syndrome was first described by Majewski in 1971.

In 1974 Spranger et al. introduced the term „short rib polydactyly syndrome“ (SRPS) to describe two conditions sharing some manifestations, including short ribs, with Jeune syndrome. Short ribs are present in all types of SRPS. Meanwhile polydactyly has been described in many, but not all cases.

Since the first description by Majewski, a lot of similar symptoms have been described, which differ in minor or major aspects and were named after their first-describers. We will list briefly the six different types of short rib polydactyly dysplasia group. Further information can be found in the actual item.

The first description of SRPS was by Majewski in 1971, followed by the description of a different type by Saldino and Noonan in 1972.

The 3th type of this group was described by Verma and Naumoff, and the type 4 by Beemer and Langer in 1983.

The Asphyxiating thoracic dysplasia was first described by Jeune in 1955 and is thus called Jeune syndrome. The last one is the well defined Ellis van Creveld syndrome, first described in 1940, although called chondroectodermal dysplasia.

All these 6 different types form the group of short rib polydactyly dysplasia.

SRP syndrome is what is known as an autosomal recessive disease that has in common severely shortened ribs, short limbs, and postaxial polydactyly. Other more variable findings are anomalies of larynx, kidneys, central nervous systems, lungs and heart. More details can be found in the actual item.

## 1.2. Includings criteria of SRP dysplasia group

The nomenclature of the short rib polydactyly syndrome has developed over years and is still confusing. It is difficult to exclude certain related symptoms of SRP dysplasia group because there are many and they are very different.

The classification is based on radiodiagnostic criteria, grouping morphologically similar disorders and intending to facilitate the recognition of specific entities.

It follows the International classification of osteochondrodysplasias, edited by the International Working group on bone dysplasias in 1992.

Though the association of dwarfism, narrow chest, and polydactyly is well known in the literature, especially by the Ellis van Creveld and Jeune syndrome, the SRPS began only recently to be delineated in more detail. A lot of similar syndromes were described in literature, claiming to have their own nosologic individuality. It is impossible to mention exactly all SRP syndromes erroneously claimed to be an separate syndrome and the right entity, but we will mention some of them, as example how of confusing the this materia is, without classification.

There was in 1973 the description by Le Marec et al. resembling the patients with the Ellis van Creveld syndrome, but differing from this disorder is the more severe metaphyseal abnormalities of the tubular bones.

Yang et al. reported in 1980 a case of Saldino-Noonan syndrome with hydrops, polydactyly, hypoplastic left heart, small kidneys, and malrotated intestine, but better development of the femora, a peculiar deformity of the ulna and less markedly of the radius.

Three of these cases are listed in the Mainz Bone Dysplasia Registry. These skeletal anomalies differed so strikingly from those of type 1 that they claimed to form an separate entity.

This was supported by the observation of peculiar cytoplasmatic inclusions in chondrocytes of the resting cartilage (Yang et al.,1980), which have not been observed in bona fide cases of SRP Type 3 Verma-Naumoff.

In 1983 Beemer et al. reported a new short rib syndrome. They described two patients with features of SRP syndrome 4, including the narrow thorax, cleft lip, cardiac defect, malrotated intestine and other defects.

The claiming as an separate entity failed in all cases, as there were to few criteria to prove a new type of SRPS.

This is only one example for the confusing history of classification of the short rib polydactyly dysplasia group.

### 1.3. Incidence of SRP dysplasia group

Lethal osteochondrodysplasias is a rare form of skeletal diseases, whose frequency is estimated to be between 1:5000 and 1:11000. But the incidence rate for the different groups differ from author to author and is difficult to estimate because of the rare number of cases.

For example the prevalence of Jeune syndrome in Italy has been calculated on the order of 1/ 84.000 births (Matriacovo, 1986), in Austria it has been calculated to 1/100.000-130.000 live births (Oberklaid et al, 1977).

Another study, containing 350.000 births the prevalences, has given estimates for the following disorders: thanatophoric dysplasias: 1:115.000, achondrogenesis: 1:350.000, other lethal chondrodysplasias: 1:23.000 ( Orioli et al., 1986).

The frequency of lethal short-limbed dwarfism is said to be 1 in 19.000 (Curran et al.1974).

Thirty cases of SRP syndrome were found in 10.834 autopsy cases of fetuses and newborns in Japan. Among them was one case of short rib polydactyly syndrome type Majewski, which incidence is estimated to be one in 10.000 (Hayashi and Okamoto, 1984) .

All these different incidence rates show the variability of osteochondrodysplasias, depending on geographic aspects, genetic aspects and unknown variables. A part of osteochondrodysplasia might not be recognized at all.

Therefore it is not possible to edit exact dates on incidence of SRP syndromes.



## 2. Is a diagnostic manual for the short rib polydactyly dysplasia group useful?

A comparison of the short rib polydactyly dysplasia group should be the first step for an international obligatory manual for the description of osteochondrodysplasias. Our aim is to give an overview of SRP syndromes and to facilitate the recognition and differentiation of SRP syndromes, and to present a new classification scheme. Establishing an etiologic diagnosis in stillborn infants has great importance for the parents and family of the affected individuals.

At the time of being informed about a stillbirth or perinatal death the parents are in a state of shock, and may refuse the autopsy. The establishment of the right diagnosis is however just as important for the parents, with a view to their family planning. The establishment of the right diagnosis is often only possible by autopsy. The malformations of the short rib polydactyly dysplasia group are autosomal recessive disorders and thus have a 25 % recurrence risk, while other malformation syndromes such as trisomy 13 and trisomy 18 are sporadic events. To diagnose the right type of malformation is often difficult and this manual shall facilitate this difficult work.

The recognition of SRP syndrome is based on three main columns : the morphology, radiology and histology.

The former mixture of clinical , pathogenetic, and radiological criteria led to many inconsistencies and was of less diagnostic assistance.

Before autopsy is performed, photographs should be taken of the entire body anterior posterior view, both profiles, and close-up views of interesting aspects. Radiological assessment is very important for the diagnosis of short rib polydactyly syndrome but can be the source of many errors.

Complete radiological assessment includes: anterior posterior and lateral views of the skull, spine and chest, a lateral view of an ankle and anterior posterior views of an upper limb, a lower limb and the pelvis (Murray et al., 1988).

Histologic section should contain a part of every organ concerned. It should be described both anomalies and normal picture of one organ to complete a consistent histopathologic picture.

Clinical criteria such as age of onset and natural history are not used because of their variability and obviously they are not important for the exact classification.

The consideration would cause further confusion, and is irrelevant for classification of short rib dysplasia group. Despite the fact that we know very little about biochemical mechanism in the chondrodystrophic conditions, descriptive morphology is still important as it frequently leads to recognition of further cases and to more information of etiology.

Despite increasing progress in the field of biochemistry and molecular biology, pathogenetic knowledge is considered too rare to allow a causal classification. The rare information about gene localization, defective proteins involved, and mode of inheritance is no criteria for this classification, but it is listed if available. In this paper we compare most patients cases, presented in English and German journals in the past decades.

### 3. Methods and Materials

The comparison of SRP dysplasia group is based on the morphological aspects, radiology and histology. Most classification schemes currently in use are based on this combination. All parts of this method are common and easy to handle. With this method it should be possible to differentiate, compare and classify every case of SRP syndrome.

Special methods like measurement of calcospherite size and genetic examinations are complicated and expensive. We will mention some results of these methods, but because there is little material they are not considered relevant for this classification.

The usual methods are considered to be sufficient to classify the present types of SRP syndromes.

The intention of this work is to be a manual in the more and more complicated materiae of Osteochondrodysplasias.

The need for common standards of histopathologic examination in osteochondrodysplasias is essential for further classifications (Yang et al. 1986).

We hope to facilitate the recognition and differentiation of this syndrome. Although the absence of radiographic and cytogenetic data precluded the exact classification of many of the older observations. The difficulties in classification of the short rib polydactyly syndromes was discussed by Cherstvoy et al. in 1980 and raised many questions what would be the best way to find a standard classification scheme.

We compared the literature of over 100 cases of SRPS in more than 20 different international journals. The criterias are listed above in 1.2. .

The world wide web and especially [www.pubmed.de](http://www.pubmed.de) was very usefull in handling these large numbers of papers. Most articles were found under the search symbols „ Short rib polydactyly syndrome“, „ Osteochondrodysplasias“, or the authors name of one abstract or the name of the first-describers for example „ Majewski“ for SRPS type 1.

The next step was the comparison of the literature, which followed the recommendation of Beighton et al.,1992, grouping morphological aspects and mainly radiodiagnostic criteria and then histological findings of the skeletal and other organs. The results of these comparison can be found in the tables of chapter 8.

### 3.1. Abbreviations

ATD:	Asphyxiating thoracic dysplasia, another name for the Jeune Syndrome first described by Jeune et al.
EvC:	Ellis van Creveld dysplasia first described by Ellis and van Creveld
FGFR:	Fibroblast growth factor receptor
PAS:	Periodic acid shift
SRPS:	Short rib polydactyly syndrome used as synonyme for SRP dysplasia group
SRPS Type 1:	Short rib polydactyly syndrome, first described by Saldino and Noonan
SRPS Type 2:	Short rib polydactyly syndrome, first described by Majewski
SRPS Type 3:	Short rib polydactyly syndrome, first described by Verma and Naumoff
SRPS Type 4:	Short rib polydactyly syndrome, first described by Beemer and Langer

#### 4. Short rib polydactyly dysplasia group

##### 4.1. SRPS Type 1 Saldino-Noonan

###### 4.1.1. Morphological aspects

Cases with type 1 of SRP syndrome were first described by Saldino and Noonan in 1972, later by Richardson et al. (1977), and Rupprecht and Gurski (1982). Severe cases of SRPS Type 2 may have similar long bone changes, and originally it was thought that they represent the same condition, because of similar clinical and radiographic changes (Spranger et al. 1974; Sillence, 1980).

Patients with SRPS Type 1 are born prematurely, they are often stillborn or die shortly after birth. Cause of death is asphyxia.

Very short extremities and polydactyly are the main morphological aspects, polydactyly of feet is occurrent in 1/3 of all cases.

Autopsies show a varying combination of primary and secondary malformations. Primary defects are the short ribs, short extremities and postaxial polydactyly of hands and sometimes of feet. Further more the prominent abdomen, narrow chests, micromelia, and prenatal hypoplasia.

The condition is illustrated in Fig. 4.1.1.

The short ribs combined with hypoplastic lungs are responsible for asphyxia which is the cause of death in most cases.

Secondary malformations with more or less significant incidence rate are pulmonary dysplasia with ectatic A. pulmonalis, complex heart defects with great vessel defects, a short malrotated gut, cloacal defects with anal and urethral atresia and ambiguous genitalia.

Further more there are often renal aplasia with hypoplastic kidneys, cystic dysplasia, double uterus, absence of the gallbladder or pancreatic head, and cysts of the pancreas, liver and kidneys. The nasal bridge is depressed and the chin is small, cleft lip/palate is common and bifid or absent epiglottis, esophageal atresia tracheoesophageal atresia or fistula have been reported. Brain anomalies like arrhinophaly and aplasia of brain nerves are rare. There are sometimes descriptions of natal teeth.

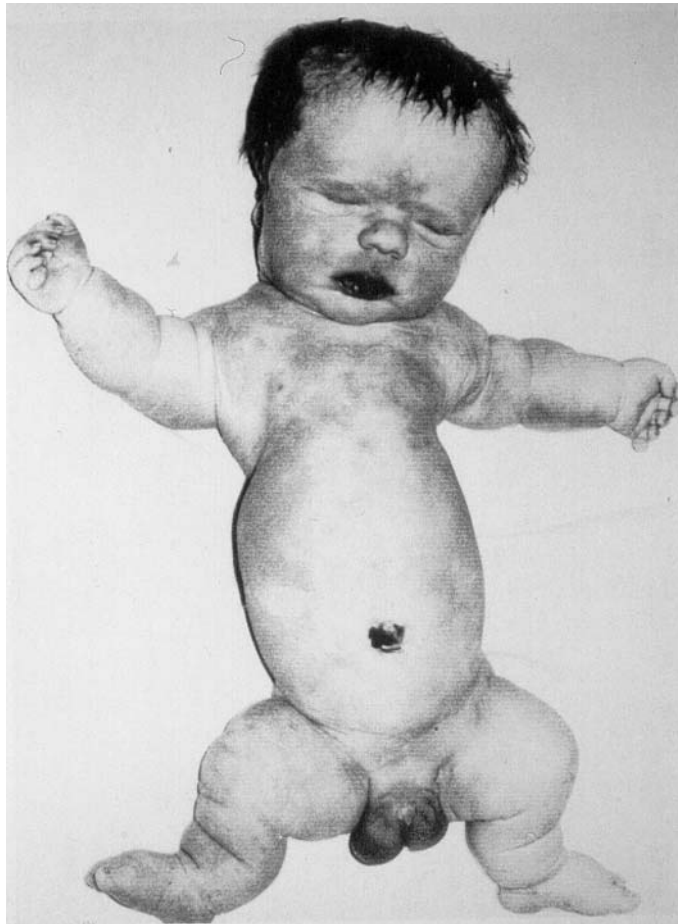


Fig. 4.1.1. : Morphological aspect of SRPS Type 1 Saldino-Noonan (Bergsma, D., 1979, Births defects Compendium: 954, 2<sup>nd</sup> Edition, The National Foundation- March of Dimes- The Macmillan Press Ltd.)

#### 4.1.2. Description of radiologic findings

Skull: radiographic examinations show normal length and ossification of the base of the skull, hypoplastic maxilla, short cranial base and flat occiput.

Thorax: the ribs are short and horizontally orientated, the scapulae are hypoplastic. The vertebral column is of normal length with small and hypoplastic vertebrae and small intervertebral spaces.

The condition is illustrated in Fig. 4.1.2.

The iliac bones: are small with horizontal acetabular roofs. The tubular bones are short and show metaphyseal dysplasia.

The pelvis: is resembling that in the Ellis-van Creveld syndrome and Jeune syndrome, with small ilia and osseous spurs projecting medially and laterally from the acetabular roofs (Mc Kusick, 1986).

There are often triangular ossification defects above lateral parts of the acetabulum, striking shortness of the long tubular bones with spurs extending from medial and lateral parts of their metaphyseal margins. Sacrum show ossification center. The differential diagnosis includes often thanatophoric dysplasia.

Extremities: hands show always polydactyly. There a short metacarpalia and phalangs visible at hands. In about 1/3 of the cases the feet show polydactyly.

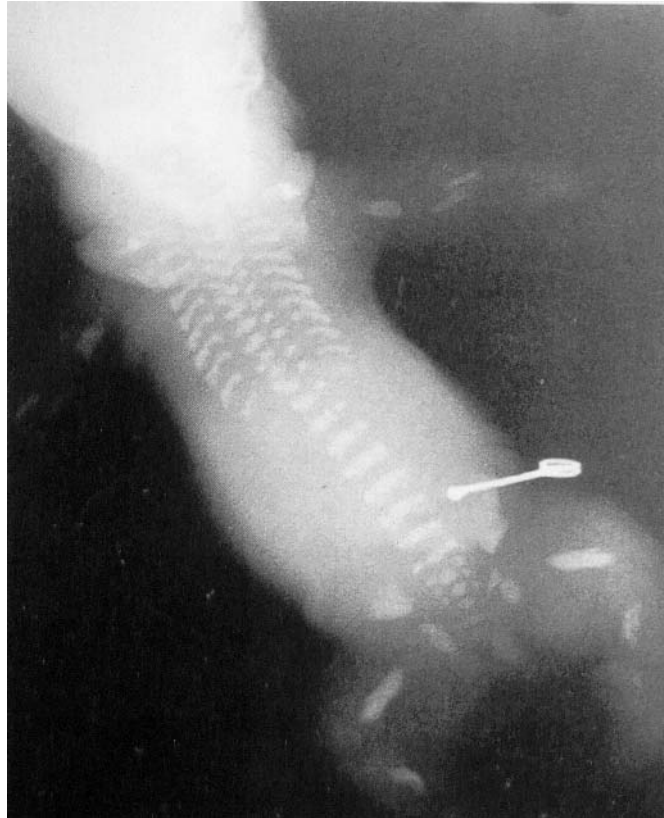

Fig. 4.1.2. : Radiograph of SRPS Type 1 showing a premature neonate with extremely shortened ribs. The vertebral bodies, ilia and limb bones are also severely dysplastic. (Potter's Pathology of the fetus and infant, 1997, Vol. 2., edited by Enid Gilbert-Barnes, St. Louis, Mosby: 1445)

#### 4.1.3. Description of histological findings

Skeletal system: the chondroosseous morphology shows irregular columnization. Ossification is defective in the calvaria, vertebrae, pelvis and bones of the hands and the feet.

Microscope examination: the growth plates of tubular bones show abnormalities of differentiation in the zone of proliferating cartilage, hypertrophy and irregular formation of the primary spongiosa. In some areas these zones can be absent and tongues of undifferentiated cartilage can extend deeply into metaphyses. The condition is illustrated in Fig. 4.1.3.; There are central fibrosis in the center of the distal femoral physeal growth zone, regarded as histological characteristics of type Saldino-Noonan (Spranger et al, 1990; Gilbert-Barnes and Opitz, 1996).

All long tubular bones are shortened.

Kidneys: some kidneys show the typical picture of polycystic dysplasia, but there are no specific alterations that would allow to differentiate between SRPS Type 1 and other types.

other organs: the histologic examinations of most reports about SRP syndrome type Saldino-Noonan do not mention in any way histologic aberrations of most internal organs. But there are rare descriptions of histology in the most journals.



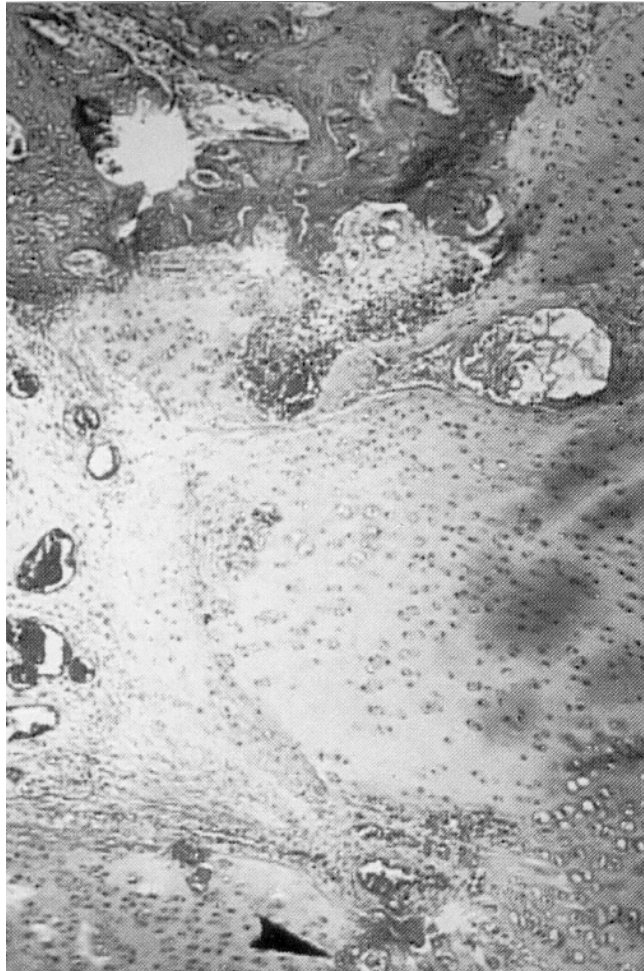

Fig.4.1.3. : Photomicrograph of SRPS Type 1: a portion of central physeal fibrosis is shown right at the center of this photomicrograph. It is surrounded by markedly deranged physeal chondrocytes. A portion of premature ossification center is shown at the upper margin (arrow). ( Potter's Pathology of the fetus and infant, 1997, Vol. 2., edited by Enid Gilbert-Barnes, St. Louis, Mosby: 1445)

## 4.2. SRPS Type 2 Majewski

### 4.2.1. Morphological aspects

In 1971 Majewski et al. described four newborn babies with a lethal form of neonatal dwarfism characterized by extremely short ribs and limbs, normal pelvis and vertebrae, disproportionally short tibiae, and polydactyly.

The conditions are illustrated in Fig. 4.2.1.

Further cases of SRP syndrome type 2 was described by Spranger et al. 1974, Motegi et al. 1975, and other authors.

As in SRP syndrome Saldino-Noonan, the patients are stillborn or die within a few hours after birth, as a result of asphyxia caused by hypoplastic lungs and short ribs.

There is only one case where the patient survived 8 weeks, observed by Bidot-Lopez et al. in 1978, but it is possible that the patient suffered the Ellis van Creveld syndrome and not SRPS Type 2.

The frequently hydropic patients have a large head with a depressed nasal bridge, low set ears, cleft lip/palate and micrognathia. The thorax is narrow, with hypoplastic lungs, the extremities are short with polydactyly of hands, and in about 50 per cent of the cases polydactyly of feet.

The occasional spectrum of extraskeletal abnormalities is similar to that in other SRP syndromes and includes gingival frenula, hypoplastic epiglottis and larynx, neonatal teeth, hypoplastic kidneys, renal cysts, micropenis, vaginal anomalies, and short, malrotated intestine.

Arrhincephaly has been described in three cases by Majewski et al., 1971; Chen et al., 1980 and Spranger et al., 1974. Further described were hepatosplenomegaly, ascites, oedema, pancreocystofibrosis and cardiovascular abnormalities. The differences between SRP Type 1, 2 and others are listed later.

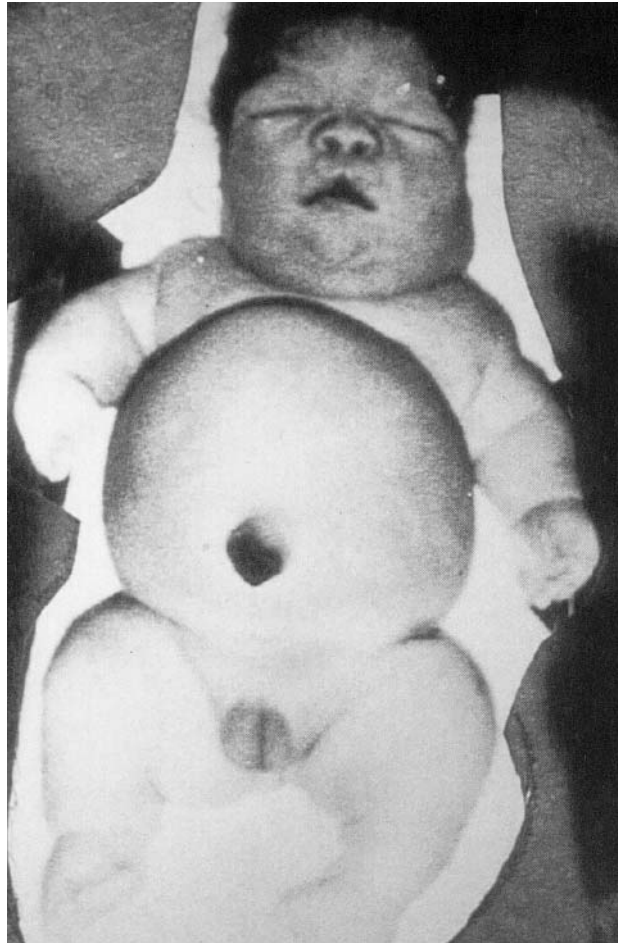


Fig. 4.2.1. : Morphological aspect of SRPS Type 2 Majewski, neonate with hydrops, extremely narrow chest, protuberant abdomen, and short limbs (Potter`s Pathology of the fetus and infant, 1997, Vol. 2., edited by Enid Gilbert-Barnes, St. Louis, Mosby: 1446).

#### 4.2.2. Description of radiologic findings

Figure 4.2.2. shows radiographic findings of SRPS Type Majewski.

Skull: retarded ossification of parietal and occipital bones.

Thorax and extremities: radiography shows extremely short horizontal ribs, with high clavicles. Spine and pelvis are unremarkable. Ossification of the proximal epiphyses was described as premature, just as the one of femora and lateral cuboids.

The tubular bones: are extremely short, especially the mesomelic segments. The tibia is also very short and has a typical oval form.

The first metacarpals and metatarsals was described to be short and rounded, but more precise descriptions of anatomic details are very rare in the most radiologic descriptions.

Abdomen: the chest is short and narrow. The abdomen is protuberant with ascites:

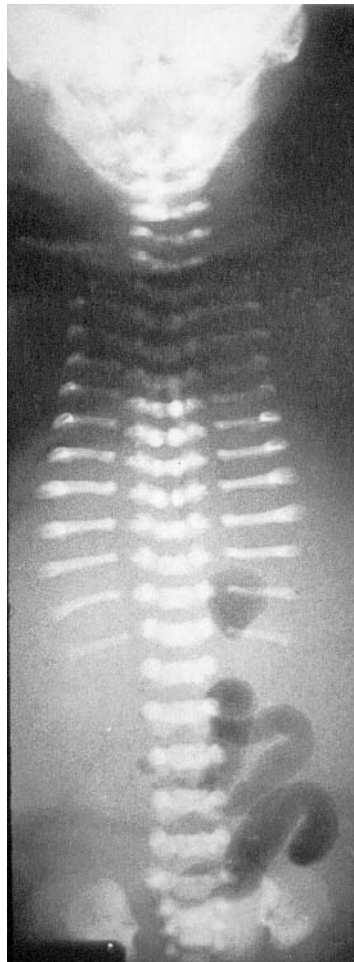


Fig. 4.2.2. : SRPS Type 2: Radiograph of the same neonate as seen in Fig. 4.2.1. showing extremely shortened ribs and unremarkable vertebral bodies and ilia. (Potter's Pathology of the fetus and infant, 1997, Vol. 2., edited by Enid Gilbert-Barnes, St. Louis, Mosby, : 1445)

#### 4.2.3. Description of histological findings

**Skeletal system:** The histologic section of the head of the humerus show marked increase in cartilage mass. Epiphyseal region may be irregular with broad epiphyseal cartilage and absence of order of columns of chondrocytes. Tibial hypoplasia is characteristic for Majewski syndrome.

The physeal growth zone is markedly retarded and disorganized as seen in Fig. 4.2.3.

**Kidneys:** The kidneys are partly dysplastic consisting of very small glomeruli and unconnected cystically dilatated tubuli. There are multiple glomerular cysts and focal cystic dilatation of the distal tubules in the kidneys. In combination with median cleft lips, and hypoplasia of the epiglottis this kidney anomalies are characteristic for the Majewski syndrom (Motegi et al., 1979).

**Other organs:** pancreocystofibrosis can be found but it is rare and not symptomatic, also the liver may show fibrosis and proliferation of bile ducts. In some areas the exocrine pancreas is normal, in others it may be absent and replaced by increased amounts of connective tissue.

**Central nervous system:** Gross and histologic examination of the brain and spinal cords show mostly no abnormalities.

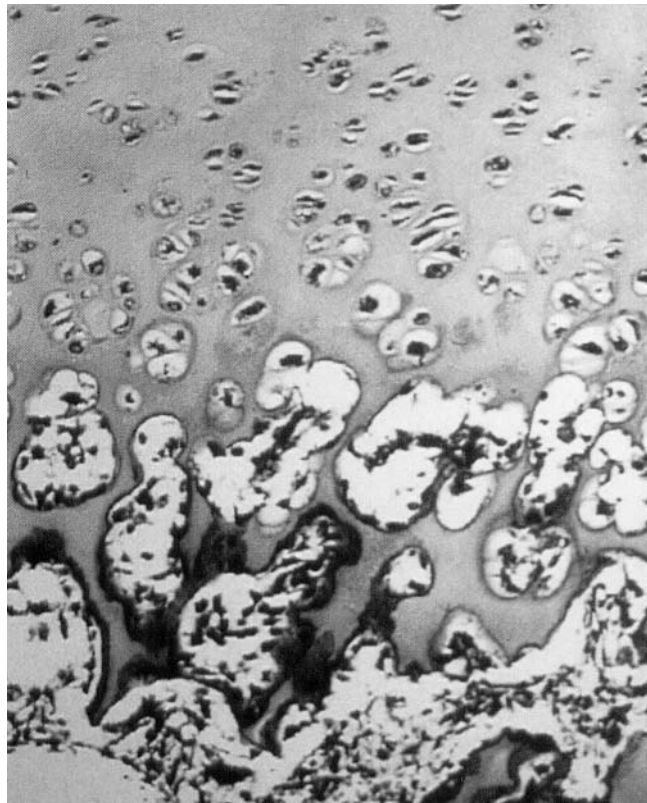


Fig. 4.2 .3. : SRPS Type 2: the physeal growth zone is markedly retarded and disorganized; (Potter`s Pathology of the fetus and infant, 1997, Vol. 2., edited by Enid Gilbert-Barnes, St. Louis, Mosby: 1446)

#### 4.2.4. Overlapping with oral facial digital syndrom (OFDS ) .

The classification of syndromes in patients with multiple congenital abnormalities is often difficult. Sensenbrenner et al. first described a case of Mohr syndrom with skeletal dysplasia in 1975. Later Temtamy et al. described another patient with overlapping phenotype between the Mohr and the Majewski syndrome in 1978. Baraitser et al. reported a similar case. It followed the report by Burn et al. in 1984 and the proposed designation of OFDS Type 4. Moerman et al. described in 1998 cases in which phenotype overlapping between OFDS Type 2 ( Mohr syndrome) and SRPS Type 2 (Majewski syndrome ) is possible.

The patients with OFDS show facial anomalies with irregular oral cavity, malformations of the fingers and toes combined with typical signs of Majewski syndrome with short ribs and long bones shortening.

### 4.3. SRPS Type 3 Verma-Naumoff

#### 4.3.1. Morphological aspects

Spranger et al. first described cases of SRPS Type 3 in 1974 and diagnosed them as Saldino-Noonan syndrome. Verma et al. (1975) and Naumoff et al. (1977) distinguished a new type of SRPS based on the descriptions by Spranger et al. (1974) and on own descriptions.

Analyses of radiological features of SRPS Type Verma-Naumoff show significant bone changes that allow us to distinguish it from others. Chondroosseus morphology of the growth plate shows short chondrocyte columns that consist only in a few hypertrophic cells. Some areas show complete absence of columnization and bone is directly deposited on the matrix (Verma et al., 1975).

The irregular „torpedo“ shape of tubular bones is not as severe and generalized as in SRPS Saldino-Noonan, although ossification is much more advanced.

The patients are stillborn or die within a few hours after birth, they are hydropic with a depressed nose, large head, and short extremities. The main morphological aspects are as in other types of SRPS: the short ribs and polydactyly of hands and feet, absence of polydactyly was mentioned by Spranger et al. (1990) and Sillence et al. (1987).

The condition is illustrated in Fig. 4.3.1.

Other morphological features are the saddle shaped nose, prominent abdomen, and narrow chest. Cleftlip/palate has been found in three patients each (Spranger et al., 1974; Naumoff et al., 1977; Bernstein et al. 1985;). Autopsies show similar malformations as in SRPS Type 1 with: hypoplasia or aplasia of the kidneys, congenital heart defects, abnormal cloacal development with anal atresia, urethral stenosis, absent or hypoplastic penis, uterus, or vagina and short gut. But cloacal developmental are not as common as in type Saldino-Noonan. They may be typical features of SRPS Type Verma-Naumoff.

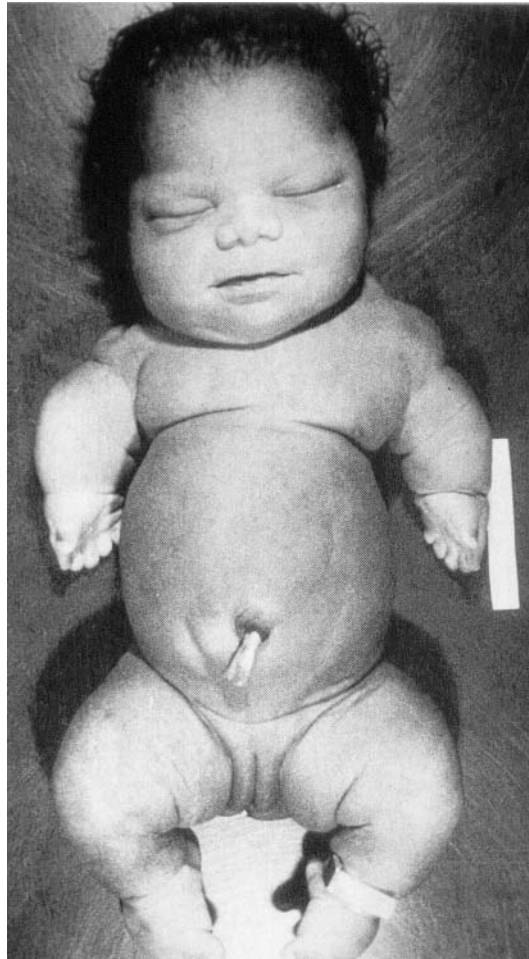


Fig. 4.3.1. : Short rib polydactyly syndrome type 3: a hydropic neonate with severely shortened extremities. Postaxial polydactyly of the hand is visible. (Wiggleworth, J. S., 1993, Textbook of fetal and perinatal pathology, Vol. 2, Blackwell Scientific Publications, Boston: 1196)



#### 4.3.2. Description of radiologic findings

Skull and bones: Described as the most significant features of SRPS Type 3 are short cranial base, combined with a bulging forehead, the depressed nose and the flat occiput. Another difference is shown in the radiologic appearance of the long tubular bones with a distinct corticomedullary demarcation, widened metaphyses, and marked longitudinal spurs (Mc Kusick, 1986;).

The long tubular bones are shortened and relatively thick. The metaphyseal ends were grossly indistinct, sometimes widened, the epiphyses may be prematurely ossified.

The bones of the hands are short and squat with irregular metaphyseal rima and present some small distal spurs. The mandible and the dental Anlagen are normal. Thorax: radiography shows the typical short ribs with normal clavicles and sometimes hypoplastic scapula, the thorax is markedly narrow, the vertebrae are small and hypoplastic with increased intervertebral spaces. The radiographic feature is shown in Fig. 4.3.2.

The pelvis may be shortened craniocaudally, and may present small and rounded iliac wings with deeply hollow, irregular acetabular roofs and sometimes deep supra acetabular indentations. Gas may be present in the stomach and proximal small intestine.

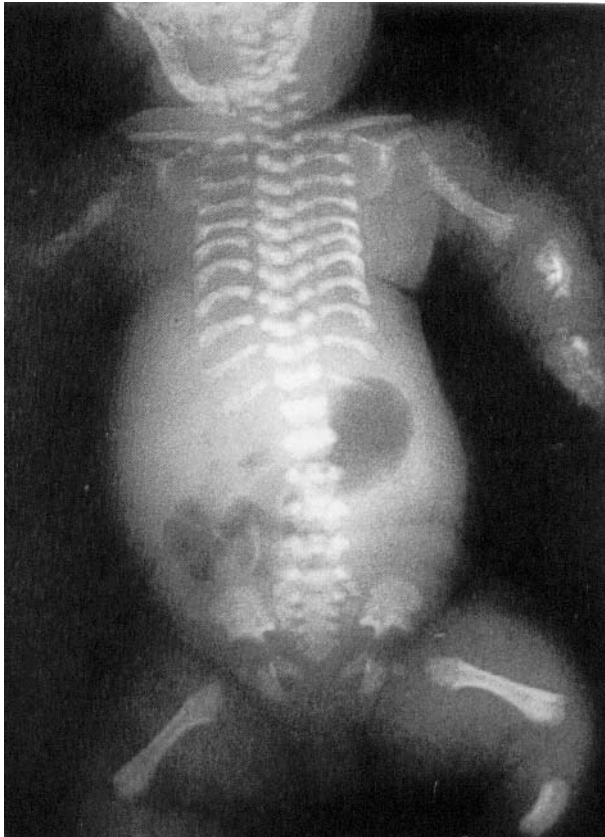

Fig. 4.3.2. : Short rib polydactyly syndrome type 3; Skeletal radiograph showing extremely shortened ribs, abnormal vertebral bodies and vertically shortened ilia. (Wiggleworth, J. S., 1993, Textbook of fetal and perinatal pathology, Vol. 2, Blackwell Scientific Publications, Boston: 1197)

#### 4.3.3. Description of histological findings

Skeletal system: Sections of the growth plate in the femoral condyles, femoral heads, and tibia confirm the macroscopic and radiologic features with patchy changes of disorganization with shortened cartilage columns due to a reduced number of hypertrophic chondrocytes.

The condition is illustrated in Fig. 4.3.3.1. Resting chondrocytes of the neonate, as seen in Fig. 4.3.3.2., contain PAS positive diastase-resistant cytoplasmic inclusions.

There may be „cupping“ of the metaphyseal margins with trabeculae of newly formed bone extending into the cartilage which confirm the radiological aspects of the metaphysis.

Other organs: There are rare descriptions of histologic abnormalities in SRPS Type Verma-Naumoff concerning in most cases the kidneys with cystic dysplasia.

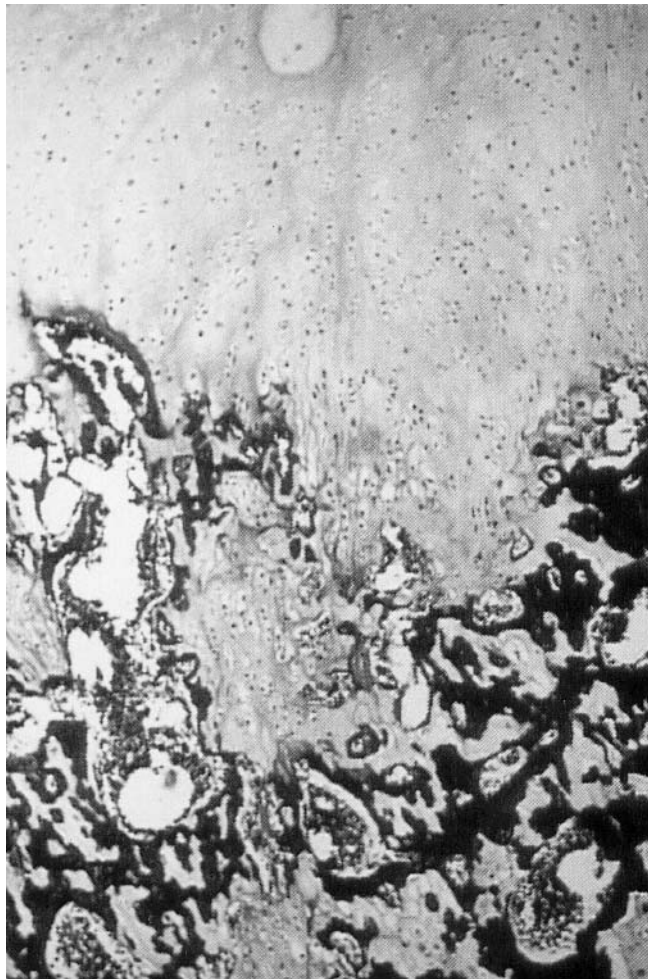


Fig. 4.3.3.1. : Photomicrograph of SRPS Type 3. The physal growth zone is markedly retarded and disorganized. (H &E, x 50). (Potter's Pathology of the fetus and infant, 1997, Vol. 2., edited by Enid Gilbert-Barnes, St. Louis, Mosby: 1448)

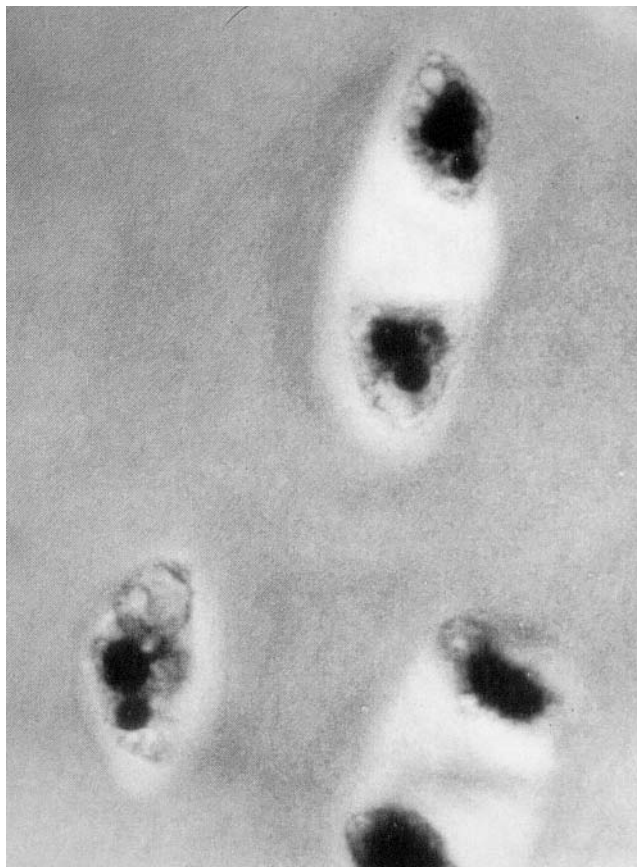

Fig. 4.3.3.2. : SRPS Typ 3: resting chondrocytes of the neonate contain PAS- positive diastase-resistant cytoplasmic inclusions, (H &E, x 50). (Potter`s Pathology of the fetus and infant, 1997, Vol. 2., edited by Enid Gilbert-Barnes, St. Louis, Mosby: 1448)

#### 4.4. SRPS Type 4 Beemer-Langer

##### 4.4.1. Morphological aspects

Beemer et al. reported a new variation of SRPS in two unrelated infants in 1983. Similar cases were reported by Passarge in 1983, Winter in 1988, Balci et al. 1991 and Yang et al. in 1991.

Morphological features were similar to those in the other SRP syndromes, especially to the Majewski type with the short ribs, short bowed limbs, hydrops, ascites, median cleft of the upper lip, narrow chest.

But the main distinguishing findings seemed to be the absence of polydactyly. Lurie et al. analyzed in 1994 six cases of Beemer-Langer syndrome in sibs, but only one case present the classical manifestation without polydactyly. Three of the affected sibs had preaxial polydactyly.

In 1994 Tsai et al. reported about two sibs without polydactyly. Lurie et al. concluded therefore that absence of this feature cannot be used to distinguish between type Majewski and type Beemer-Langer. Other morphological features are a large head with low nasal bridge, midline cleft lip and palate, macrocephaly, oral abnormalities, including cleft tongue, natal teeth and often oral frenula.

The neck is short and the chest is narrowed with a protuberant abdomen.

Other malformations described are hypoplastic kidneys, renal cysts, and also, as in type Majewski, cardiovascular anomalies.

The autopsy may disclose a large ductus arteriosus, preductal coarctation of aorta, malrotation of intestines, dilatation of the urinary bladder, mild or grave hydronephrosis and hydronephrosis, and atresia of ureteropelvic junction. Hydrocephalus with single ventricle, agenesis of corpus callosum, a Dandy-Walker „cerebellar cyst“, and arachnoid cysts of occipital lobes were reported in the case by Yang et al. (1991).

Chondroosseous morphology is normal, which is one of the main distinguishing features of type Majewski, which shows the typically ovoid long tubular bones. SRPS Beemer-Langer type is characterized clinically especially by median cleft lip, small chest with very short ribs, protuberant abdomen with umbilical hernia, and ambiguous genitalia in male patients (Yang et al., 1991).

#### 4.4.2. Description of radiologic findings of SRPS Type 4 Beemer -Langer

Skull: radiographics confirm the macroscopic aspects with marked macrocephaly and shortening of skull base.

Thorax and extremities: postmortem radiographics show typical features of SRP syndrome with short, horizontal ribs with anterior irregularity and widening, small, poorly ossified vertebrae and increased intervertebral spaces.

Other features are high position of thin clavicles due to thoracic lordosis, small scapulae, small illia due to short basilar portions and small iliac wings; shortened long tubular bones, bowes radii and ulnae, and relatively normal tubulated tibiae.

Absence of metaphyseal irregularities, and short tubular bones of hands and feet with and without polydactyly may occur.

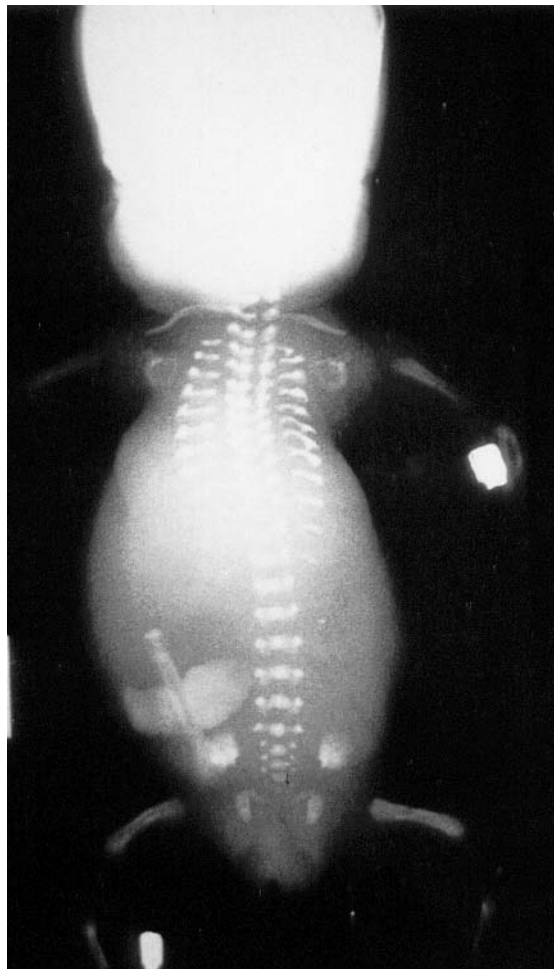


Fig: 4.4.2.: SRPS Type 4: radiograph of a neonate showing extremely shortened ribs and abnormal vertebral bodies and ilia. (Potter's Pathology of the fetus and infant, 1997, Vol. 2., edited by Enid Gilbert-Barnes, St. Louis, Mosby: 1448)

#### 4.4.3. Description of histological findings

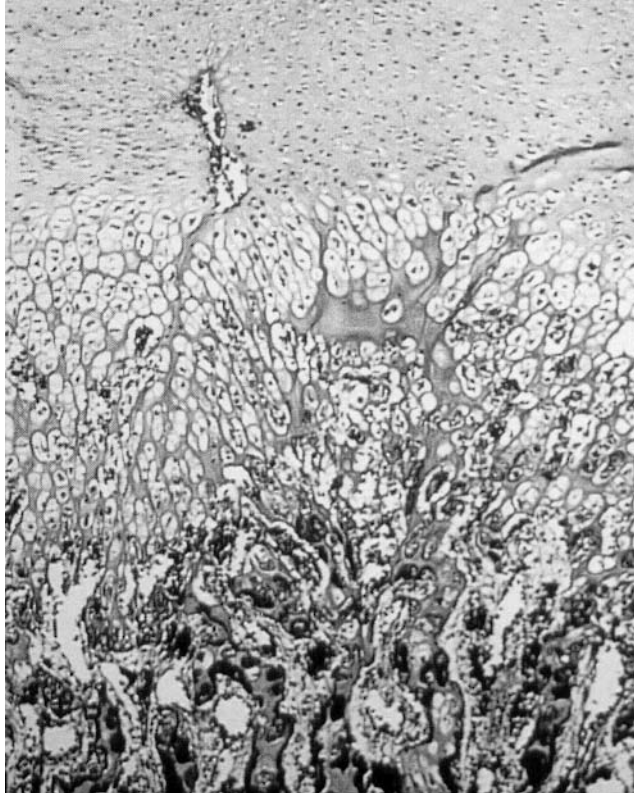Skeletal system: histopathological examinations of skeletal system show the cartilage to be relatively unremarkable.

The physal growth zone may be disorganized with irregular vascular penetration of the cartilage at the metaphyseal border. Hypertrophy zone may appear prominent, caused by large chondrocytic lacunae. This prominent zone of hypertrophy may be shown in proximal humerus, radius, femur, tibia, and distal femur. The same zone is disorganized in the vertebrae, distal humerus and radius but not as prominent. Irregular islands of cartilage are visible in the metaphyseas of long tubular bones.

The cartilage of vertebrael bodies show serrated cartilage bone junction with widened zones of provisional calcification.

Kidneys: there are descriptions of abnormalities of kidneys with layers of fibrous tissue around cystically dilatated tubules in cortex and medullae and occasional islands of cartilage in the interstitium, confirming the macroscopic diagnosis of cystic renal displasia.

Other organs: liver and pancreas may show fibrous tissue. These changes in liver resemble those of congenital hepatic fibrosis associated with autosomal recessive polycystic kidneys (Cydecian et al.; 1993).



4.4.3.1.: Photomicrograph of SRPS Type 4: the physal growth zone shows a prominent but disorganized zone of hypertrophy. There is irregular vascular penetration of the cartilage. (Potter`s Pathology of the fetus and infant, 1997, Vol. 2., edited by Enid Gilbert-Barnes, St. Louis, Mosby: 1448)

## 4.5. Asphyxiating thoracic dysplasia (Jeune syndrome)

### 4.5.1. Morphological aspects

The conditions of Jeune syndrome were first described in a brother and a sister by Jeune et al. in 1955. Another term is „Asphyxiating thoracic dysplasia“ or „thoracic-pelvic-phalangeal dystrophy“ (Langer et al.; 1968).

Polydactyly, which is sometime present, may led to confusion with Ellis van Creveld syndrome. Newborns with Jeune syndrome have a narrow thorax, short sternum with often incomplete ossification, and are in respiratory distress.

The condition is illustrated in Fig. 4.5.1.

The respiratory distress is variable and due to short, horizontally ribs and hypoplastic lungs. Many patients are stillborn or die within a few days after birth. Severe cases have also short limbs and are hydropic. Polydactyly may be present. Lighter manifestations of Jeune syndrome may survive the neonatal period, their thorax is however narrow and they suffer from respiratory difficulties throughout the first year of life. In later childhood the shape of the thoracic cage tends to revert to normality.

Kaufmann and Kirkpatrick (1974) stated that to up of 80 per cent of patients die in infancy, thus promoting speculation as to whether survivors have a genetically distinct form of this disorder. This theory gained further support when Kozlowski and Masel (1976) described two children whose diagnosis was reached by chance at the age of 4, when radiographs were obtained for unrelated reasons.

The only report of an affected adult concerns a 32-year old American Indian (Friedmann et al., 1975). Patients with Jeune syndrome can develop renal, hepatic, retinal, and myocardial lesions (Oberklaid et al.; 1977; Bard et al.; 1978). Dentition may be defect (Maroteaux and Savart, 1964). Death due to respiratory insufficiency, bronchopneumonia or later from nephronophtisis with renal failure may occur at any time, but there are also cases with survival to adulthood (Oberklaid et al., 1977; Donaldsen et al., 1985).

Death from respiratory failure is common in infancy (Barnes et al., 1969). In 1968, Langer and Herdmann described the high rate of progressive renal disease in individuals who survived infancy. Reports of affected sibs and increased incidence of parental consanguinity confirm the autosomal recessive condition of Jeune`s syndrome.

Occasional abnormalities are pancreatic cysts, retinal degeneration and lacunar skull.

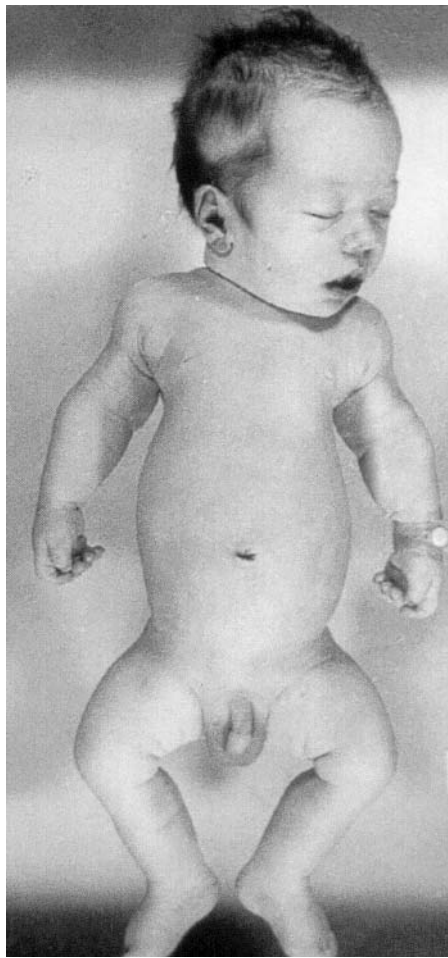


Fig. 4.5.1.: Asphyxiating thoracic dysplasia (Jeune syndrome): Neonate with narrow chest and mild acromelic shortening of the limbs. (Potter's Pathology of the fetus and infant, 1997, Vol. 2., edited by Enid Gilbert-Barnes, St. Louis, Mosby: 1443)



#### 4.5.2. Description of radiological findings

In the neonatals, the major radiographic features are a narrow thorax, short and horizontally orientated ribs, with irregular costochondral junction. Further high clavicles, and short iliac bones.

The tubular bones may show trident form of the acetabular margins.

The tibiae and fibulae are short. The vertebral bodies show irregular density, which is similar to the radiographics in Saldino-Noonan type. Horizontal acetabular roofs with spur-like projections at lower margins of sciatic notches. Early ossification of capital femoral epiphysis.

There may be postaxial polydactyly with shortening of metacarpals, proximal phalanges, and middle phalanges. Children surviving the neonatal period show regress of pelvic and thoracic anomalies, rendering the radiographic diagnosis more difficult (Kozlowski and Masel, 1976; Cortina et al., 1979).

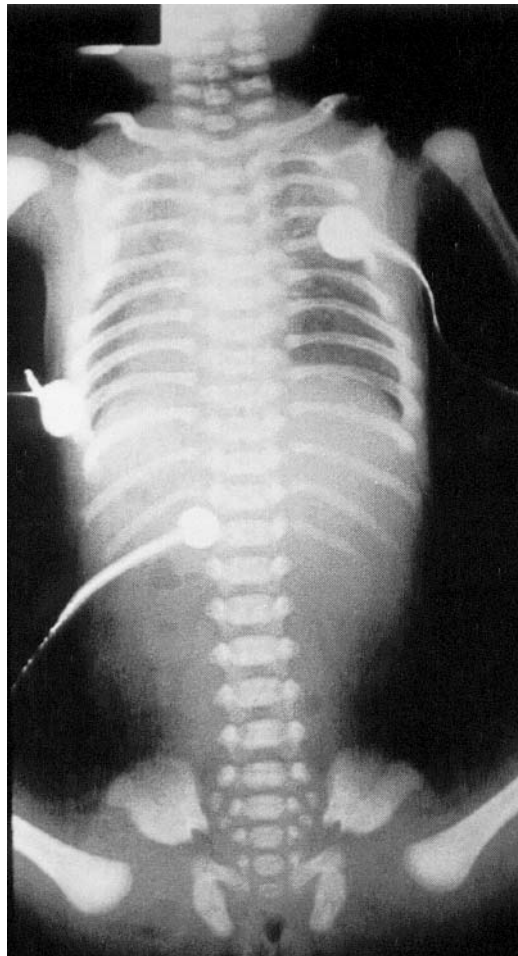


Fig. 4.5.2.1.: ATD: radiograph of a neonate showing short ribs, normal vertebral bodies and vertically shortened ilia. (Potter's Pathology of the fetus and infant, 1997, Vol. 2., edited by Enid Gilbert-Barnes, St. Louis, Mosby: 1443)

#### 4.5.3. Description of histological findings

Yang et al. disclosed two different types which were designated as type 1 and type 2. Type 1 of Jeune syndrome is characterized by irregular metaphyseal ends and histopathologically irregular cartilage bone junction with patchy distribution of physal zone of hypertrophy.

Type 2 of Jeune syndrome show radiologically smooth metaphyseal ends and histopathologically diffusely retarded and disorganized physes with smooth cartilage bone junction as shown in Fig. 4.5.3.

Endochondral ossification in both types of Jeune syndrome is histological aberrated with large islands of cartilage in the metaphysis. In the chondroosseous junction of the growth zone the number of proliferating and hypertrophic chondrocytes may be reduced. There may be transverse plates of bones (Yang et al.,1976). The distal and middle phalanges show cone shaped epiphyses and metaphyses.

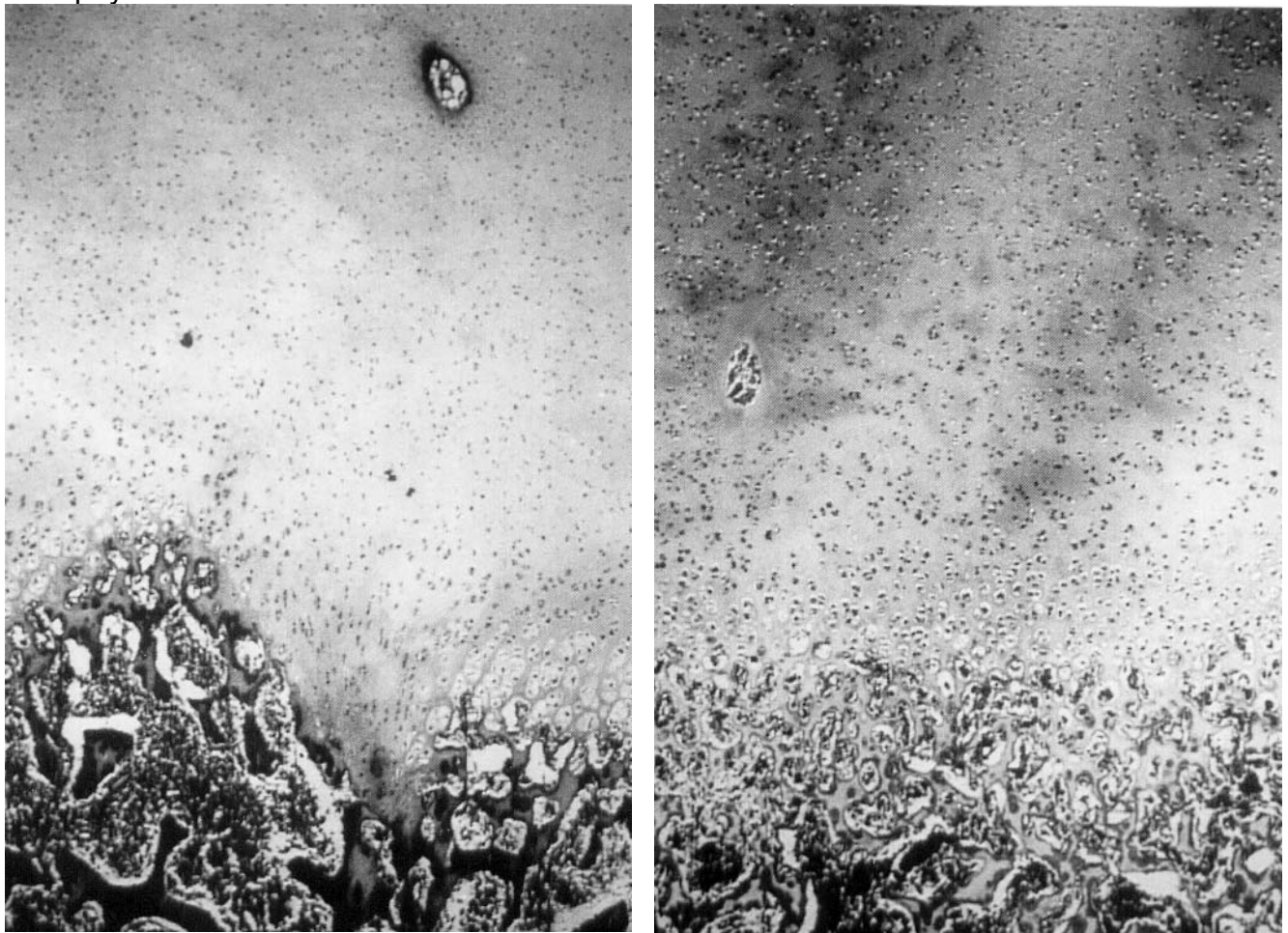


Fig. 4.5.3. A: The physal growth zone with patchy distribution of enchondral ossification. ATD type 2; B: type 2 cartilage showing a diffusely retarded and disorganized physis). (Potter's Pathology of the fetus and infant, 1997, Vol. 2., edited by Enid Gilbert-Barnes, St. Louis, Mosby: 1444)

## 4.6. Ellis van Creveld dysplasia

### 4.6.1. Morphological aspects

Ellis van Creveld dysplasia, also called chondroectodermal dysplasia, was first described by Ellis and van Creveld in 1940. It is characterized by acromelic dwarfism, dysplastic nails, postaxial polydactyly, and oral abnormalities.

Contrary to the other forms of SRPS Ellis van Creveld dysplasia is not necessarily lethal. Chondroectodermal dysplasia is a well defined entity in which short limbed dwarfism and polydactyly are associated with structural cardiac anomalies. Since the first description by Ellis and van Creveld more than 120 cases have been described. The largest series is that of Mc Kusick et al. (1964) who identified the disorder in an inbred religious isolate, the Amish of Pennsylvania, USA.

Anomalies of the hair and genitalia are sometimes found. All these anomalies derive from dysfunction of the ectodermal and mesodermal germs (Ellis and van Creveld, 1940; Jones, 1988; Gorlin et al., 1990). The multiple abnormalities require a multidisciplinary treatment of the patients by combined surgical-orthodontic treatment.

A typical case of EvC dysplasia show the following 4 main symptoms:

1.) Disproportionate dwarfism due to chondrodysplasia of long bones and an exceptionally long trunk. The severity of short limbs increases from the proximal to the distal segments (acromesomelic dysplasia). Genu valgum is always present, and by the age of 5 or 6 typical X-ray changes may consist of erosion of the lateral aspect of the proximal tibial metaphysis.

2.) Bilateral postaxial polydactyly of the hands and only rarely of the feet. The extra fingers are rather well developed. In the fingers the proximal phalanges are longer than the middle and distal phalanges so the patient cannot make a tight fist.

3.) Ectodermal dysplasia in which the nails are small and dystrophic, the hair is thin and sparse, and the teeth are hypodontic. Main syndroms of oral manifestations are hyperplastic frena, partial anodontia, small conical crowns, and malocclusion (Ellis and van Creveld, 1940; Mc Kusick et al., 1964; Eidelmann and Rosenzweig, 1965; Winter and Geddes, 1967; Biggerstaff and Mazaheri, 1968; Prabhu and Dolakia, 1978; Tzuckert and Garfunkel, 1978; Sarnat et al., 1980; Himmelhoch and Mostofi, 1988; Varela and Roms, 1996;). Hyperplasia of the frena is the most important diagnostic criteria for the EvC Syndrome, further anomalies described in literature are dystrophic philtrum, fusion of the middle portion of the upper lip to the maxillary gingival margin, and neonatal teeth, caused by these hyperplastic frena. Other malformations are small cranial base, hypoplastic maxilla, large mandible with increased gonial angle, and malocclusion.

4.) Congenital heart malformations occur in 50-60% of the cases and are most commonly due to a single antrum and ventricular septum defects. About one half the of patients die in early infancy as a consequence of these cardiac or thoracic malformations.

Occasional abnormalities are further mental retardation, scant or fine hair, cryptorchidism, epispadias, equinovarus and renal agenesis.

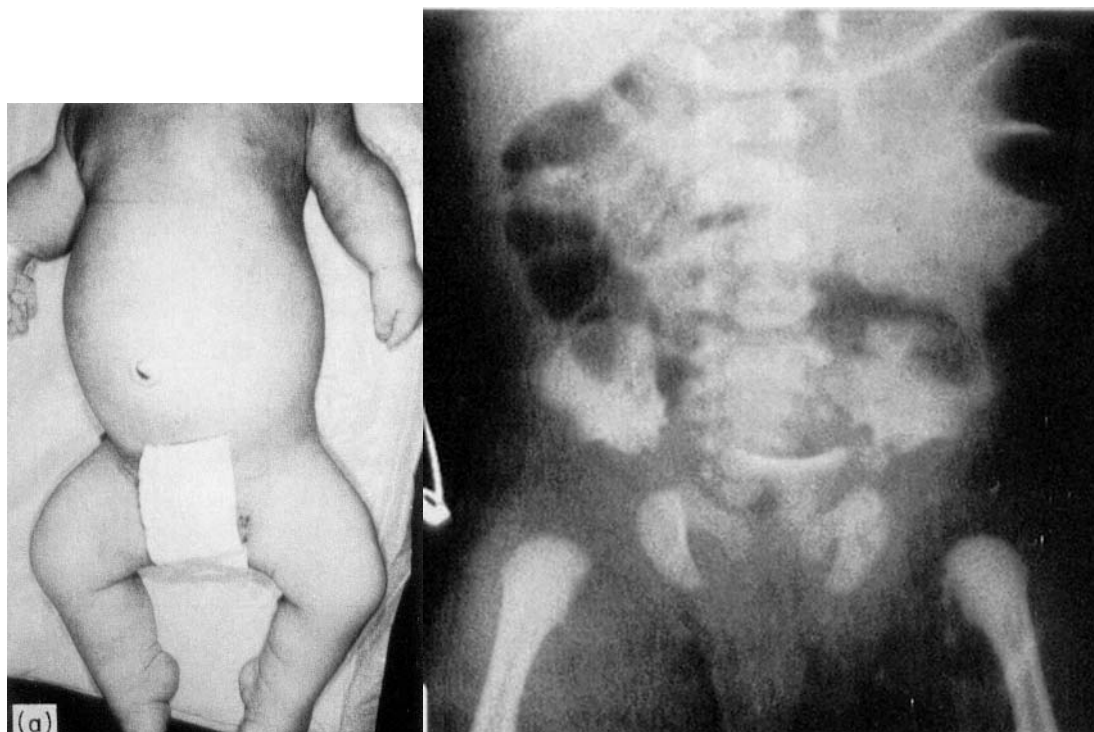


Fig. 4.6.1.: Ellis van Creveld dysplasia: Infant with small chest and mild dwarfism. (Wiggleworth, J. S., 1993, Textbook of fetal and perinatal pathology, Vol. 2, Blackwell Scientific Publications, Boston: 1194)

#### 4.6.2. Description of radiological findings

Literature of radiographics is sparse because of a high surviving rate of patients with EvC dysplasia. The radiological and histological descriptions are based on the cases of Qureshi et al. (1993).

Skeletal system: shortened long tubular bones with rounded metaphyseal ends. The bones of the hand are just as shortened. Polydactyly of upper limb is seen in all cases. Polydactyly of lower limb is present in two of the 3 described cases. Iliac bones have squared appearance. The acetabular roof looks unusual with a "trident-like" appearance.

The radiological features are shown in Fig. 4.6.2.

In infancy the radiographic changes in the pelvis and thorax are very similar to those of asphyxiating thoracic dysplasia. Bony fusions in the carpus and hypoplasia of the phalanges serve as distinguishing features.

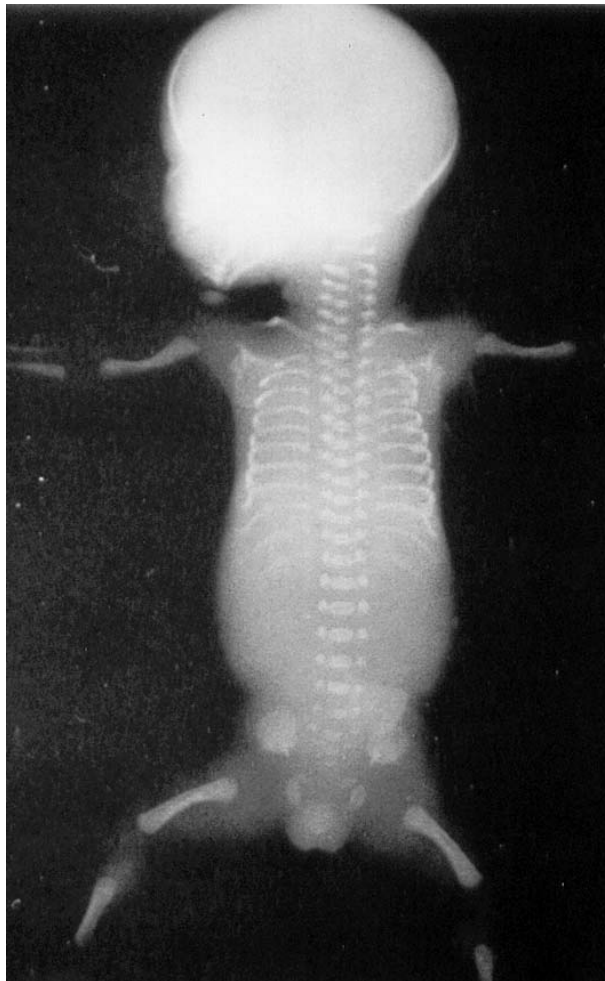


Fig. 4.6.2.: Ellis van Creveld dysplasia: infant with small chest and mild dwarfism. (Wiggleworth, J. S., 1993, Textbook of fetal and perinatal pathology, Vol. 2, Blackwell Scientific Publications, Boston: 1194)

#### 4.6.3. Description of histological findings

The skeletal histopathology of Ellis van Creveld dysplasia or chondrodermal dysplasia has been studied in fetus, newborns, and older individuals

Skeletal system: All cases showed similar histopathologic changes. In the femur was poor columnization of chondrocytes in the physis occurred especially in the zone of hypertrophy. The resting cartilage was normal. In the vertebrae there was variable but definite chondrocytic disorganization in the central physeal area, whereas in the peripheral physis there was better organization of chondrocytes. There are no islands of cartilage in the metaphysis.

No invasion of the physeal growth zone by fibrous or mesenchymal-like bands of soft tissue is noted.

The cartilage matrix of the femora, vertebral bodies, and ribs was unremarkable.

Periosteal membranous ossification extends to the perichondrium of the physis at the level of the zone of proliferation (Qureshi, et al. 1993).

## 5. Discussion

### 5.1. Differences and Similarities of SRP dysplasia group

Superficially two different forms of short rib polydactyly dysplasia group can be distinguished : the usually lethal forms of type 1-4, and the usually non-lethal forms of Asphyxiating thoracic dysplasia and Ellis van Creveld dysplasia. Lethality and non lethality is applied to the neonatal period of patients.

In the first group type Beemer-Langer seems to be a special case with its absence of polydactyly.

The distribution of visceral anomalies in the various types of short rib polydactyly dysplasia overlap so widely that the classification usually should be based mainly upon roentgenographic criteria, but secondary malformations like cardiac malformations are helpful for exact distinction.

Sillence compared clinical, radiographic and morphological data from cases of non Majewski short rib polydactyly syndrome, and stated that the clinical findings were extremely variable and that the radiographic findings showed a spectrum of severity (Sillence, 1980).

Recognition and differentiation of osteochondrodysplasias is difficult because most morphological and radiological features are very inconsistent and differ only in minor aspects.

The possible distinguishing features are described here according to the the 1992 classification of Beighton et al.; overlap of the different distinguishing features in the different descriptions are unfortunately unavoidable.

The following table shall help to classify the different types of the Short rib polydactyly dysplasia group following the primary and secondary malformations. But the data of the different primary and secondary malformations are not exact, because a lot of the autopsy cases are not comprehensively described.

1.) The Saldino-Noonan type has most features in common with type Verma-Naumoff. The Saldino-Noonan type of SRPS is differentiated from Jeune syndrome and type Verma-Naumoff radiographically by the presence of extremely short rib, and broad undermodeled tubular bones.

Another typical feature is the polydactyly of feet occuring in every 3<sup>rd</sup> case of Saldino- Noonan SRPS: This type of short rib polydactyly syndrome and type Verma-Naumoff can be distinguished by the presence of renal dysplasia in type Saldino-Noonan, the pelvic and metaphyseal dysplasia, and advanced disturbance in endochondral ossification with marked shortening of all tubular bones with metaphyseal irregularities (Meizner et al., 1985).

Such findings occurred particularly in the humeri, femora and tubular bones of the hands. SRPS Saldino-Noonan and type Verma-Naumoff have in common abnormal vertebrae, pelvic anomalies, and spurs at the long ends of bones, distinguishing this two types from type Majewski (Spranger et al., 1974).

The configuration of long bones in type Saldino-Noonan is more pointed, contrary to type Verma-Naumoff where it is more rounded with lateral spiculation.

Another distinguishing feature to separate type 1 from type 3 is the high incidence in type Saldino-Noonan of pulmonary dysplasia combined with heart defects, urogenital and anorectal abnormalities with imperforate anus, persistent cloaca, ureteral and vaginal atresia .

These abnormalities could be interpreted as a dysfunction of cloacal development (Yang et al., 1980). Suspicious is moreover the excess of phenotypic females, meanwhile some males has ambiguous genitalia.

Chondro-osseus histopathology is qualitatively similar in SRPS Saldino-Noonan and SRPS Verma-Naumoff cases. Quantitatively type Verma-Naumoff has an excess of PAS positive inclusion bodies, and the calcospherite size is much larger as measured in type Saldino-Noonan. The essential features of Saldino-Noonan are shortened proliferation zone of chondrocytes with loss of columnization, and irregular and disorganized formation of trabeculae.

One possible way to differentiate similar types of SRP syndrome is the examination of collagens and proteoglycans that are native to cartilage and are the most affected products in this abnormalities( Keating, S.J. et al. 1989). Collagen abnormalities were found in many cases of osteochondrodysplasias, for example achondrogenesis type 2, thanatophoric dysplasia, Kniest dysplasia, and the spondyloepiphyseal dysplasias.

In 1990 Gruber et al. evaluated calcification of cartilage in the SRP syndrom using scanning electron microscopy and quantitative morphometry of calcification regions. The removing of soft and cellular tissue exposed calcospherites which examination by scanning electron microscopy allowed to differentiate better between SRPS Type Saldino-Noonan and type Majewski. The result was that mean calcospherit area of the type Majewski did not differ from normal control groups, meanwhile the calcospherit size from type Saldino-Noonan was much larger than both the control group and type Majewski.

The causes for enlarged calcospherites are unknown. There are hypotheses with three possible explanations:

the first is that matrix alterations may be present which act to offer resistance to, or chemically inhibit, growing calcospherites;

the second is that there may be possible alterations in the matrix which result in fewer, more widely spaced initial sites of calcification. (Gruber et al. ;1990). A third alternative would be that these osteochondrodysplasias are due to defective enchondral ossification, and the aberative calcospherite nodules are the result.

In all cases of possible osteochondrodysplasias, whether or not facilities for ultrastructure examination exist, a small piece of cartilage should be observed in glutaraldehyde (Keating et al .1989).

The sample can be transported to laboratories where electron microscopy is done for ultrastructural examination of matrix structures. This is important for the discovery of biochemical abnormalities in osteochondrodysplasias and could be another option for more exact differentiation of types of SRPS.



2.) The Majewski type of short rib polydactyly has, pre-and postaxial polysyndactyly, suspicious disproportionate shortening of tibia with normal metaphyseal tibial edges, median cleft lip and palate, hypoplasia of the epiglottis, multiple glomerular cysts and focal cystic dilatation of the distal tubules in the kidney (Motegi et al., 1979), and further multiple visceral anomalies, with hepatosplenomegaly combined with ascites.

Polydactyly of feet marks out especially type Majewski, when it is combined with pre and postaxial polydactyly of hands. Other specific features are arrhinencephaly (Spranger et al., 1974), absence of dysplastic changes in the tubular and pelvic elements, with normal vertebral bodies.

Other long bones show relatively little change (Sillence et al., 1987). The presence of normal ilia can be used to distinguish it from ATD and Verma-Naumoff type of SRPS.

Exceptional is the short, undermodeled, often oval tibia, and the radiological appearance of high clavicles.

The disorganization in chondroosseus morphology is quite similar to those described at type Saldino-Noonan, although the shortening of proliferative columns and irregularity in columnization is not so marked.

3.) The Verma-Naumoff type of short rib polydactyly has typical hydrophic appearance, shortening of the skull base, vertebral anomalies, more pronounced shortening of the ribs and a depressed nasal bridge according to their first describers Verma (1976) and Naumoff (1977). SRPS type Saldino-Noonan and Verma-Naumoff have many features in common.

But only type Verma-Naumoff has presence of PAS positive inclusions bodies in chondrocytes. Similar cytoplasmic inclusions have not been seen in other short rib polydactyly syndromes.

The presence of abnormal vertebrae and iliac bones can exclude the possibility of Majewski type of SRPS.

The presence of severely shortened limbs, extremely shortened horizontal ribs, and abnormal vertebrae also exclude the Ellis van Creveld dysplasia and ATD, which are milder forms of short rib polydactyly dysplasia group (Yang et al., 1980).

Generally the Verma-Naumoff type has more significant bone changes.

Another typical feature are skull alterations, with the short cranial base, a bulging forehead, the depressed nose and the flat occiput.

4.) The Beemer-Langer type of short rib polydactyly, which has most features in common with type Majewski, is characterized by a median cleft lip, ambiguous genitalia, small iliac wings, and sometimes absence of polydactyly (Yang et al., 1991).

The bowed radii and ulnae seemed to be a typical feature of type Beemer-Langer until these traits were observed in at least 3 cases with SRPS, type Majewski, and lacking in at least 3 cases with SRPS type Beemer-Langer (Hennekam, 1991).

Differentiation to the Majewski type relies on the radiological appearance of the tibia, which is normal (Beemer et al., 1983; Winter, 1988; Spranger and Maroteaux, 1990). Differentiation to type Saldino-Noonan and Verma-Naumoff could be made by the absence of metaphyseal irregularities and spiking (Saldino and Noonan, 1972; Naumoff et al., 1977).

But in general the differentiation between type Beemer-Langer and type Majewski is difficult, if not impossible, on clinical grounds only.

The absence of polydactyly would be the most important differentiating characteristic, but the inconsistency of this feature makes it less reliable.

Lurie et al. (1994), concluded therefore that absence of polydactyly cannot be used to distinguish the 2 syndromes.

Normally the Beemer-Langer type has no kidney abnormalities. The appearance is more hydropic than in other types. The appearance of the Beemer-Langer type is still very inconsistent

5.) The Asphyxiating thoracic dysplasia has characteristically trident iliac bones combined with renal cystic dysplasia.

In ATD and Ellis van Creveld dysplasia the ribs are not so extremely shortened as in type 1-4 of SRPS. Therefore the tubular bones show fewer dysplastic changes and the respiratory distress does not always lead to a fatal outcome.

The differentiation to other short rib polydactyly syndromes and chondroectodermal dysplasia consists in absence of cleft lip/palate and urogenital malformations.

The distinction between ATD and SRPS is not precise and in practice depends on the size of thorax and the lengths of infant's survival.

If the thorax is very small and patients die shortly after birth, the diagnosis is likely to be one of the SRP syndromes. If the thorax is larger and death occurs only after days or weeks, or the patient is surviving, the diagnosis is ATD.

Further more the term Asphyxiating thoracic dysplasia is confusing, because the disease is sometimes not asphyxiating at all. Some of the surviving patients have no respiratory symptoms in infancy or even in childhood. Some infants have only respiratory symptoms in conjunction with infection, who respond to standard treatment (Yang et al., 1987).

The polydactyly in Jeune syndrome is not obligatory. Surviving patients have a high rate of progressive renal disease. Radiograph of the patient in Fig. 2 show a typical feature of Jeune syndrome with small thorax, relative increase of cardio thorac diameter and "handle bar" appearance of clavicles. The radiographic features of type Verma-Naumoff and Jeune syndrome were qualitatively the same, but varied in severity, apart from the almost normal appearance of vertebral bodies in Jeune syndrom (Yang et al., 1987).

Type Verma-Naumoff and Jeune syndrome have in common metaphyseal irregularities, which distinguish them from EvC dysplasia. Usually patients with Jeune syndrome have no cleft/lip palate as SRPS type 1-4.

The relationship of ATD to EvC dysplasia was discussed for several years. Indeed the X-ray features of these two conditions are very similar, especially those of the pelvis. Moreover the presence of polydactyly and dental anomalies have been observed in ATD similar to those in EvC dysplasia. Despite these similarities, the two conditions are probably caused by two different gene mutations, the end results of which are similar.

6.) Contrary to other forms of the short rib dysplasia group Ellis van Creveld dysplasia is a well defined entity. Like ATD the Ellis van Creveld dysplasia has trident iliac bones but is distinguishable by the presence of ectodermal defects (nail dysplasia and sparse hair), cardiac defects (typically atrial septal defect), fusion of the hamate and capitate bones, and deformity of the proximal tibia. Radiologic similarities between ATD and Ellis van Creveld dysplasia are noted by several authors (Maroteaux et al., 1964; Langer, 1968; Kozlowski et al., 1972).

In general, congenital heart anomalies, and ectodermal dysplasia are specific to Ellis van Creveld dysplasia, as kidney disorders are more common in ATD and SRPS type Saldino-Noonan. Hyperplasia of the frena is one of the most important diagnostic features of EvC dysplasia.

The EvC dysplasia is characterized by the usually non-lethal disproportionate dwarfism due to chondrodysplasia of the long bones, bilateral postaxial polydactyly of the hands and sometimes of feet. The ectodermal defects are manifest in small and dystrophic nails, thin and sparse hair, and hypodontic teeth. The main syndroms of oral manifestation are hyperplasia of frena, hypoplastic maxilla and malocclusion.

The shortening of the ribs is usually slight, and not the main cause of death. The main death cause are cardiac malformation.

## 5.2. Interpretation of Clinical aspects

The morphological main features of the SRP dysplasia group are the shortening of the limbs and ribs, and the polydactyly of hands and feet. All these primary features point to abnormalities in the development of the bones.

The developmental events that result in this cluster of syndromes are thought to occur during the embryological period that begins at the time of conception and spans through the eight week of intrauterine life.

Following these malformations of bones all types of SRP dysplasia group seem to form a unit, because all types show shortening of long tubular bones, due to defective enchondreal ossification.

Polydactyly is the appearance of additional fingers or toes. Often the extra finger is incompletely developed and without functional fixation of the muscles; it is functionally worthless. The extra finger is placed more often on the ulnar and radial site than centrally, meanwhile the extra toe is mainly situated on the fibular site of feet.

Polydactyly is usually inherited on dominant way. The developmental errors leading to polydactyly are thought to occur just as bone shortening at 33 to 48 day of fetal life. All types of the short rib polydactyly dysplasia group, with exception of part of the Beemer-Langer type show polydactyly. The most part of the extremities development seems to pass in a normal way, apart from the short ribs, limbs, and polydactyly.

Therefore all types of SRP dysplasia group seem to form a unit in these points of feature.

The secondary functional respiratory problems are the result of the structural defect of ribs involving narrowness and immobility of the thoracic cage. These problems concern mainly the types 1-4, and the Jeune syndrome. If patients with Jeune syndrome are not troubled by respiratory problems, they especially suffer from renal problems. Patients with Ellis van Creveld dysplasia on the contrary mainly suffer from cardiac problems, which are the main cause of death in these cases.

Secondary malformations are variable in all types and stretch from anal atresia to cystic gallbladder. They are very inconsistent and serve only in combination as indication for differentiation.

Generally, it can be stated that all types of the short rib polydactyly dysplasia group form a clinical entity, with more or less considerable deviation. For example, as visible in table 8.1. all types have in common the short thorax. Another feature is the polydactyly of hand, which can be absent in type Beemer-Langer and Jeune syndrome.

Prevention of all kind of short rib polydactyly dysplasia group is still not known. Genetic counseling is indicated.

Prognosis: For the types 1-4 there no treatment is possible, because the malformations are too severe. If the patients do not die of asphyxiation in the first hours, they die of the occasional features, for example the cardiac malformations.

Most patients with Jeune syndrome do not survive early infancy. If the patient does survive the first months of life, death may later result from renal involvement. There is no effect upon intelligence in surviving patients.

The growth in length of long tubular bones is altered. Respiratory problems become less severe in older patients, but the thoracic malformations persist. Defects of renal function may sometimes occur in the second decade of life. Patients with EvC dysplasia have almost normal surviving rate, if they are free of cardiac malformations.

Treatment: It is not possible to treat patients with SRPS type 1-4, because malformations are too severe. There is only one case of these syndrome reported by Bidot-Lopez (1978), where the patient survived 8 weeks, but these case seem to be Ellis van Creveld dysplasia.

Jeune syndrome patients have a better prognosis, if respiratory infections are treated promptly, and affected infants are immunized early against such diseases as influenza, measles and pertussis.

Ellis van Creveld patients treatment consist of orthopedic correction of genu valgum, amputation of extra digits, and surgical repair of cardiac malformation.

The severe malformations of unusual dental findings have to be corrected by multidisciplinary treatment by dentists and orthodontists. All surgical interventions should be performed under prophylactic antibiotic coverage.

### 5.3. Interpretation of genetic aspects

Embryological correlation of SRPS was examined by Knapp et al. in 1990, especially the Majewski type, and Cherstvoy et al. in 1980.

The pathogenesis of these malformations is still undetermined.

Since the skeletal manifestations of SRPS are the most severe, the generalised abnormalities of all organ systems suggest a defect in regulation of cellular differentiation during early embryogenesis.

Therefore we have to make a short excursion into embryology: Most elements of bones derive from mesenchymal tissue, which is the origin of cartilage elements. Later these cartilage models ossify by way of endochondral ossification. A good example for the endochondral ossification is the development of long tubular bones.

After formation of the primary ossification center in the diaphysis, the growth in length at the end of the primordium follows the cartilage growth zone. After the development of another primary ossification center in the epiphysis, the cartilage growth zone becomes epiphyseal cartilage. The growth in length of the long tubular bones is maintained by the epiphyseal cartilage, i.e. by the small cartilage zone between dia- and epiphysis. The endochondral ossification of the skeleton of the extremities begins at the end of the embryonal period, i.e. at 6<sup>th</sup> week of gestation. The developmental errors leading to short rib polydactyly dysplasia group with regard to defective development of long tubular bones occur in this time, thus 33 to 48 days of fetal life (Carnegie stages 15 through 19).

The same affects the cardiogenesis, of which the critical period spans from 20<sup>st</sup> day of gestation until 50<sup>st</sup> day. In this time developmental disturbance causes many different anomalies. This explanation is valid for most organs affected by aberrations in the SRP dysplasia group, which in general occur from the 4<sup>th</sup> until 8<sup>th</sup> week of gestation.

All types of SRP dysplasia group have in common: they are all inherited as autosomal recessive traits and all children die during first days of life (except in the case of Bidot-Lopez, 1978). The bone dysplasia is associated with a number of different abnormalities. Possible explanations for this similarity are, according to Cherstvoy et al. :

1. all types are clinical variants of the same genetic defect;
2. the different types of SRPS are due to different alleles of the same gene;
3. all types are separate genetic entities;
4. some types are due to genetic variability and others are caused by different allelic

or non-allelic mutations.

The different clinical subtypes are not characterized on a molecular level yet. However, structural cytogenetic aberrations have been noted in two patients: A de novo 17q paracentric inversion mosaicism was reported in a patient with SRPS type Beemer-Langer by Chen et al. (1994).

Another case of familial pericentric inversion of chromosome 4 was reported in a patient with overlapping symptoms of Majewski type and Beemer Langer type by Urioste et al. (1994). The breakpoints were described as 4p16 and 4q13.2, respectively.

Interestingly Polymeropoulos et al. (1996) placed the gene for recessively inherited Ellis van Creveld dysplasia in the region of 4p16, proximal to the fibroblast growth factor receptor FGFR 3 locus, a mutation of which should also cause thanatophoric dwarfism (Rousseau, 1995).

The etiology of all parts of SRP dysplasia group is still uncertain, despite the fact that they are all inherited by autosomal recessive way. Detection of carrier is not known. Gene mapping and linkage is still unproved. Occurrence is still variable, and more precise data are not available, because the small number of patients did not allow statistical significant declarations.

All types of SRPS follow recessive mendelian inheritance. This conclusion is based on the observation of recurrence of Majewski syndrome in siblings born to unaffected parents and the presence of consanguinity in the parents of patients with Majewski syndrome (Chen, 1980; Temtamy, 1978; Black, 1982). The risk of recurrence for parents with one affected infant is 25 per cent.

The risk of recurrence for patients child is zero for the type 1-4 because affected individuals are not expected to survive to reproduce.

#### 5.4. Intrauterine sonographic diagnosis

The age of detectability of all types of SRP dysplasia group with severe malformations is relatively early. The condition may be recognized in the newborn period through clinical ultrasound.

Biometry of fetal long bones is an accepted method of determination for the gestational age in the second trimester. Long bones measurement has been established from nine week's gestation (Zorzoli et al., 1994), and is helpful if skeletal dysplasias are suspected.

Between 10 and 12 weeks of embryonal age, the extremities undergo changes in position, rotation and abduction that can readily be observed by transvaginal sonography (Timor-Tritsch et al., 1988). If there is a suspicion of skeletal dysplasias, all long bones should be measured sonographically. If there is a case of SRPS all long bones are likely to be shortened. The next step is the evaluation of chest and abdomen, to exclude constriction that may lead to pulmonary hypoplasia.

Hands and feet should be examined for syndactyly or polydactyly. If polydactyly is observed the skeletal dysplasia belongs to the category of SRP dysplasia group.

As an example we take the diagnosis of short rib polydactyly syndrome type Saldino-Noonan, which was recognized at 13 weeks gestation by Hill and Leary in 1998. All of the long bones measured < 3 mm in length. The normal length of bone should be 1 cm in this gestational age (Yang et al., 1991). All long bones were below the 5<sup>th</sup> percentile for the biparietal diameter. The fetal hand showed fan-shaped appearance, which is suspicious for polydactyly. There was marked disproportion between chest and abdomen. After dilatation and curettage, an autopsy confirmed the sonographic findings, and the final pathologic diagnosis was Saldino-Noonan short rib polydactyly syndrome.

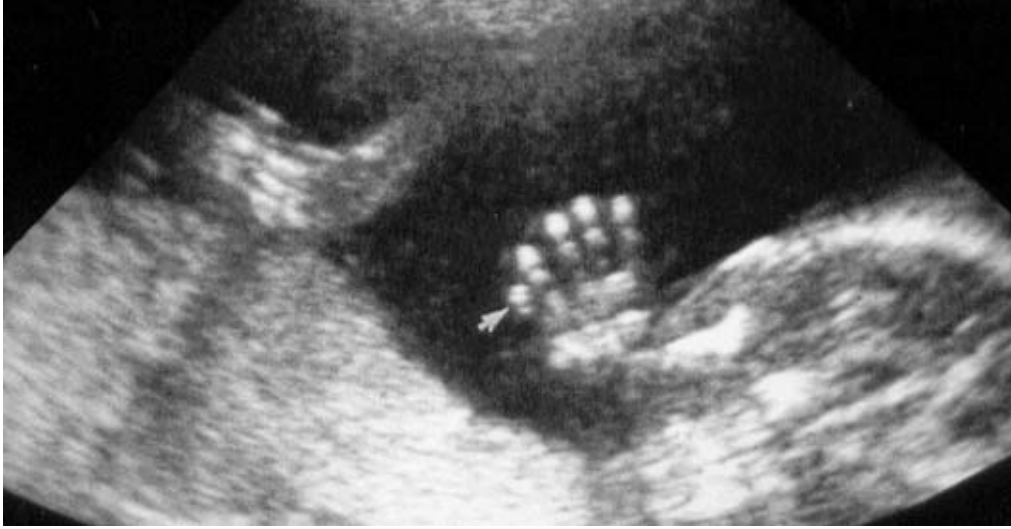But usually prenatal ultrasound diagnosis of the various skeletal dysplasias is made during the late second trimester of pregnancy (Hobbins et al., 1982; Wladimiroff et al., 1984).

The ultrasound diagnosis of Jeune syndrome (Elejade et al., 1985; Schinzel et al., 1985; Lipson et al., 1984) or chondroectodermal dysplasia (Mahoney and Hobbins, 1977) was made after the observation of long bone shortening at second trimester or later, commonly after 18 weeks of gestation.

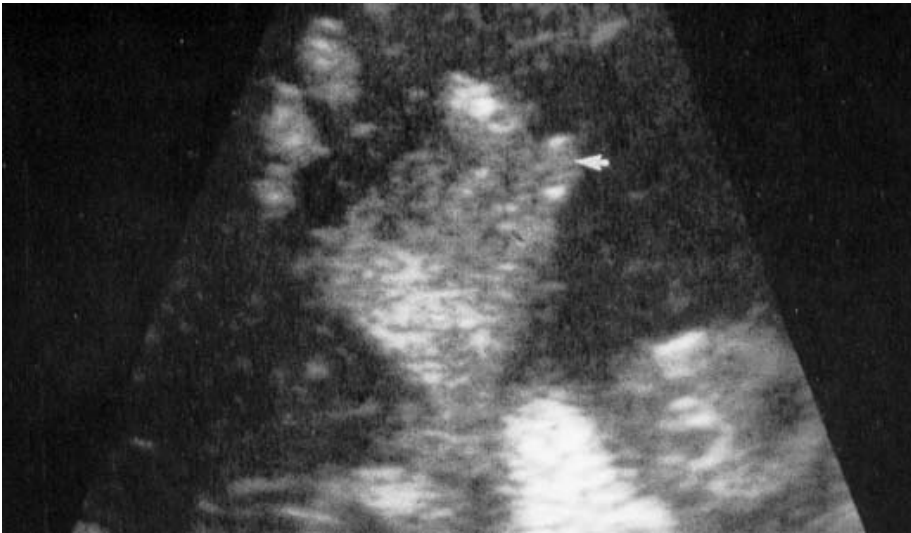The differential diagnosis between Jeune syndrome and chondroectodermal dysplasia is made by the degree and type of limb shortening and the evidence of other skeletal anomalies, like narrow chest, skull malformations or polydactyly. A detailed examination of the cardiovascular, genito-urinary, gastrointestinal and central nervous systems organs may give indications for extraskelatal anomalies.

The following ultrasound pictures show typical signs of possible indications for the short rib polydactyly dysplasia group.



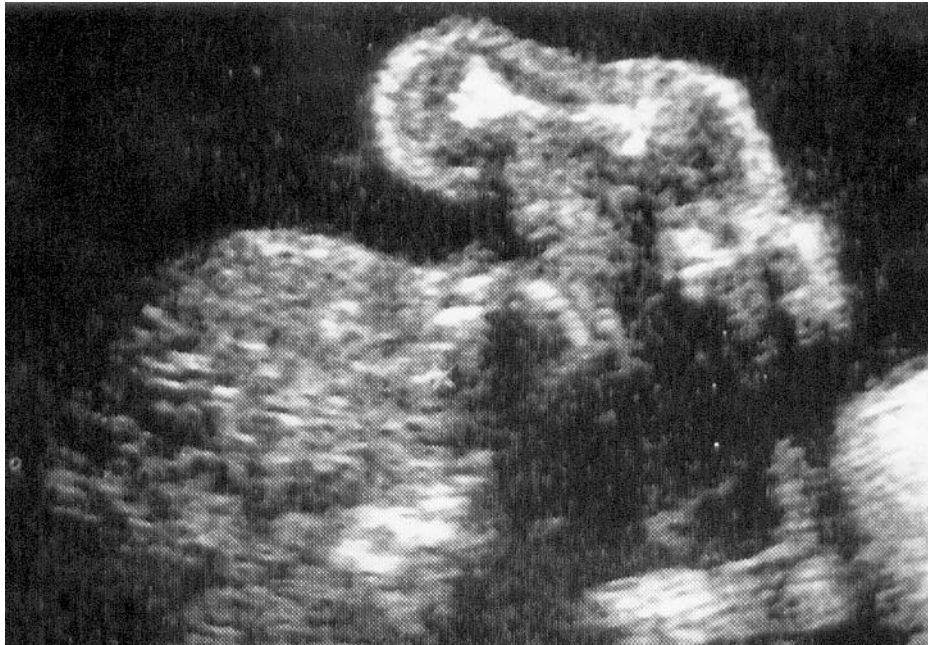

A:

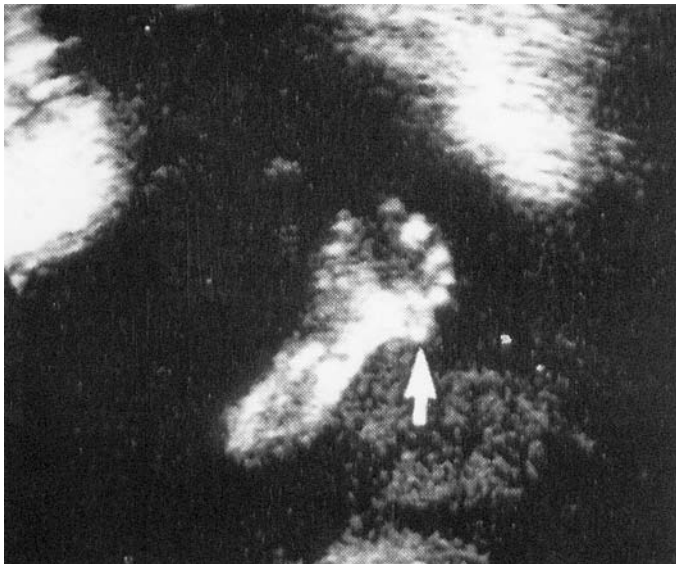


B:

Fig. 5.4.1. **A:** Postaxial polydactyly. View of the digits of a fetus with trisomy 13 and postaxial polydactyly. The arrow indicates the location of the extra digit. **B:** Preaxial polydactyly. View of the palm of the hand of a fetus with duplicated thumb (arrow) : Benacerraf, B.R., 1997, Ultrasound of fetal syndromes, Churchill Livingstone, N.Y., : 61-62)



A:



B:

Fig. 5.4.2. : **A:** Shortened humerus with widened metaphyses typical of short rib polydactyly syndrome, type 3. **B:** Evidence of polydactyly (arrow) in the same fetus as depicted in figure **A** with short rib polydactyly syndrome, type 3. (Meizner, I., Barhard, I., 1995, SRPS Type 3 diagnosed during routine prenatal ultrasonographic screening. A case report. Prenat. Diagn., 15: 665-668)

## 5.5. Classification of SRP dysplasia group

Some authors suggest that all types of SRP dysplasia group constitute a single entity with variable expressions (Bernstein et al., 1985;).

Martinez-Frias et al. suggested a single entity encompassing all types of lethal SRPS, based on intrafamilial overlapping of SRPS.

A continuous spectrum was also suggested by Beemer in 1983. It is not easy to distinguish all types at the first attempt, but all in all every type has its own form as a separate entity with the specific symptoms, that constitute one type. It is not possible to distinguish exactly the different types only by the way of short ribs or polydactyly, at the most it is possible to distinguish Jeune syndrome and the Ellis van Creveld dysplasia from the type 1-4, because the former have less shortened ribs. All symptoms together form for every type a characteristic picture that can be recognized by the described combination of morphology, radiology and sometimes histology.

Table 8.1.- 8.3. are designed as a help to decide which type is present. If the ribs are extremely shortened the diagnosis for type 1-4 is probable. If they are less shortened the diagnosis of Jeune syndrome or Ellis van Creveld syndrome is more likely.

The next distinguishing feature is polydactyly of hands which is occasionally absent in Beemer-Langer type and Jeune syndrome.

The next characteristic of type 1-4 are the low set ears, and cleft/lip palate, which do not occur in Jeune- and Ellis van Creveld syndrome. This is also valid for the appearance of narrow chest, which is not characteristic for the last two types.

A saddle shaped nose occurs often in type 2, 3, and 4, sometimes in type 1 and EvC dysplasia, and hardly in Jeune syndrome. Oesophageal and anal atresia are being found especially in Saldino-Noonan type.

Congenital heart disease occurs often in Saldino-Noonan type and EvC dysplasia, meanwhile Majewski type and Jeune syndrome show kidney anomalies. In Majewski type often additional genitourinary tract anomalies, hepatosplenomegaly and ascites occurs. Fibrosis of pancreas was reported in all types except of EvC dysplasia.

Characteristic particularly for Ellis van Creveld dysplasia are the hypoplastic maxilla, malocclusion and dystrophic nails.

Occasional syndromes reported in one single patient are not mentioned and practically in every category „others“ should be added. Controversies regarding the classification of some disorders as Beemer Langer type are common and await further analysis.

At first glance there is close relationship between type Saldino-Noonan and Verma-Naumoff, just as between type Majewski and Beemer-Langer. But further analysis show differences which justify a classification as separate entity. All in all the classification of the 2nd revision by the international working group on bony dysplasias in Bad Honnef in 1991 is confirmed ( Beighton et al., 1992 ).

## 6. Summary

The short rib polydactyly dysplasia group is part of the „Defects of the tubular (and flat) bones and/or axial skeleton“, which is a subdivision of the Osteochondrodysplasias.

The short rib polydactyly dysplasia group consists of the inevitable lethal group of the type 1 Saldino-Noonan syndrome, the type 2 Majewski syndrome, the type 3 Verma- Naumoff and the type 4 Beemer-Langer syndrome which are all characterized by severe shortening of the long tubular bones, especially the ribs, and polydactyly which can be absent in type Beemer- Langer.

The main cause of death in this first group is asphyxie due to the short ribs.

The second group contains the Asphyxiating thoracic dysplasia, although called Jeune syndrome and the Ellis van Creveld dysplasia, also called Chondroectodermal dysplasia, which have both better surviving rates than SRPS Type 1-4. The main cause of death of Jeune syndrom is also asphyxie. The cause of death of the Ellis van Creveld are mostly cardiac malformations.

Incidences of SRP dysplasia group differ from author to author, and because of the paucity of cases it is impossible to edit exact data, but incidence are between 1/ 50.000-100.000.

The exact genesis of the short rib polydactyly dysplasia group is still unknown, but there are indications that structural cytogenetic abberations are involved at the genesis of SRP dysplasia group. The malformations have to occur during the embryological period that begins at the time of conception and spans through the eight week of intrauterine life. An exact association with the day of gestation is not possible.

The confusing mass of publications of SRP dysplasia group with its different priorities of description require a obligatory manual for the description of osteochondrodysplasias. This work is a first step in this direction.

To facilitate the classification of every short rib polydactyly syndrome a full autopsy should be performed with photographs of the entire body anterior-posterior few, both profiles, and close-up views of interesting aspects. Complete radiological assessment is very important for the diagnosis of short rib polydactyly syndrome. Histologic section should contain a part of every organ concerned. Both, anomalies and normal picture of one organ should be described to complete a consistent histopathologic picture.

The comparison of short rib polydactyly dysplasia group followed the international working group on bone dysplasias in Bad Honnef in 1991 (Beighton et al., 1992 ). The result of this working group is essentially confirmed. The six different types are listed and characteristics of morphological aspects, radiology and histology findings are described.

The discussion is a kind of differential diagnosis of the short rib polydactyly dysplasia group, and compares each type with it's own characteristics with the other five one.

A classification entails the possibility to examine a certain disorder at a certain point of time. There is no doubt that scientific progress and experience make a revision necessary. We hope that this comparison and classification facilitates further progress in this way.

## 7. References:

Balci, S., Ercal,MD, Onol, B., Caglar, M., Dogan, A., Dogruel, N., 1991: Familial short rib syndrome, type Beemer, with pyloric stenosis and short intestine, one case diagnosed prenatally., Clin. Genet. 39: 298-303. ;

Bard, L. A. , Bard, P. A., Owens, G. P., and Hall, B. D., 1978, Retinal involment in thoracic- pelvic-phalangeal dystrophy, Arch. Ophthalmol. 96: 278-281. ;

Barnes, N.D., Hull, D., 1961: Thoracic dystrophy, Arch. Dis. Child. 44: 11-17. ;

Barnes, N.D., Hull, D., Milner, A.D., and Waterstone, D.J., 1971, Chest reconstruction in thoracic dystrophy, Arch. Dis. Child. 46: 833-837. ;

Beckwitt, S., Turkel, S., Diehl, E.,, 1985, Necropsy findings in neonatal asphyxiating thoracic dystrophy, J. Med. Genet. 22: 112-118. ;

Beemer, F.A., Langer, L.O., Klep-de Pater,J.M., Hammes,A.M., Bylsma,J.B., Pauli, R.M., Myers,T.L., and Haws,C.C., 1983, A new short rib syndrome: Report of three cases. Am. J. Med. Genet. 14:115-123. ;

Beighton, P., Giedion, Z., Gorlin, R., 1983, International nomenclature of constitutional diseases of bone, Ann. Radiol. (Paris) 26: 457.;

Beighton, P., Kozlowski, R., 1992, International Classification of Osteochondrodysplasias, American Journal of Medical genet.: 44: 223-229. ;

Belloni, C., and Beluffi, G., 1981, Short rib-polydactyly syndrom, type Verma Naumoff, Fortschr. Röntgenstr. 134: 431-435.;

Bergström, K., Gustavson, K.H., Jorulf, H.,and Sundström, C., 1979 A case of Majewski syndrome with pathoanatomic examination, Skeletal Radiol. 4: 134-140. ;

Bernstein, J., Broughs, AJ, Mc Adams AJ, 1974, The renal lesion in syndromes of multiple congenital malformations: Jeunes asphyxiating thoracic dystrophy, 1974 Birth defects 10: 35-43. ;

Bernstein, R., Isdale, J., Pinto, M., Du Toitzaaijman, Jenkins , T., 1985, Short rib polydactyly syndrom : a single or heterogenous entity? J. Med. Genet., 22: 46. ;

Bidot-Lopez, P., Ablow, R.C., Ogden, J.A., and Mahoney, M., 1978, A case of short rib polydactyly, Pediatrics 61: 427-432. ;

Biggerstaff, R., 1968, Oral manifestations of the Ellis van Creveld syndrome, J. Am. Dent. Assoc. , 77: 1090-1095. ;

Böhm, N, Karitzky, D., 1978, Chondroectodermal dysplasia with dysplasia of renal medulla and bile ducts, *Histopathology* 2: 267-281. ;

Black, I.L., Fitzsimmons, J., Fitzsimmons, E., and Thomas, A.J., 1982 Parental consanguinity and the Majewski syndrom, *J. Med. Genet.* 19: 141-143. ;

Bomann, H., Hoel, P.S., Lunde, O., Omsjo, I., 1982, Short rib polydactyly syndrom type Saldino- Noonan, *Clin. Genet.* 24: 267-281. ;

Borochowitz, Z., Rimoin, D.L., 1993, Skeletal pathology: The congenital chondrodysplasias. In Reed, G.B., et al.: *Diseases of the Fetus and Newborns*. 2<sup>nd</sup> edition. London: Chapman and Hall.

Brenner, R.E. , Nerlich, A., Kircner, F., 1993, Proliferation and collagen biosynthesis of osteoblasts and chondrocytes in short rib syndrome type Beemer. *Am. J. Med. Genet.* 46: 584-591. ;

Bronstein, M., Keret, D., Deutsch, M., Liberson, A., Barchava, I., 1993, Transvaginal sonographic Detection of skeletal anomalies in the first and early second trimester. *Prenat. Diagn.*, 13: 597-601. ;

Bronstein, M, Reichler, A., Borochowitz, Z., 1994: Early prenatal diagnosis of polycystic pancreas with narrow thorax and short limb dwarfism. *Am. J. Med. Genet.* 49: 67-69. ;

Brueton, L.A., Dillon, MJ, Winter, R., 1990, Ellis van Creveld syndrom, Jeune syndrom and renal hepatic pancreatic Dysplasia: Separate entities or disease spectrum? *J. Med. Genet.* 53: 252- 255. ;

Bui, T.H., 1984, Prenatal diagnosis of chondroectodermal dysplasia with fetoscopy, *Prenatal Diag* 4: 155-159. ;

Calvin, H., 1990, Laryngeal findings in Short rib polydactyly Syndrome: Case Report and Embryological Correlations, *Laryngoscope* 100: 579-582. ;

Chen, H., Yang, S.S., Gonzalez, E., Fowler, M., and Al Saadi, A., 1980, Short rib polydactyly syndrome, Majewski type, *Am. Med. Genet.* 7: 215-222. ;

Chen, H., Yang S: S., Gonzalez, E., 1989: Short rib syndrome without polydactyly., *J. Med. Genet.* 26: 346- 349.;

Chen, H., 1992: A de novo 17q paracentric inversion mosaicism in a patient with Beemer Langer type short rib polydactyly syndrome. Presented at the First Annual Meeting of Bone Dysplasia Society. Chicago, June, 1992 ;

Cherstvoy, E.D., Lurie, I.W., Shved, I.A., Lazjik, G.I., Ostrowskaya, T.I., and Usoev, S.S., 1980, Difficulties in classification of the short rib poly dactyly syndromes, Eur. J. Pediatr. 133: 57-61. ;

Cideciyan, D, Rodriguez, MM, Haun, RL; 1993: New findings in short rib syndrome. Am. J. Med. Genet. 46: 255-259. ;

Cooper, P.C., and Hall, C.M., 1982, Lethal short rib polydactyly syndrome of the Majewski type. A report of three cases. Radiology 144: 513-517. ;

Cortina, H., Beltran, J., Olague, R., Ceres, L. , Alonso, A., and Lanuza, A., 1979, The wide spectrum of the asphyxiating thoracic dysplasia, Pediatr. Radiol. 8: 93-98. ;

Christo, G.G., Subbalaxmi Murthy, V., Kapadia R.D., Xavier, C., Venkatesh, A., 1987, SRPS type Saldino-Noonan, Indian Pediatr. 24: 585. ;

Cremin, B.J., and Beighton, P., 1974, Dwarfism in the newborn: The nomenclature, radiological features and genetic significance. Br. J. Radiol.47: 77. ;

Cremin, B.J., and Beighton, P., 1978, Lethal short rib polydactyly syndromes. In: Bone dysplasia of Infancy New York: Springer-Verlag, Chapter 7: 37-44. ;

Curran, J.P., Sigmon, B. A. and Opitz, J. M. 1974. Lethal form of chondroplastic dwarfism. Pediatrics 53: 76-85. ;

De Sierra, T.M., 1992, Prenatal diagnosis of short rib polydactyly syndrome with situs inversus, Am. J. Med. Genet 44: 555-557.;

Dvore, G.R., Miller, J., 1979, Diagnosis of structural abnormalities in fetus, Clin. Perinat., 6: 293-96. ;

Donaldson, M.D.C., Wanrer, A.A., Trompeter, R.S., Haycock, G.B., and Chantler, C., 1985, Familial juvenile nephronophthisis, Jeune syndrome and associated disorders, Arch. Dis. Child. 60: 426- 434. ;

Edelson, P, Spackman, PJ, 1974: A renal lesion in asphyxiating thoracic dysplasia 1974, Birth Defects 10: 51-56. ;

Elejade, B.R., 1985, Prenatal diagnosis of Jeune syndrome. Am J Med Genet 21: 433-438. ;

Ellis, R.W., van Creveld, S., 1940, Syndrome characterized by ectodermal dysplasia, polydactyly, chondro dysplasias and congenital morbus cordis, Report of 3 cases, Arch. Dis. Child, 15: 65-84. ;

Encioglu, N., Karatekin, G., Sezgin, B., Nuhoglu, A., Cenani, A., 1996, Short rib polydactyly syndrom in twins : BeemerLanger type with polydactyly., Clin. Genet., 50: 159-163. ;

Eyre, D.R., Upton, M.P., Shapiro, F.D., Wilkinson, R.H., and Vawter, G.F., 1986, Nonexpression of cartilage type 2 collagen in a case of Langer-Saldino achondrogenesis, Am. J. Hum. Genet. ,39: 52-67. ;

Finegold, M.J., Katzew, H., Genieser, NB, 1971: Lung structure in thoracic dystrophy. Amer. J. Dis. Child. 122: 153-159.;

Franceschini, P., Guala, A., Vardeu, M.P., Signorile, F., Franceschini, D., Bolgiana, M.P., 1995, Short rib dysplasia group ( with/ without polydactyly) : report of a patient suggesting the existence of a continuous spectrum, Am. J. Med. Genet., 59(3) : 359- 364.;

Francomano, C.A., 1995: The gene for Ellis van Creveld syndrome maps to chromosome 4p16. , Am. J. Med. Genet., 57: 191.;

Filly, R.A.,Golbus, MS, Carry, JC, 1981, Short limbed dwarfism: Ultrasonographic diagnosis by mensuration of fetal femoral lenght; Radiology, 138: 653-656

Friedman, J.M., Kaplan, H.G., and Hall, J.G., 1975, The Jeune syndrom in an adult, Am. J. Med., 59: 857-862.;

Garcia, H., Drescher, H., Kuchelmeister, K.; Lenz, A., Roessner, A., 1988, Short rib polydactyly syndromes, Pädiatr., 200: 140-144.;

Gembruch, U., Hansmann, M., Födisch, H.J., 1985, Early prenatal diagnosis of Short rib polydactyly syndrom type Majewski by ultrasound in a case of risk, Prenatal diagnosis; Vol 5, 357-362.;

Giedon, A., 1981, Osteochondrodysplasien, in: Lehrbuch der Röntgendiagnostik, Vol 2, Part, H.R. Schinz, W.E. Baensch, W. Frommhold, R.Glauner, E. Uehlinger, and J. Wellauer, Thieme, Stuttgart, pp. 6-171.;

Gilbert-Barness, E., 1996, Abnormal bone developpment: Histopathology of skeletal dysplasias, In Martini–Neri, M., (eds) „Gene Regulation anf Fetal Developpment“ N.Y., Wiley –Liss: 103-156.;

Gordon, I.R.S., Brown, N.J., 1976, The syndrom of micromelic dwarfism and multiple anomalies, Ann. Radiol., 19: 161-165.;

Grote, W., Weisner, D., Jänig, U., Harms, D., and Wiedmann, R.H., 1983 ,Prenatal diagnosis of a short rib polydactyly syndrom type Saldino Noonan at 17 weeks gestation, Eur. J. Pediatr., 140: 63-66.;



Gruskin, A.B., 1974: The renal disease of thoracic asphyxiant dystrophy. Birth Defects 1974: 10: 44-50.;

Habeck, J.O., Künzel, W., Müller, D., Tode, G., and Schmidt, J., 1982, Kurzrippen Polydactily Syndrom Typ 3 mit Zeichen einer ektodermalen Dysplasie, Zentralbl. Gynäkol., 104: 568-575.;

Hayashi, I., and Okamoto, N. 1984 Survey of 10834 autopsy cases of human embryos, fetuses and newborns, p. 96-104, Atlas of human congenital malformations. Maruzen hirishima publishing service center, Hiroshima.

Hennekam, R.C.M., 1991, Short Rib syndrome-Beemer type in sibs, Am. J. Med.: Genet. 40: 230-233.;

Herdmann, R.C., 1968: The thoracic asphyxiant dystrophy and renal disease. Am. J. Dis. Child.1968: 116: 192-201.;

Himelhoch, D.A., Oral abnormalities in the Ellis van Creveld syndrome : A case report, Pediatr. Dent. 1988: 10: 309-313.;

Hirokawa, K., 1967: Ellis van Creveld dysplasia; report of an autopsy case. Acta Path. Jpn. 17: 139- 143.;

Hobbins, J.C., 1980: The diagnosis of skeletal dysplasias with ultrasound. In Sanders,R.C., James, A.E. (eds): „ The principles and practice of Ultrasonography in Obstretics and Gynecology.“ 2<sup>nd</sup> Ed. New York: Appletons Century Crofts, 191-203.;

Hobbins, J.C., Dugoff, C., 1982, Diagnosis of fetal skeletal dysplasias with ultrasound, Am. J. Obstet. Gynecol. 142, 306-312.;

Hudgins, L., Rosengren, S., Treem, W., 1992: Early cirrhosis in survivors with Jeune thoracic dystrophy. Pediatrics 120: 754-756.;

International nomenclature of constitutional disease of bone, , 1978, J. Pediatr. 93: 614-616.;

Jequier, J.C., :Asphyxiating thoracic dysplasia. In H.J. Kaufmann : Progress in pediatric radiology., Basel: S. Karger 1973, Bd. 4, Intrinsic disease of bones, 184.;

Jeune, M., Beraud, C., and Carron, R., 1954: Dystrophie thoracique asphyxiante de caractere familial, Arch. Fr. Pediatr. 12: 886-891.;

Johnson, V.P., 1982, Midtremester prenatal diagnosis of short limb dwarfism (Saldino-Noonan type): Birth defects: Original article series 13: 133-141.;

Kaibara, N., Eguchi, M., Shibata, K., and Takagishi, K., 1980, Short rib polydactyly syndrom type 1, Saldino Noonan, Eur. J. Pediatr. 113: 63-65.;

Karjoo, M., 1993, Pancreatic exocrine enzyme deficiency associated with asphyxiating thoracic dystrophy. Arch Dis Child 48(1993) 143-146.;

Keating, S.J., Eyre, D.R., Pritzker, K.P., 1989, Short rib polydactyly syndrome type 1: an autopsy approach to diagnosis of chondrodysplasias. Mod. Pathol. 1989 Sep. 2 (5) : 427-32.;

Kotte, W, Kunze, P., Eichhorn, D., 1972: Die familiäre asphyxierende Thoraxdystrophie (Maladie de Jeune); Ein Beitrag zur DD des disproportionierten Zwergwuchses. Kinderärztl Prax 40:83-92.;

Kozlowski, K., and Masel, J., 1976, Asphyxiating thoracic dystrophie without respiratory disease, Pediatr. Radiol. 5: 30-33.;

Kozlowski, K., and Masel, J., Morris, L., Ryan, L., Collins, E., Van Vliet, P., Woolnough, H., 1977, Neonatal death dwarfism (report of 17 cases) Aust. Radiol. 21:164-183.;

Krepler, R., Weissenbacher, G., Leodolter, S., Myller-Tyl, E., 1976, Nicht lebensfähiger, mikromeler Zwergwuchs: Thorax-dystrophie-Polydaktyly syndrom Typ Saldino-Noonan, Monatsschr. Kinderheilk. 124: 167-173.;

Lachmann, R.S., 1994. Fetal imaging in the skeletal dysplasias: overview and experience, Pediatr. Radiol., 24: 413-417.;

Langer, L.O., 1968, Thoracic-pelvic-phalangeal dystrophy, Radiology 91: 447-456.;

Lavanya, R., Pratap, K., 1995, Short rib polydactyly syndrome a rare skeletal dysplasia, Int. J. Gynaecol. Obstet. 50(3) : 291-292.;

Le Marec, B., Passarege, E., Dellenbach, P., Kerisit, J., Signargout, J., Ferrand, B., and Senecal, J., 1973, Les formes neonatales lethales de la dysplasie chondroectodermique, Ann. Radiol.. 16: 19-26.;

Leroy, J., 1978, Saldino-Noonan short rib polydactyly dwarfism syndrom. Clin. Genet. 13: 127.;

Lipson, M., Waskey, J., Rice, J., Adomian, G., Lachmann, R., Eilly, R., and Rimoin, D., 1984, Prenatal diagnosis of asphyxiating thoracic dysplasia, Am. J. Med. Genet. 18: 273-277.;

Lowry, R.B., and Wignall, N., 1975, Saldino Noonan short rib polydactyly dwarfism syndrom, Pediatrics 56: 121-123.;

- Lurie, WL, 1994: Further delineation of the Beemer-Langer syndrome using concordance rate in affected sibs. , Am. J. Med. Genet.:50: 313-317.;
- Lungarotti, D., 1993, Lethal SRS of the Beemer type without polydactyly, *Pediatr. Radiol.* 1993: 325-326.;
- Lyndon, M. Hill and Janice Leary, 1998, *Prenatal diagnosis* 18: 1198- 1201.;
- Mahoney, M.J., Hobbins, MC, 1977: Prenatal diagnosis of chondroectodermal dysplasia with fetoscopy and ultrasound, *N England J Med* 297: 258-260.;
- Majewski, E., Pfeiffer, A., Lenz, W., Müller, R., Feil, G., and Seiler, R., 1971, Polysyndaktilie, verkürzte Gliedmassen und Genitalfehlbildung: Kennzeichen eines selbstständigen Syndroms ?; *Z. Kinderheilk.* 111: 118-138.;
- Majewski, E., Ozturk, B., Gillesen-Kaesbach, G., Jeune syndrom with tongue lobulation and preaxial polydactyly, and Jeune syndrom with situs inversus and asplenia: compound heterozygosity Jeune-Mohr and Jeune- Ivermark?; *Am J. Med: Genet.* 1996, May 3 63, 74-79.;
- Martinez-Frias, M.L., Bermejo, L., Urioste, M., 1993a, Short rib polydactyly syndrome with anencephaly and other CHS Anomalies: A new type of SRPS or a more severe expression of known SRPS entity ?, *Am. J. Med.* 47: 782- 787.;
- Martinez-Frias, M.L., Bermejo, L., Urioste, M., 1993b, Lethal short rib polydactyly syndromes: Further evidence for their Overlapping in a continuous spectrum. *J. Med. Genet.* 30: 937- 941.;
- Maroteaux, P., and Savart, P., 1964, La dystrophie thoracique asphyxiant: Etude radiologique et rapports avec le Ellis van Creveld syndrone, *Ann. Radiol.* 7: 332-338.;
- Maroteaux , P., Lamy, M., and Robert, J.-M., 1967, Le nanisme thanatophore, *Presse Med.*, 75: 2519-2524.;
- Mc Cormac, R.M., 1984. Short Rib Polydactyly syndrome type 2, *Pediatric Pathology*, 2: 457-467.;
- Mc Kusick, V.A., 1978, Mendelian inheritance in Man. Catalogs of Autosomal dominant , Autosomal recessive, and X-linked Phenotypes. 5 th ed. John Hopkins University Press, Baltimore.
- Mc Kusick, V.A., Egeland, J.A., Eldrige, R., Krusen, D., 1964, Dwarfism in the amish. The Ellis van Creveld syndrom. *Bull. John Hopkins Hos.* 116: 286-326.;
- Meizner, I., Barhard, I., 1995, SRPS type 3 diagnosed during routine prenatal ultrasonographic screening, A case report. *Prenat. Diagn.*, 15: 665-668.;

Miriam L. Richardson, 1977, Prenatal diagnosis of recurrence of Saldino-Noonan dwarfism, *The Journal of Pediatrics*, Sep.: 467-471.;

Mishra, O.P., 1991, SRPS (type Saldino-Noonan); *Indian Pediatrics*, 28: 1063-1065.;

Mitchell, F.N., 1958, Ellis van Creveld syndrome, report of two cases in siblings. *Acta Paediat.* 47: 142-151.;

Moerman, P., Fryns, J.P., 1998, Oral-facial-digital syndrome type 4(Mohr-Majewski syndrome): a fetopatological study; *Genetic counseling*, Vol 9, No.1 1988: 39-43.;

Montemarano, H., Bulas, D.I., Chandra, R., Tiff, C., 1995, Prenatal diagnosis of glomerulocystic kidney disease in short rib polydactyly syndrome type 2, Majewski type, *Pediatr. Radiol.*,25(6) 469-471.;

Motegi, T., Kusonoki, M., Nishi, T., Hamada, T., Sato, M., Imamura, T., and Mohri, N., 1979, short rib polydactyly syndrom, Majewski type in two male siblings, *Hum. Genet.* 49:269-275.;

Myong, N.H., Park, J.W., Chi, J.G., 1998, Short rib polydactyly syndome, Beemer-Langer type, with bilateral huge polycystic renal dysplasiy: an autopsy case. *J. Korean Med. Sci.*, 13: 201-206.;

Naumoff, P., Young, L.W., Mazer, J., and Amortegui, A.J., 1977, Short rib polxdactyly syndrome type 3, *Radiology* 122: 443-447.;

Nagai, T.,1995, Del 12 associated with an asphyxiating thoracic dysplasia or chondroectodermal dysplasia like syndrome., *Am. J. Med. Genet.* 55: 16-18.;

Oberklaid, F., Danks, D.M., Mayne, V., and Cambell, P., 1977, Asphyxiating thoracic dysplasia, *Arch. Dis. Child.* 52: 758-765.;

Orioli, I.M. , Castilla, E. E. , and Barbosa-Neto, J. G. ,1986 The birth prevalence rates for the skeletal diseases, *J. Med. Genet.*, 23: 328-332.;

Parenti, G.C., 1936, La anosteogenesi, *Pathologica* 28:447-461.;

Passarge, E., 1983, Familial occurence of a short rib polydactyly syndrome with hydrops fetalis but without polydactyly, *Am. J. Med. Genet.*, 14: 403-405.;

Piepkorn, M., Karp, L.E., Hickock, D., Wiegenstein, L., and Hall, J.G., 1977, A lethal neonatal dwarfing condition with short ribs, polysyndactyly, cranial synostosis, cleft palate, cardiovascular and urogenital anomalies, and severe ossificaton defect, *Teratology* 16: 345-350.;

Pirnar, T, 1966:Asphyxiating thoracic dystrophy of the newborn. Am. J. Roentgenol. 98: 358-364.;

Polymeropoulos, M.H., 1996: The gene for the EvC syndrome is located on chromosome 4p 16q. Genomics 35: 1-5.;

Quennan, J.T., 1980, Ultrasound measurement of fetal limb bones, Am. J. Obstet. Gynecol., 138: 297-302.;

Quereshi, S., Hogan, M., 1993, Skeletal histopathology in fetuses with EvC-syndrome; Am. J. Med. Genet. 1993, 45: 471-476.;

Reid, C.S., Barlow, S., 1985: Phenotypic heterogeneity in the Jeune syndrome. Pediatr. Res. 19: 329.;

Reid, C.S., Hewlett, M., 1986: Clinical findings in the Jeune syndrome, Am J Human Genet 39: 76.;

Reiterer, F., Muller, W., Wendler, H., 1986: Variance in the clinical picture of ATD ; Klin. Pädiatr. 1986, Jul-Aug; 1984: 340-343.;

Rhagvan, K.R., 1983, Short rib polydactyly syndrome (Majewski type), Indian Pediatr. 20: 870-873.;

Richardson, M.M., Beudet, A.L., Wagner, M.L., Malini, S., Rosenberg, H., and Lucci, J.A., 1977, Prenatal diagnosis of recurrence of Saldino-Noonan dwarfism, J. Pediatr. 91: 467-471.;

Rupprecht, E., Justus, J., 1974: Thanatophorer Zwergwuchs. Pädiatr. Grenzgeb. 13: 365-372.;

Rupprecht, E., Gurski, A., 1982, Kurzrippen Polydactayly Syndrom Typ Saldino-Noonan, bei zwei Geschwistern, Helv. Pediatr. Acta 37: 161-169.;

Russel, J.G.B., 1970: Asphyxiating thoracic dystrophy of the newborn. Br. J. Radiol. 43: 814-815.;

Saldino, R.M., 1973, Radiographic diagnosis of neonatal short limbed dwarfism, Med. Radiog. Photog., 49: 61-93.;

Saldino, R.M., Noonan, C.D., 1972, Severe thoracic dystrophy with striking micromelia, abnormal osseous development, including the spine, and multiple visceral anomalies, Am. J. Roentgenol. 114: 257-263.;

Sarimurat, N., Elcioglu, N., 1998: Jeune`s asphyxiating thoracic dystrophy of the newborn. Eur J Pediatr Surg. 1998 Apr. 8 (2): 100-101.;

Schimitz, R., Hamid, N., 1972: Unusual features in familial asphyxiating thoracic dysplasia. Clin. Genet. 3: 90-98.;

Schinzel, A., 1985: Prenatalsonographic diagnosis of Jeune syndrome. Radiology 154: 777-778.;

Schlenkser, K.H., 1981, Die sonographische Darstellung der fetalen Extremitäten im mittleren Trimenon, Geburtshilfe-Frauenheilkunde, 41: 366-373.;

Schmidt, R., Pajewski, N., 1972: Unusual features in familial asphyxiating thoracic dystrophy. Clin Genet 3: 90-98.;

Sha, K.J.,1980 : Renal lesion in Jeunes syndrome., Br. J. Radiol. 53: 432-436.;

Shiang, R., 1994: Mutations in the transmembrane domaine of FGFR3 cause the most common genetic form of Dwarfism, achondroplasia. Cell 1994: 78: 335-342.;

Shokeir, M.H.K., Houston, CS., 1971: Asphyxiating chondrodystrophy: association with renal disease and evidence for possible heterozygous expression. J. Med. Genet. 1971: 8: 107- 112.;

Sillence, D.O., 1980, Invited editorial comment: Non Majewski short rib polydactyly syndrome, Am. J. Med. Genet. 7: 223-229.;

Sillence, D.O., Kozlowski, K., Bar-ziv, J., Fuhrmann-Rieger, A., Fuhrmann, W., and Pascu, F., 1987, Perinatally lethal short rib polydactyly syndromes,1., Variability in known syndromes, Pediatr. Radiol. 17: 474-480.;

Sillence, D.O.,1980, Invited editorial comment: Non Majewski short rib polydactyly syndrome, Am. J. Med. Genet. 7: 223- 229.;

Skiptunas, S.M., Weiner, S., 1987: Early prenatal diagnosis of asphyxiating thoracic dysplasia (Jeune syndrome). Value of fetal thoracic measurement. J. Ultrasound Med.1987, Jan; 6(1): 41-43.;

Sommer, A., Mulne, A., Cordero, L., 1977, The Majewski syndrome a case report. Birth defects,Orig. Art. Ser. 13: 257-258.;

Smith, H.L., Jones, M., 1958, Chondroectodermal dysplasia, Report of a case. Pediatrics 21: 298- 307;

Special report 1978: International nomenclature of constitutional diseases of bone. Am. J. Roentgenol.131, 352-354.;

Spranger, J., Grimm, B., Weller, M., Weissenbacher, G., Herrmann, J., Gilbert, E., and Krepler, R., 1974, SRP syndrome, types Majewski and Saldino Noonan, Z. Kinderheilkunde, 116: 73-94.;

Spranger, J., Maroteaux, P., 1990, The lethal osteochondrodysplasias, Adv. Hum. Genet. 19: 1-103.;

Stoll, C., Dott, B., Roth, M.P., and Alembik, Y., 1989, Birth prevalence rates of skeletal dysplasias, Clin. Genet. 35: 88-92.;

Stromme Koppang, H., Boman, H., Hoel, P.S., 1983, Oral abnormalities in the Saldino-Noonan syndrom , Virchows Arch. A. Pathol. Anat. Histopathol. 398(3) : 247- 262.;

Susami, H., Kuroda, T., 1999, EvC syndrome: craniofacial morphology and multidisciplinary treatment, Cleft palate Craniofac. J.: 1999, Jul., 36 (4): 345-352.;

Tabernia, A.C., Stamps., P., et al., 1977: Jeune syndrome (asphyxiating thoracic dystrophy): Clin. Pediatr. 16: 903-908.;

Temtamy, S., Mc Kusick, V.A., 1978, : Majewski syndrom, Births defects, 14, 429-437.;

Thompson, G.S.M., Reynolds, C.P., Cruikshank. J., Antenatal detection of recurrence of Majewski dwarf. Clin. Radiol.1982, 33: 509-517.;

Todd, T.W, 1986, A thoracic expansion technique for Jeunes asphyxiating thoracic dystrophy. J. Pediatr. Surgery 21: 161-163.;

Tsai, Y.C., 1992: Unusual short rib polydactyly syndrome, Am. J. Med. Genet. 44: 31-36.;

Turkel, S.B., 1985: Necropsy finding in neonatal asphyxiating thoracic dystrophy. J. Med. Genet. 22: 112-118.;

Urioste, M., 1994, Short rib polydactyly syndrome and pericentric inversion of chromosome 4. Am. J. Med. Genet., 49: 94-97.;

van Maldergem, L., 1992: Lethal short rib with median cleft and without polydactyly: a fourth case, Pediatr. Radiol. 20: 367-368.;

Verma, I.C., Bhagarva, S., and Agarwal, S., 1975, An autosomal recessive form of lethal chondrodystrophy with severe thoracic narrowing, rhizoacromelic type of micromelia, polydactyly and genital anomalies, Birth Defects Orig. Artic. Ser. 11: 167-174.;

Walley, V.M., Coates , C.F., Gilbert, J.J., Valentine, G.H., and Davies, E.M., 1983, Short rib polydactyly syndrome type Majewski, Am. J. Med. Genet. 14: 445-452.;

Whitley, CB, Schwarzenberg, SJ, 1987: Direct hyperbilirubemia and hepatic fibrosis: a new presentation of Jeune syndrome (asphyxiating thoracic dystrophy); Am. J. Med. Genet. Suppl.; 3: 211-220.;

Wilke, A., Schmoll, J., 1994, Typical complication of short rib polydactyly syndrom, Klin. Pädiatr.112-115.;

Winter, R.M., 1988: A lethal short rib syndrome without polydactyly, J. Med. Genet. 25: 349-350.;

Wladimiroff, J.W., Beemer, F.A., Hemmes, A.M., 1981, Early diagnosis of skeletal dysplasia by real-time, Lancet: 661-662.;

Wu, M.H., Kuo, P.L., Lin, S.J., 1995, Prenatal diagnosis of recurrence of SRPS, Am. J. Med. Genet., 55: (3): 279-284.;

Yang, S.S., Lin, C.S., Al Saadi, A., Nangia, B.S., and Bernstein, J., 1980, Short rib polydactyly syndrom, type 3 with chondrocytic inclusions, Am. J. Med. Genet. 7: 205-213.;

Yang, S.S. , Kitchen, E. , Gilbert, E.F., Rimoin, D.L. , 1986, Histopathologic examination in osteochondrodysplasias. Arch. Pathol. Lab. Med. 110: 1986

Yang, S.S, Roth, A., 1987: Three conditions in neonatal asphyxiating thoracic dysplasia and short rib polydactyly Syndrome spectrum: a clinicopathologic study: Am. J. Med. Genet.Suppl. 1987: 3: 191-207.;

Yang, S.S., Roth, J.A., Langer, L.O., 1991, Short rib polydactyly Beemer-Langer type with polydactyly: a multiple congenital anomalies dysplasia: Am. J. Med. Genet. 39: 243-246.;



Table 8.1.: Comparison of morphological aspects

Group	SRPS 1	SRPS 2	SRPS 3	SRPS 4	Jeune syn.	E.v.Creveld syn.
<b>Number of cases / n</b>	25	45	20	23	36	40
Shaped nose	5	34	17	20	0	20
Hypoplastic maxilla	0	0	0	0	0	40
Occlusion	0	0	0	0	0	30
Prominent abdomen	25	35	15	20	0	0
shortened limbs	25	45	20	23	30	40
short ribs	25	45	20	23	30	0
Asphyxie	25	45	20	23	36	0
Omphalocele	2	0	0	1	0	0
Hypoplastic-lung	25	45	20	23	28	0
Prenatal hypoplasia	10	0	0	20	0	0
narrow chest	25	17	20	23	0	0
polydactyly of hands	25	45	20	10	36	40
polydactyly of feet	8	18	17	5	4	8
dystrophic nails	0	0	0	0	0	40
cleft lip/palate	7	35	8	20	0	0
hepatosplenomegaly	5	19	8	0	4	0
ascites	0	19	0	0	0	0
oedema	0	19	0	0	0	0
renal anomalies	6	40	9	2	7	0
cystic dysplasia	0	40	9	2	7	0
hypoplastic kidney	1	30	10	0	0	0
genital anomalies	0	7	0	0	0	8
cardiovascular anomalies	12	4	0	5	4	24
gastrointestinal anomalies	2	7	13	2	0	0
brain anomalies	3	11	0	1	0	0
genu valgum	0	0	0	0	1	34

Table 8.2.: Comparison of morphological aspects

Group	SRPS 1	SRPS 2	SRPS 3	SRPS 4	Jeune syn.	E.v.Creveld syn.
<b>main features:</b>						
short thorax	yes	yes	yes	yes	yes	yes
polydactyly of hands	yes (postaxial)	yes(pre/post)	yes(postaxial)	sometimes	sometimes	yes
polydactyly of feets	sometimes	often	sometimes	sometimes	rare	sometimes
short limbs	yes	yes	yes	yes	yes	sometimes
<b>occasional features:</b>						
low seat ear	often	often	sometimes	yes	no	no
shaped nose	sometimes	often	yes	yes	no	sometimes
hypoplastic maxilla	no	no	no	no	no	often
occlusion	no	no	no	no	no	often
hydrophic appearance	often	often	yes	sometimes	no	no
cleft lip / palate	sometimes	yes	sometimes	yes	no	no
dystrophic nails	no	no	no	no	no	yes
narrow chest	yes	often	yes	yes	rare	no
hypoplastic lung	yes	yes	yes	yes	often	no
congenital heart disease	often	rare	no	sometimes	rare	often
kidneys anomalies	sometimes	yes	sometimes	rare	dependent of age	no
genitourinary tract anomalies	often	sometimes	no	no	sometimes	no
hepatosplenomegaly	sometimes	often	sometimes	rare	no	no
ascites	no	sometimes	no	no	no	no
gallblader & cystic ductagenesis	yes	no	no	rare		no
fibrosis of pancreas	sometimes	sometimes	often	rare	sometimes	no
esophageal atresia	often	no	no	no	no	no
anal atresia	often	no	no	no	no	no
arrhincephaly	no	sometimes	no	no	no	no

rare=<25%

sometimes = 50%

often = 75%

yes =100%

Table 8.3.: Comparison of radiological aspects

Group	SRPS 1	SRPS 2	SRPS 3	SRPS 4	Jeune syn.	E.v.Creveld syn.
<b>radiological features</b>						
long bones shortening	yes	yes	yes	yes	yes	yes
tibia peculiar aspect	no	yes/ ovoid	no	no	no	no
femura peculiar aspect	yes/pointed distal ends	no	round ed	no	no	no
short horizontal ribs	yes	yes	yes	yes	often	slight
short thoracic cage	yes	yes	yes	yes	yes	yes
small pelvis	yes	sometim es	yes	yes	yes	sometimes
short ilia, flat acetabula	yes	no	yes	sometim es	no	no
spine deficient ossification	yes	no	often	often	no	no
premature epiphyseal ossification	often	sometim es	often	often	no	no
shortened skull base	no	no	yes	no	no	no

## Lebenslauf

Name: Samir Jarrar  
Geburtsdatum: 19. April 1973  
Geburtsort: München  
Familienstatus: Verheiratet, 2 Kinder  
Nationalität: Deutsch  
Adresse: Prälat Wellenhofer-Str. 31, 81377 Munich

### Ausbildung

1983-1993 Luisengymnasium München  
1993 Abitur

### Universitätsausbildung

1995 Student der Medizinischen Fakultät, Ludwig Maximilians  
Universität,  
1998 Physikum  
1999 1. Staatsexamen  
2001 2. Staatsexamen  
2002 3. Staatsexamen

## Acknowledgment

I sincerely thank Prof. Dr. B. Pontz for his continuous support during all aspects of this thesis.

This work is dedicated to my parents

