

**Abteilung und Poliklinik für Sportorthopädie  
der Technischen Universität München**

(Vorstand: Univ.-Prof. Dr. A. Imhoff)

**Arthroscopic Reconstruction of the Coracoclavicular  
Ligaments with Suture Anchors and Small Titanium Plate**  
A Comparative Biomechanical Study

**Bancha Chernchujit**

Vollständiger Abdruck der von der Fakultät für Medizin der Technischen Universität  
München zur Erlangung des akademischen Grades eines

**Doktors der Medizin**

genehmigten Dissertation.

Vorsitzender: Univ.-Prof. Dr. D. Neumeier

Prüfer der Dissertation:

1. Univ.-Prof. Dr. A. Imhoff
2. Priv.Doz. Dr. A. Burkart

Die Dissertation wurde am 20.04.2004 bei der Technischen Universität München  
eingereicht und durch die Fakultät für Medizin am 22.07.2004 angenommen.

## TABLE OF CONTENTS

<b>1 INTRODUCTION.....</b>	<b>5</b>
1.1 Background.....	8
1.2 Anatomy.....	9
1.3 Biomechanics.....	12
1.4 Mechanism of injury.....	13
1.5 Classification .....	14
1.6 Incidence .....	17
<b>2 PURPOSE OF THE STUDY.....</b>	<b>17</b>
<b>3 MATERIALS AND METHODS.....</b>	<b>18</b>
3.1 Specimen preparation.....	18
3.2 Testing procedure.....	19
3.3 Reconstruction technique.....	24
3.3.1 Reconstruction with coracoacromial ligament.....	24
3.3.2 Reconstruction with bone suture anchors.....	27
3.3.3 Reconstruction with synthetic loop.....	39
3.3.4 Reconstruction with Coracoclavicular screw.....	41
3.4 Data and statistical analysis.....	44
<b>4 RESULTS.....</b>	<b>46</b>
4.1 Coracoclavicular ligament complex.....	46
4.2 Coracoclavicular reconstructions.....	46
4.2.1 Standard Coracoclavicular reconstruction.....	46
4.2.2 Suture Anchors reconstruction .....	47
<b>5 DISCUSSION.....</b>	<b>57</b>
5.1 Primary stabilization.....	58
5.2 Dynamic stabilization.....	59
5.3 Secondary stabilization.....	60
5.3.1 Native coracoclavicular ligament complex.....	61

5.3.2	Coracoacromial ligament transfer.....	62
5.3.3	Coracoclavicular screw fixation.....	63
5.3.4	Synthetic loop reconstruction.....	65
5.3.5	Suture anchors with small titanium plate.....	68
<b>6</b>	<b>CLINICAL APPLICATION.....</b>	<b>74</b>
<b>7</b>	<b>CONCLUSION.....</b>	<b>75</b>
<b>8</b>	<b>ABSTRACT.....</b>	<b>76</b>
<b>9</b>	<b>REFERENCES.....</b>	<b>78</b>
<b>10</b>	<b>FIGURE LEGENDS.....</b>	<b>85</b>
<b>11</b>	<b>TABLE LEGENDS.....</b>	<b>88</b>
<b>12</b>	<b>ACKNOWLEDGEMENTS.....</b>	<b>89</b>
<b>13</b>	<b>GRANT SOURCES.....</b>	<b>90</b>
<b>14</b>	<b>CURRICULUM VITAE.....</b>	<b>91</b>

## ABBREVIATIONS

AC	Acromioclavicular joint
CC	Coracoclavicular ligament
CA	Coracoacromial ligament
Corkscrew FT	Corkscrew full threaded
DT	Deltotrapezial fascia
EF	Elongation at failure ( mm.)
FW	Fiberwire
Lig.	Ligament
N	Newton
No.	Number
PDS	Polydioxanonsulphate
ST	Stiffness ( N/mm.)
UTS	Ultimate tensile strength ( N)

# 1 INTRODUCTION

Acromioclavicular dislocations are among the most common injury occurring in the athletic patients. Most commonly, a sprain to the joint occurs with variability in the amount of ligamentous damage and displacement that occurs. Although the understanding and management of this injury have evolved continuously during the last two decades, there is no consensus about the ideal treatment. There is probably no other joint in the human body that has been treated in so many different ways. There are numerous procedures, both historic and contemporary, that can be used to treat the acromioclavicular dislocation. Reviewing the literature there are 32 of conservative treatment and over 100 methods of operative treatment (Urist, 1959). Operative interventions for these injuries attempt to reproduce, either statically or dynamically, the anatomic restraints that stabilize the acromioclavicular joint. As such, the acromioclavicular joint can be operated using one of the five surgical techniques: (1) Acromioclavicular fixation techniques, (2) Coracoclavicular fixation techniques, (3) Ligament substitution using coracoacromial ligament, (4) Excision of the lateral clavicle, and (5) Dynamic muscle transfer. These five methods are not mutually exclusive, however, as they may be combined in a single operative setting to produce a final construct with superior mechanical stability.

Fixation between the acromion and the clavicle was previously quite popular. Because of the numerous reports of migration of these pins into areas of vital organs including the liver, neck, lung, spinal canal, heart, subclavian artery, and aorta, their use has diminished (Mazet et al., 1943; Norell et al., 1965; Sethi et al., 1995). The Hook plate

has been popularized in Europe and used successfully for the acromioclavicular joint reconstruction. Sim et al reported on their experience with the hook plate and found that it successfully reconstructed the acromioclavicular joint but it required a second operation with a high incidence of infection and one episode of plate subluxation ( Sim et al., 1995). Bosworth was the first to described a technique in which a screw is placed through the clavicle and then inserted to the base of coracoid, using percutaneous technique ( Bosworth, 1941). Tsou reported on 53 pateints in 1989 who underwent percutaneous coracoclavicular fixation and found 32% technical failure ( Tsou, 1989). In addition, coracoclavicular screw required removal after the ligament healing to avoid breakage or bony erosion ( Power and Bach, 1974). To eliminate the need of screw removal, some authors have recommended use of synthetic material or graft looped between the coracoid and the clavicle ( Bunnell 1928, Bearden et al., 1973; Albrecht, 1983). Simple coracoclavicular cerclage causes anterior subluxation of the distal clavicle with malreduction of the acromioclavicular joint (Baker et al., 2003; Jerosch et al.,1999; Morrison and Lemos, 1995). To avoid such complication, Morrison and Lemos recommended that the loop should be placed as near the base of coracoid as possible and then inserted through a hole at the junction of the anterior and middle thirds of the clavicle. If the loop in the clavicle was too posterior, it would tend to displace the clavicle anterior to the acromion( Morrison and Lemos, 1995). Distal clavicle resection was first reported by Mumford in 1941 ( Mumford, 1941). Distal clavicle resection was undertaken as a salvage procedure for chronic persistent pain after acromioclavicular dislocation, especially type I or type II injuries, or as treatment of degenerative or osteolytic acromioclavicular joint arthrosis. Dynamic muscle transfer by transferring of

the short head of biceps with or without the coracobrachialis has been described ( Bailey R., 1965; Bailey R., 1972; Brunelli G., 1956; Dewar F and Barrington T., 1965; Glorian B. and Delplace J., 1973) and usually achieved acceptable results. However, the risk of nonunion or injury to the musculocutaneous nerve with transfer of coracoid was substantial ( Caspi et al., 1987). The most recent report on this procedure noted that nearly half of the patients whose shoulder were operated on had continued aching of the joint, particularly those over the age of 40 ( Ferris et al., 1989). Skjeldal et al reported 10 complications in 17 patients, including coracoid fragmentation, infection and pain ( Skjeldal et al., 1988) .

Although these numerous options of surgical methods, there has been no consensus regarding surgical treatment for severely dislocated acromioclavicular joints. To date, most of the current interventions are performed using coracoclavicular reconstruction techniques. Because of its high rate of clinical success, less soft tissue dissection and relative low incidence of complications, coracoclavicular reconstruction has become a more common surgical procedure for the treatment of severe acromioclavicular joint injuries. There are two basic forms of fixation between clavicle and coracoid, rigid and nonrigid constructs. Screws and wires represent a rigid form of fixation, and suture ( either absorbable or nonabsorbable) or grafts characterize a nonrigid form of fixation. The latter can be either looped around the base of coracoid or passed through a transosseous tunnel in the coracoid. More recently, the use of suture anchors has been described for the treatment of acromioclavicular joint dislocation ( Imhoff et al., 2003). These devices offer the potential advantages of technical ease of use and reduced risk of neurovascular injury, as they avoid passage of suture material around the base of

the coracoid. Moreover this can be performed using arthroscopic stabilization technique ( Imhoff et al., 2003). The advantage of an arthroscopic acromioclavicular reconstruction is the less compromise of musculotendinous structures, less morbidity, shorter rehabilitation, and quicker return to activity. In addition, the cosmesis is also excellent. However the deficit remains in the biomechanical properties of this new reconstruction technique comparing with the native coracoclavicular ligament and other standard coracoclavicular reconstruction.

### **1.1 Background**

The acromioclavicular (AC) joint is commonly involved in traumatic injuries that affect the shoulder. In a review of dislocations of the shoulder complex, acromioclavicular dislocations are the second most common injury. It accounts for 12-20% of all injuries about the shoulder ( Cave, 1858; Kocher et al., 1998). However, these injuries are often confused with other problems associated with the shoulder complex. Hippocrates (460-377 BC), was the first to delineate acromioclavicular joint injuries from glenohumeral joint injuries, as well as their mechanism of injury. Galen (129-199 AD) experienced an acromioclavicular dislocation and could not tolerate the tight bandaging recommended at the time and thus became one of the earliest noncompliant patients (Rockwood et al.,1990).

The treatment of AC joint injuries has evolved and changed as our understanding of the nature of the problem and the biomechanics of the joint has developed. In 1917, Cadenat described the ligament transfer, which was later popularized by Weaver and Dunn ( Cadenat, 1917). This remains the most commonly used and successful surgical



treatment we have today for many complete acromioclavicular joint dislocations. Surgical treatment was very common in the 1940s to 1960s for complete dislocations ( Tossy et al., 1963).

After further study, the complete dislocations according to older classification systems were broken down into more detailed groupings depending on the degree of soft tissue injury. Now, treatment addresses the specific pathology involved, and many of the injuries thought to need treatment in the past are successfully treated with conservative measures. Treatment remains controversial in many circumstances, as over the years numerous surgical methods have been described.

## **1.2 Anatomy**

The acromioclavicular joint is a diarthrodial joint located between the lateral end of the clavicle and the medial margin of the acromion process of the scapula. Interposed in the joint is a fibrocartilaginous disk, which helps distribute the forces from the upper extremity to the axial skeleton. Studies performed on cadavers have shown variable morphology in the size and shape of this disk. In 1987, Salter et al reported on 53 acromioclavicular joints in cadavers. A complete disk was observed in only 1 joint, a meniscoid disk was found in 25 joints, only remnants of a disk were found in 16 joints, and the disk was completely absent in 11 joints ( Salter, 1987).

In 1944, Inman et al initially described the rotatory motion at the acromioclavicular joint as 20°. In 1990, Rockwood and Young obtained a more accurate range of 5° to 8° through the use of pins placed in the acromion and clavicle of a living subject. They called this motion "synchronous scapuloclavicular rotation."

The acromioclavicular joint capsule is quite thin, but with heavy ligamentous support ( Nuber and Bowen, 1997). Salter et al provided a detailed anatomic description from cadaveric specimens (Salter et al., 1987). They found that the superior acromioclavicular ligament was more substantial and thicker ( 2.0 mm-5.5 mm) than the inferior acromioclavicular ligament, and had a more defined insertion into the distal clavicle. The superior acromioclavicular ligament was also noted to insert into the clavicle and essentially merge with the musculotendinous aponeurosis of the delto-trapezial fascia. In over half of their specimens, the inferior ligament could not be identified.

The coracoclavicular ligament complex consists of the conoid and trapezoid ligaments ( Fig 1,5 ). The former is posteromedial, and the latter is anterolateral. Salter and colleagues reported that well-defined bursae can exist between these ligaments. They found the trapezoid and conoid ligament to vary significantly in length and width. The trapezoid ligament varied from 0.8 cm to 2.5 cm in length and width. The conoid ligament varied from 0.7cm to 2.5 cm in length and 0.4 cm to 0.95 cm in width ( Salter et al., 1987)

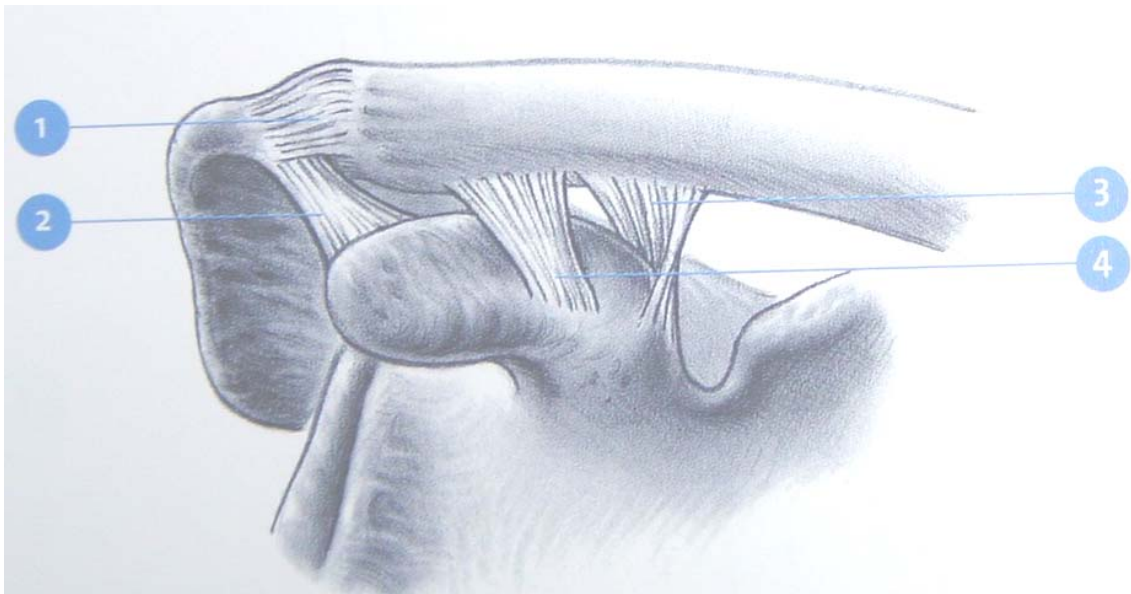


Fig 1. Demonstrating the acromioclavicular joint (1), coracoacromial ligament (2), Conoid ligament (3), and Trapezoid ligament (4)

### 1.3 Biomechanics

The primary functions of the acromioclavicular joint are to transmit force from the appendicular skeleton to the axial skeleton and to suspend the upper extremity. There have been several biomechanical studies involving sequential ligament section in cadaveric specimens that have documented the strength, stiffness, and relative contribution of these supporting structures to joint constraint under displacement ( Branch et al., 1996; Debski et al., 2001; Fukuda et al.,1986; Klimkiewicz et al., 1999). Fukuda et al found the acromioclavicular ligaments are the primary restraints to posterior translation and axial distraction ( Fukuda et al., 1986)

The coracoclavicular ligament is a very strong passive stabilizer with two parts. The laterally located part is trapezoid, the medially located part is conoid. The trapezoid ligament attaches laterally in the anteroposterior plane and thus is the primary restraint to compression (axially) as well as a secondary restraint to superior translation. The conoid ligament is the primary restraint to both superior translation and anterior translation. This function is a result of its inferoposterior to superoanterior course. Both of these ligaments arise from the base of the coracoid process, which is important to consider when performing stabilization procedure ( Table1).

**Table 1. Main primary stabilizers of the AC-joint in relation to the direction of the force**

Direction of force	Conoid ligament	Trapezoid ligament	Acromioclavicular ligament
Anterior translation	x		
Posterior translation			x
Superior translation	x		
Distraction (axial)			x
Compression (axial)		x	

#### **1.4 Mechanism of Injury**

Dislocation of the acromioclavicular joint can occur with indirect trauma but usually results from direct trauma to the shoulder region. The subcutaneous position of this joint, which does not have large amounts of muscle protecting it, theoretically puts it an increased risk of injury (Fig.3). The classic history for an injury to the acromioclavicular joint is a direct force applied to the acromion with the arm in an adducted position. The acromion is driven medially and downward and an abrasion or laceration of the overlying skin is not uncommon. The clavicle rests against the first rib, and the rib blocks further downward displacement of the clavicle. As a result, if the clavicle is not fractured, the acromioclavicular and coracoclavicular ligaments are ruptured. In addition, contraction of the trapezius muscle provides a second mechanism by which inferior clavicular displacement is resisted. The force initially injures the acromioclavicular ligaments. When the force continues, further trauma and energy are absorbed by the coracoclavicular ligaments, resulting in greater displacement of the clavicle relative to the acromion. A more severe injury may occur with larger forces and disruption of the deltotrapezial fascia, in addition to the ligamentous injuries.

Indirect injury can result from a fall onto an adducted outstretched hand or elbow, which causes the humerus to translocate superiorly, driving the humeral head into the acromion and causing damage.

## 1.5 Classification

The pathoanatomy of acromioclavicular dislocation was first described by Cadenat in 1917 (Cadenat, 1917). Tossy et al and Allman later classified the injury into three types, based on the extent of injury to the acromioclavicular and coracoclavicular ligaments( Tossy et al., 1963; Allman, 1967). Rockwood et al expanded this classification in 1984 to six types of acromioclavicular injury. (Fig 2.)

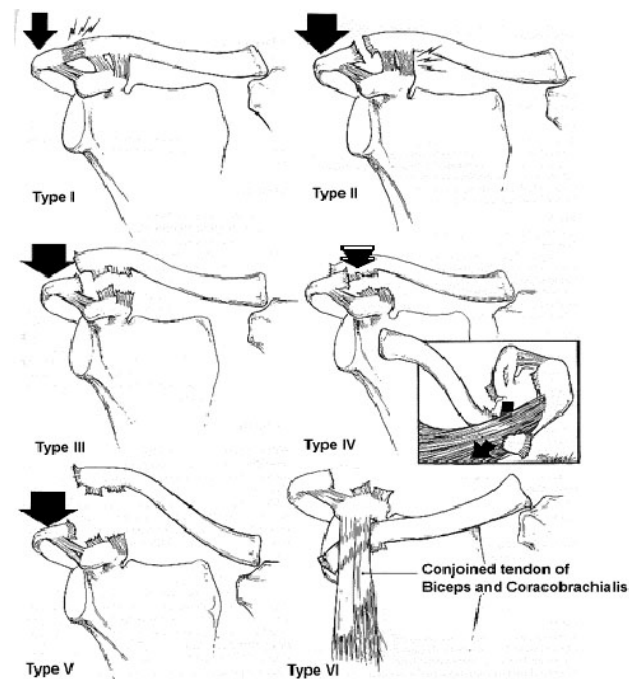


Fig 2. Rockwood Classification of acromioclavicular joint injury.

Type I injuries result from minor strains of the acromioclavicular ligament and capsule. The acromioclavicular joint is stable, and pain is minimal. Although roentgenograms initially may be negative, periosteal calcification at the distal end of the clavicle may be apparent later. Type II injuries are caused by more significant forces, and the coracoclavicular ligaments remain intact. In this instance the acromioclavicular joint

is unstable. This instability, especially in the anteroposterior plane, causes deformity, and on the roentgenograms the lateral end of the clavicle may ride higher than the acromion, usually by less than the thickness of the clavicle even when stress is applied to the joint. Considerable pain and tenderness are present over the acromioclavicular joint, but stress roentgenograms are necessary to assess the degree of instability following these injuries. Injuries that results from a force sufficient to rupture both the acromioclavicular and coracoclavicular ligaments have been known as grade III injuries. Rockwood further classified these injuries into type III, IV, V, VI. Type III injuries consists of disruption of the acromioclavicular and coracoclavicular ligaments and the distal clavicular attachment of the deltoid muscle. The distal clavicle is above the acromion by at least the thickness of the clavicle. Traditionally this elevation of the clavicle has been attributed to the pull of the trapezius muscle; however, Rockwood believes the scapula, including the glenohumeral joint, is depressed, rather than the clavicle being elevated, creating the gap between the clavicle and the acromion. In type IV injuries, the same structures are disrupted as in grade III injuries. The distal clavicle is displaced posteriorly into or through the trapezius muscle. In type V injuries the distal attachments of the deltoid and trapezius to the clavicle are both detached from the distal half of the clavicle. The acromioclavicular joint is displaced from 100% to 300%, and a gross separation between the clavicle and the acromion is present. Type VI injuries are rare and are caused by extreme abduction that tears the acromioclavicular and coracoclavicular ligaments ( Gerber and Rockwood, 1987). The distal clavicle is displaced under the coracoid and behind the conjoined tendons. In this type, transient paresthesias are present in most patients before reduction and subside afterward.

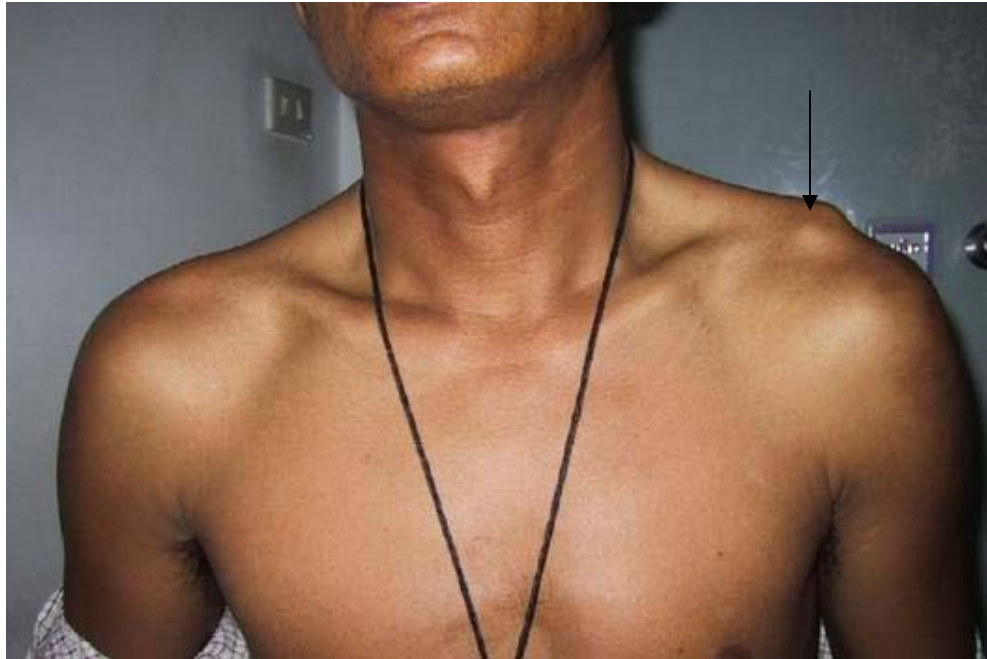

Fig 3. Showing the dislocated acromioclavicular on the left shoulder. The arrow shows tenting of the skin at the distal clavicle



## **1.6 Incidence**

In a review of dislocations of the shoulder complex, Cave 1958 evaluated 394 cases. Dislocations were glenohumeral in 85% of injuries (335), acromioclavicular in 12% of injuries (47), and sternoclavicular in 3% of injuries (12). In 1961 Rowe et al retrospectively reviewed the medical records of the Massachusetts General Hospital and found 52 AC joint injuries among 1,603 shoulder-girdle injuries. Most occurred in the second decade of life. Thorndike et al., 1942 reported AC joint involvement in 223 of 578 athletes with shoulder injuries. AC injuries are among the most common injuries affecting hockey and rugby players ( Daly et al., 1990; Diaz et al., 1991). The injury is approximately five times more common in men than in women. Type I and II injuries occur twice as frequently as the more severe, complete dislocations, types III, IV, V, and VI.

## **2 PURPOSE OF THE STUDY**

Although the controversy about the optimal treatment of acromioclavicular joint separation, whether surgical or not, there is even more controversy over the proper technique once operative treatment has been deemed necessary. Despite numerous techniques have been described to address these injuries, there is little information in the literature regarding the biomechanical properties of augmentations.

The purpose of this study was to test, in human cadaveric models, the biomechanical properties of a new reconstruction technique that uses various suture anchors and small titanium plate. These properties were compared with those of the normal intact coracoclavicular ligaments as well as traditional techniques such as the

coracoacromial ligament transfer techniques, synthetic suture loop, coracoclavicular screw. The ultimate goal of this study was to develop a better operative solution to this common injury, one that is less invasive, might have sufficient initial and ultimate strength to allow early motion, accelerated rehabilitation, earlier return to sports, and lower failure rates.

### **3 MATERIALS AND METHODS**

#### **3.1 Specimen Preparation**

Coracoclavicular bone-ligament-bone specimens ( Fig 5.) were harvested from 20 fresh-frozen human cadavers, 12 right and 8 left unpaired shoulders were obtained from donors with a mean age of 55 years (range, 28 to 76). All specimens were free from disease or injury to the acromioclavicular joint.

Shoulder specimens were stored at  $-20^{\circ}\text{C}$  and allowed to thaw at room temperature for 24 hours before use. The skin, subcutaneous tissues, and muscles were removed, and the acromioclavicular ligaments and capsule were divided, leaving the coracoacromial ligament and coracoclavicular ligament complex intact. The sternoclavicular joint and the glenohumeral joint were disarticulated.

Immediately after dissection, the body of the scapula was embedded in an open-top steel box, allowing the upper part of the spine, glenoid, and coracoid to protrude (Fig. 6). Care was taken to embed each specimen in the correct anatomic position, with the long axis of the clavicle and the scapular plane oriented at approximately  $90^{\circ}$  to one

another. During preparation and testing, specimens were kept appropriately hydrated with physiologic saline at room temperature. For the overnight interval between instrument insertion and testing, the specimens were stored refrigerated in sealed plastic bags to decrease moisture loss.

### **3.2 Testing Procedure**

Custom-made fixtures were designed for fixation of the scapula and clavicle to the electro-mechanical testing machine ( Zwick-Roell, Ulm, Germany) (Fig.4). The scapula bodies were potted in metal blocks using Epoxy resin ( Ureol FC 52 Polyol, Muenchen, Germany) while the clavicle was secured to the testing machine with nuts and bolts through two drill holes into the clavicle that were connected with a plate ( Fig.6). The Zwick clamp was secured onto the middle of the plate. This setup provided rigid fixation of the clavicle and scapula to the Zwick testing machine and allowed the coracoclavicular ligaments and augmentations to be oriented parallel and in line with the pull of the Zwick testing machine. Initial use of trial constructs and slow-motion video analysis ensured that no slippage occurred between the clavicle –fixture or scapula-fixture interfaces.

Each of the 20 shoulder specimens underwent application of unidirectional load to failure. The software controller was programmed to produce a displacement rate of 25 mm/min. The ultimate tensile strength, stiffness, elongation at failure were digitally collected by the software. The testes were performed respectively as the followings

1. Reconstruction with coracoacromial ligament (n= 10)
2. Reconstruction with bone anchor suture system

- 2.1 Reconstruction with 2.8-mm Fastak with fiberwire # 2 and a small titanium plate (n=10 )
- 2.2 Reconstruction with 2.8-mm Fastak with fiberwire # 5 and a small titanium plate (n=10)
- 2.3 Reconstruction with 3.5-mm Fastak with fiberwire # 5 and a small titanium plate (n=10)
- 2.4 Reconstruction with 5.5-mm Corkscrew Full threaded ( Corkscrew FT) with fiberwire # 2 and small titanium plate (n=10)
- 2.5 Reconstruction with 5.0-mm Corkscrew with fiberwire # 5 and a small titanium plate (n=6)
- 3. Reconstruction with synthetic loop
  - 3.1 Reconstruction with 5-mm PDS (Polydioxononsulphate) tape (n= 10)
  - 3.2 Reconstruction with 5-mm Mersilene tape (n=10)
- 4. Reconstruction with Bosworth screw
  - 4.1 Unicortical Bosworth screw (n =10 )
  - 4.2 Bicortical Bosworth screw (n=10)




Fig 4. The Zwick testing machine. The data were acquired by using the Zwick software and compiled using a desktop computer.

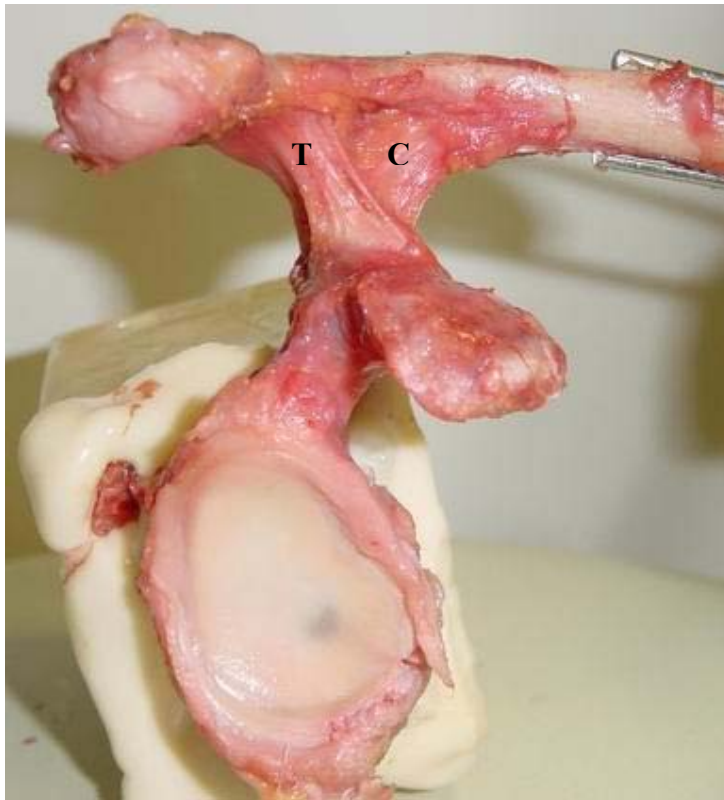

Fig 5. Demonstrating the coracoclavicular ligament complex. (T= Trapezoid, C=Conoid)




Fig 6. The body of scapula was embedded in an open-top steel box with Epoxy resin, allowing the upper part of the spine, glenoid and coracoid to protude. The clavicle was secured to the testing machine (Zwick) with nut and bolts through 2 drill holes into the clavicle that were connected with a plate

### **3.3 Reconstruction technique**

#### ***3.3.1 Reconstruction with Coracoacromial ligament***

In 1972, the Coracoacromial ligament transfer was first described by Weaver and Dunn. Approximately 1-cm of the distal clavicle was excised with an oscillating saw first. The medullary bone was removed from the remaining end of the clavicle. The 2.0-mm drill bit was used to create two holes on the superior surface of the lateral clavicle, directly over the coracoid process. These holes should be placed in the anterior one third of the clavicle. Care was taken to preserve and isolate the entire coracoacromial ligament (Fig.7). Then the coracoacromial ligament was released from its insertion under the acromion and mobilized into intramedullary canal of the clavicle with a Meniscus needle. The ligament was prepared for the transfer by weaving with fiberwire#2 in a modified Bunnell configuration. Both ends of the suture were passed into the distal clavicle from the medullary canal and were tied over the superior cortex of the clavicle through two 2-mm drill holes. (Fig.8).



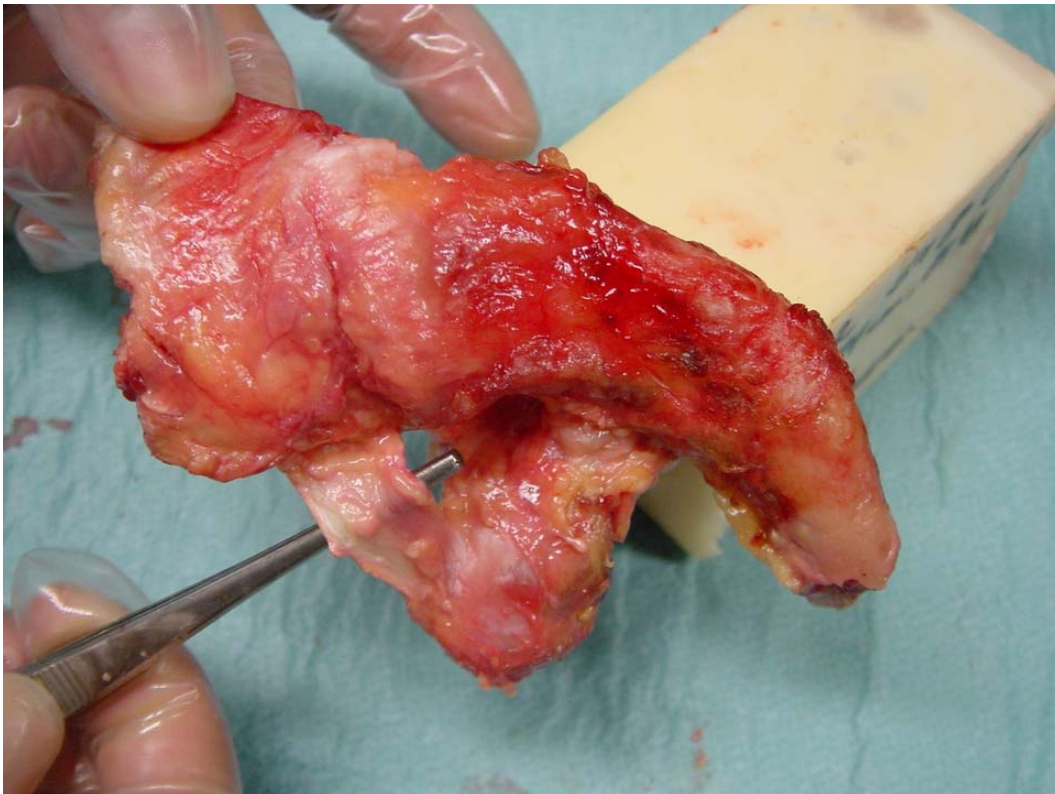


Fig 7. Depiction of coracoacromial ligament

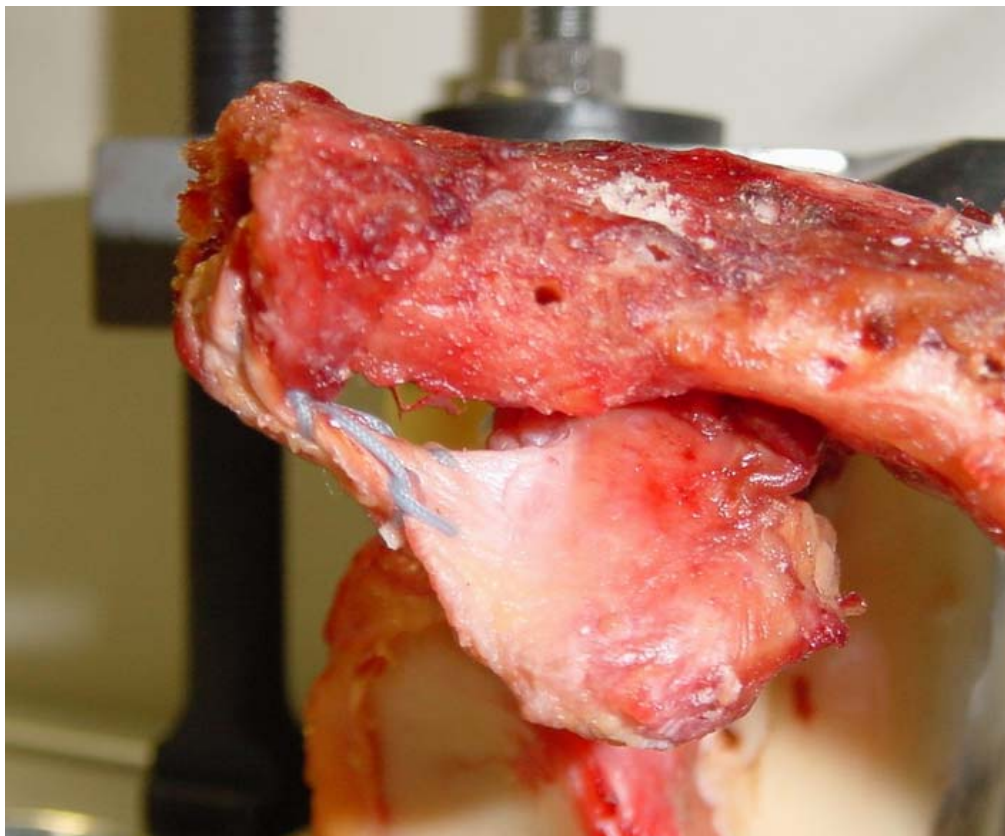


Fig 8. Demonstrating the Weaver-Dunn procedure. The distal clavicle was excised and the coracoacromial ligament was transferred into the medullary canal of the clavicle.

### ***3.3.2 Reconstruction with bone suture anchors with titanium plate***

In 2003, Imhoff et al proposed a new arthroscopic technique to reconstruct the high grade acromioclavicular dislocation using bone suture anchor system and small titanium plate ( Imhoff et al., 2003). This technique was performed under arthroscopic approach. However, in this experimental study, we could not performed the biomechanical testing of the constructs under arthroscopic technique so we performed and tested all the reconstructions by open technique ( Fig. 10-17).

After finish the biomechanical testing of the coracoacromial ligament transfer, we removed the remnant of the torn coracoacromial ligament and performed the biomechanical testing of suture anchors with titanium plate in the same cadaver. Special delivery system ( Imhoff delivery device, Arthrex, Inc, Naples, FL) was placed onto the superior surface of the base of the corocoid and followed by two bone anchors . The 2.0-mm drill bit was used to create 2 tunnels through the anterior half of the clavicle. A meniscus needle was passed through this tunnel from superior and a 2/0 thread was then inserted through the loop of meniscus needle. Then the needle was withdrawn upward just anterior to the distal clavicle leaving the free ends to retrieve the fiberwires through the tunnel in distal clavicle(. The same procedures were then repeated again in the second tunnel. The four free ends of the sutures were passed through the holes of the titanium plate. The slip-knot was performed and tightened over the titanium plate (Fig.13-19). We performed the reconstructions in the same way in every suture anchor, using 2 suture anchors and two fiberwires in every test except for the corkscrew FT, we used 1 Corkscrew and 2 loops of fiberwire #2.0



Fig 9. View from the top of the Imhoff delivery device and small titanium plates




Fig 10. The suture anchors tested include ( from left to right) the 5.5-mm Corkscrew FT, 5.0-mm Corkscrew, 3.5-mm Corkscrew, 2.8-mm Fastak



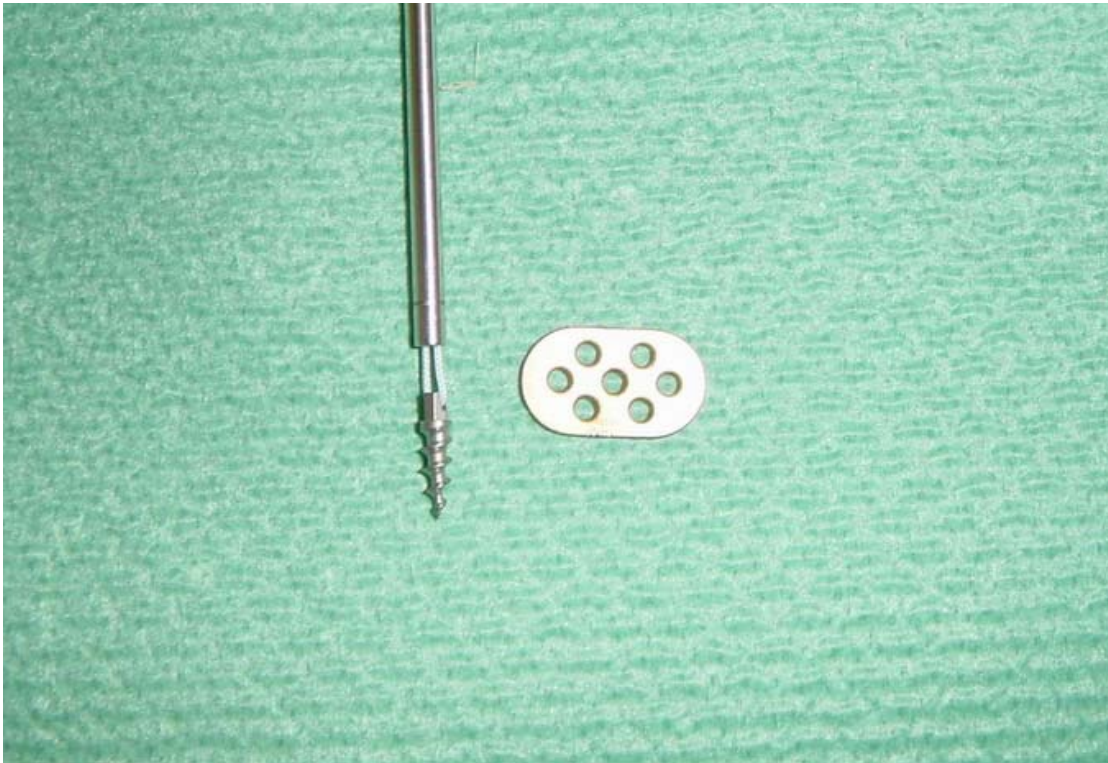


Fig 11. The 2.8-mm Fastak with fiberwire and a small titanium plate

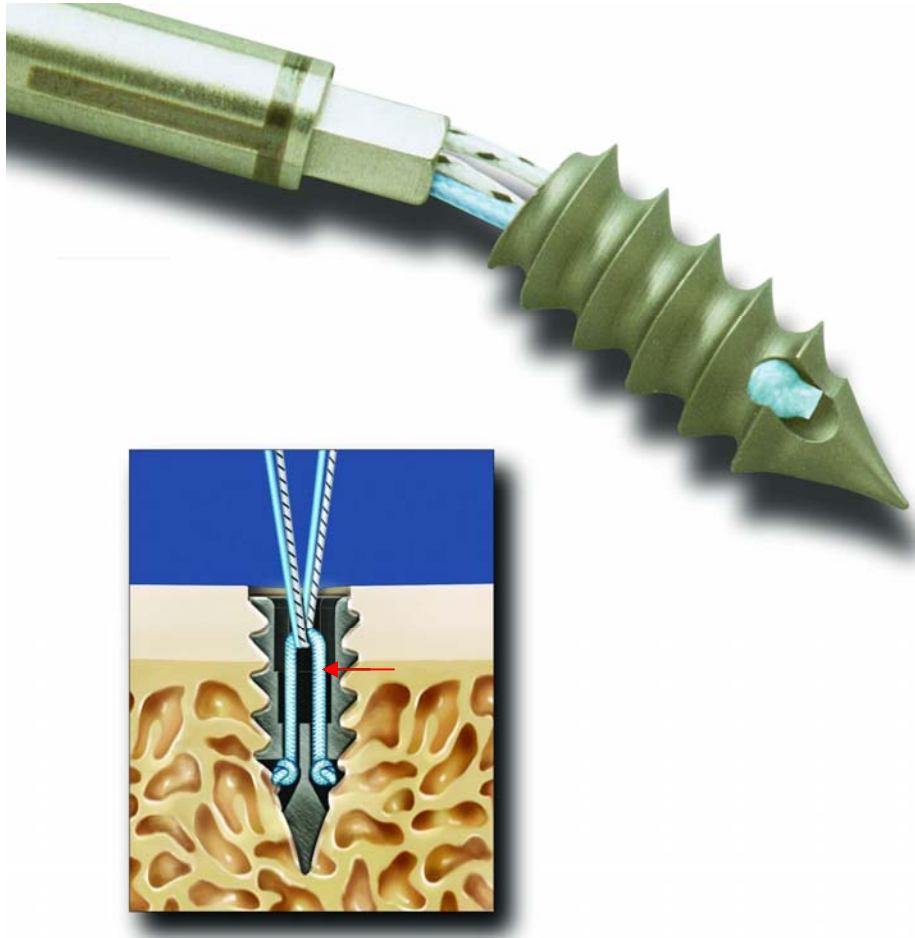


Fig 12. The 5.5-mm Corkscrew FT with fiberwires#2. The arrow demonstrates the fiberwire#2 loop in the screw



Fig 13. The 2.8-mm Fastak is placed into the superior surface of the base of the corocoid



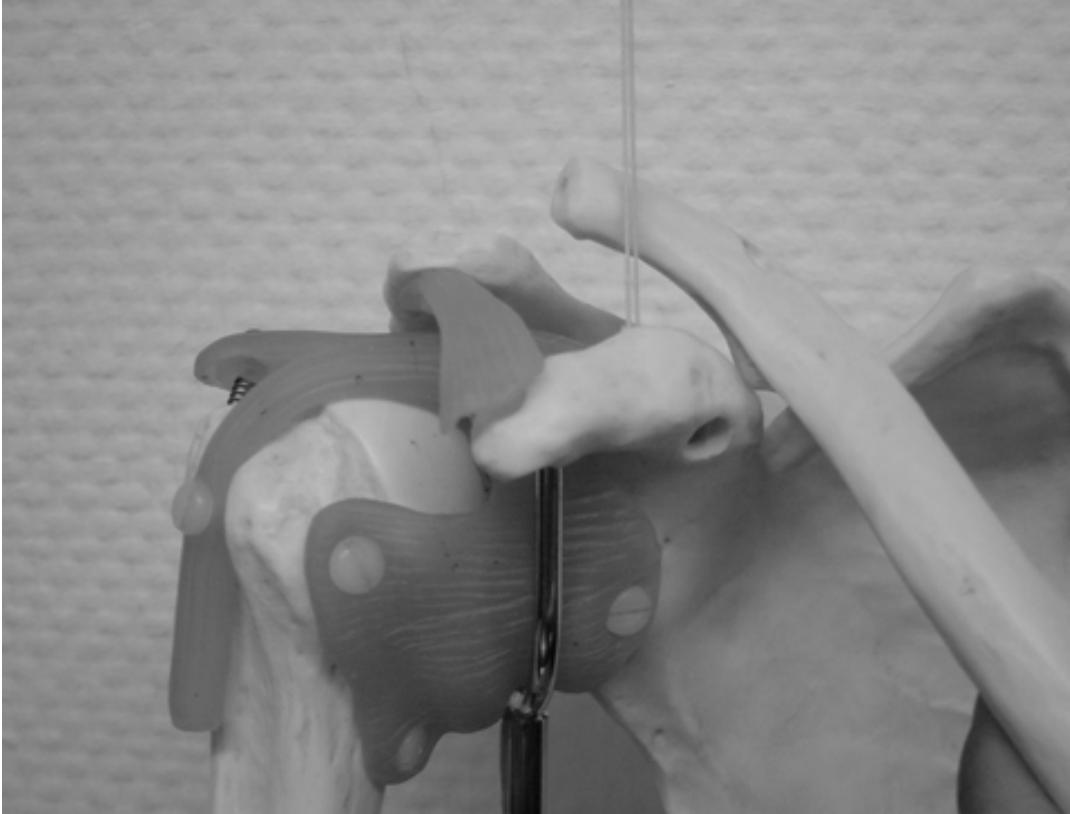

Fig 14. The strand of each suture is passed out just anterior to the distal clavicle

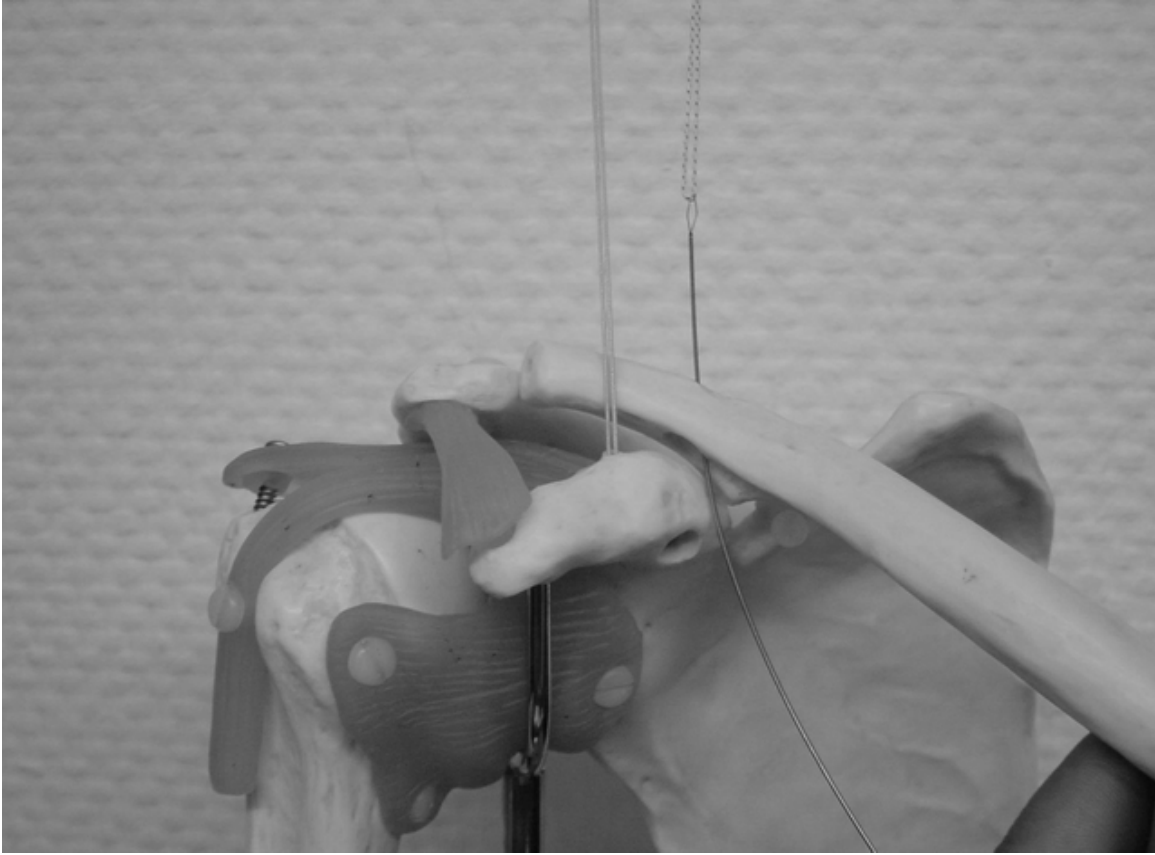


Fig 15. The meniscus needle with a 2/0 thread is passed through the tunnel from superior.

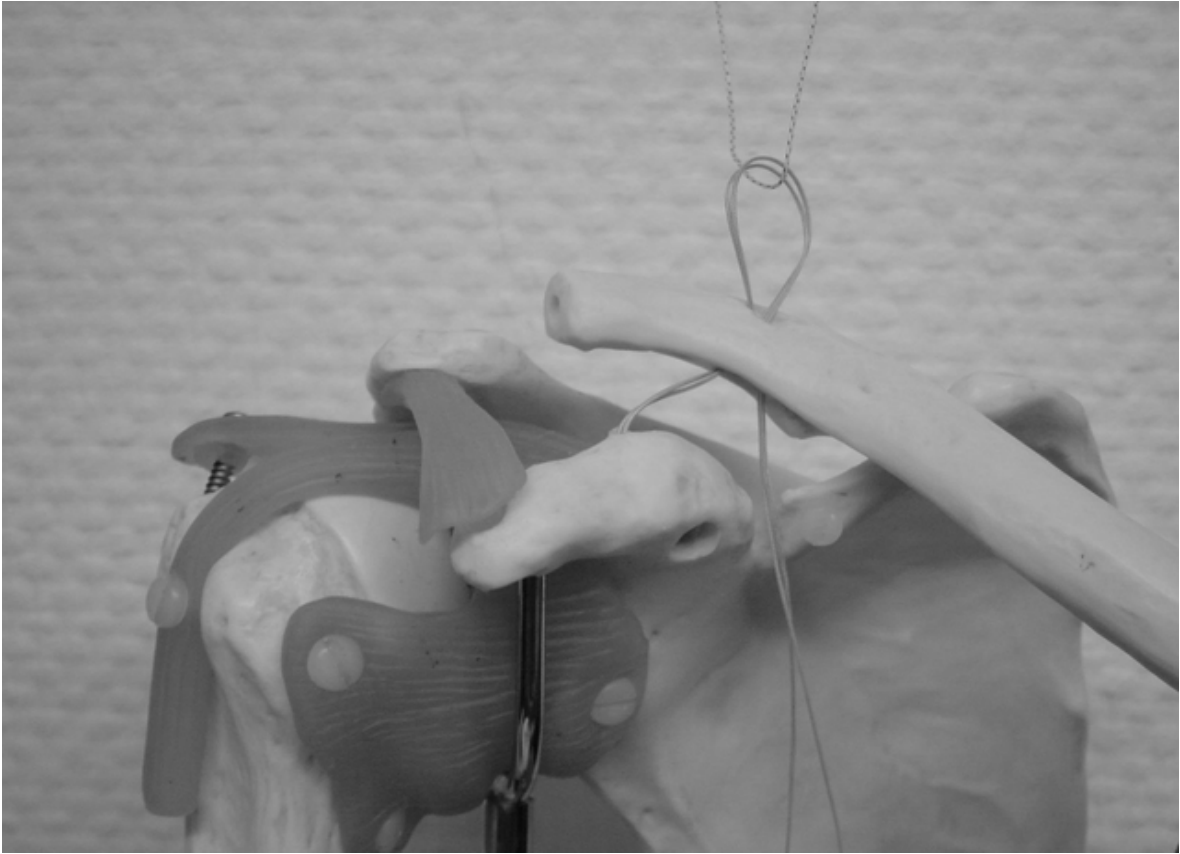


Fig 16. The free ends of the fiberwires are retrieved through the tunnel in distal clavicle

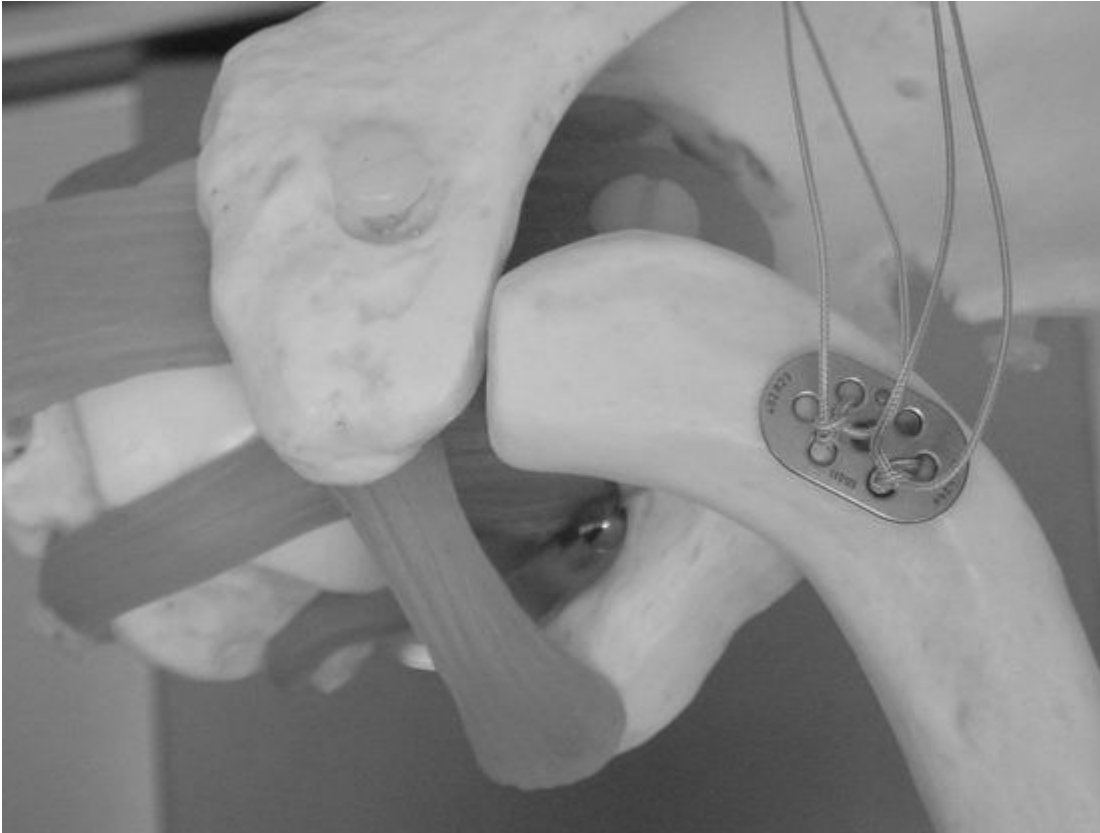


Fig 17. The four free ends of the Fiberwires No.2 are passed through the holes of the titanium plate and the slip-knot are performed and tightened over the titanium

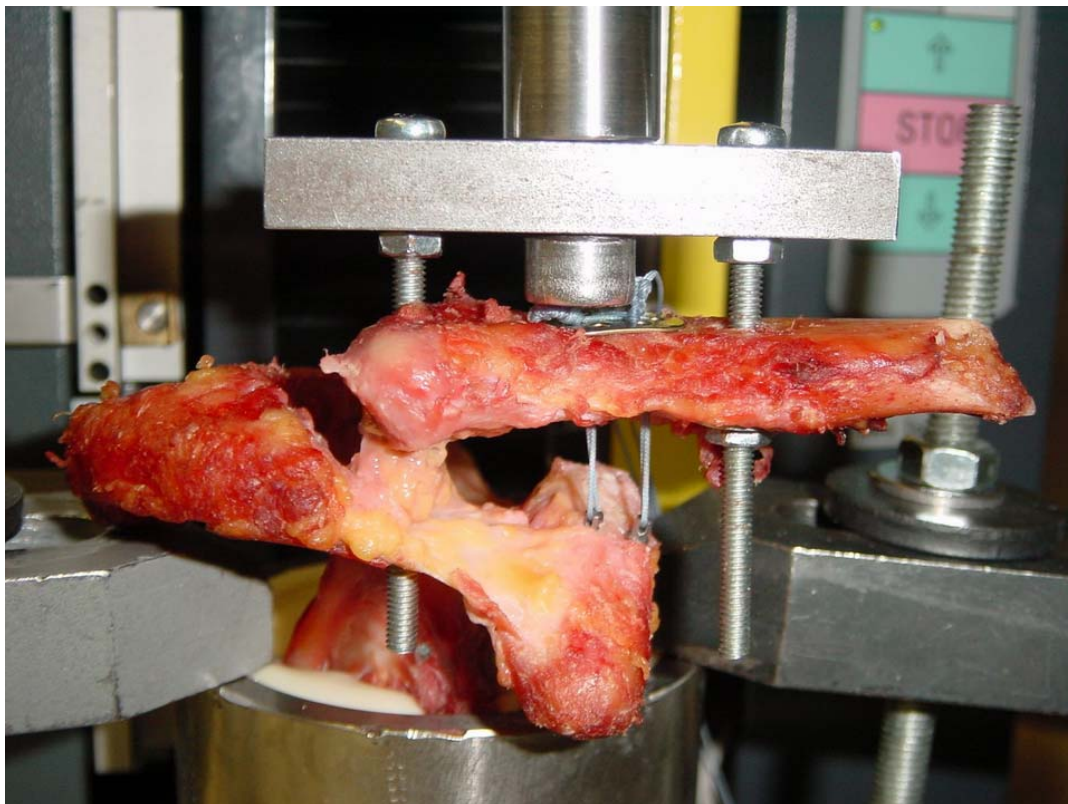


Fig 18. Setup of the specimen in the mechanical testing machine. Construct with 2.8-mm Fastak with fiberwire#2 and small titanium plate loaded on testing apparatus.




Fig 19. Technique for reconstruction with Corkscrew FT with 2 loops of fiberwire#2

### ***3.3.3 Reconstruction with Synthetic loop***

The synthetic tape ( 5-mm PDS band or 5-mm Mersilene tape) was passed under the base of coracoid, then drill holes was placed in the clavicle for passage of the coracoclavicular sutures. With the joint reduced, the entry points for the drill holes were identified. The drill holes should be bicortical and placed at the junction of the anterior one-third and posterior two-thirds of the clavicle in the anterior-posterior direction. In the medial-lateral direction, the drill holes should be oriented so that the sutures exiting the lateral side of the coracoid line up with the lateral hole and the medially exiting sutures line up with the medial hole. A suture passer was then used to pass the lateral and medial limbs of the subcoracoid sutures through the lateral and medial clavicular drill holes, respectively. Alternatively, the lateral or medial sutures could be passed up through their corresponding clavicular drill hole and then back inferiorly through the opposite drill hole so that the free ends of the sutures were between the clavicle and coracoid. This would result in the knot lying in the coracoclavicular interspace rather than on the superficial surface of the clavicle when the sutures were tied. ( Fig. 20)

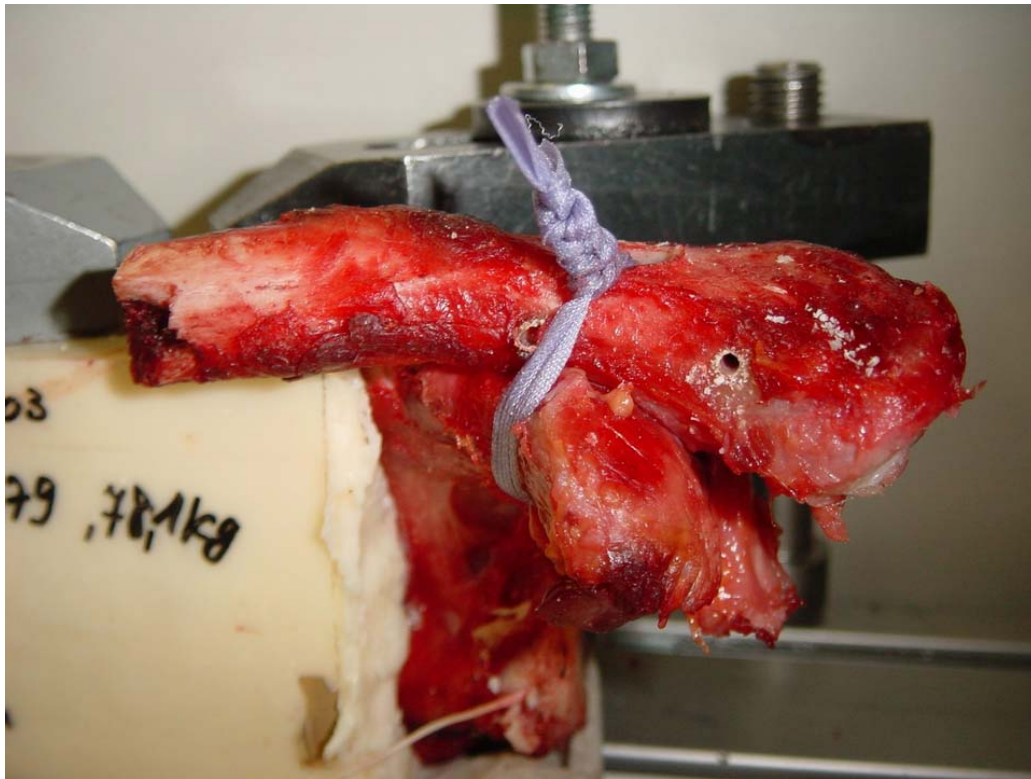


Fig 20. Five-mm PDS tape is looped under the coracoid and through a drill hole in the clavicle, then tied on the medial side.



### ***3.3.4 Reconstruction with Coracoclavicular screw***

In 1941, Bosworth proposed a fixation technique between the clavicle and coracoid by using a coracoclavicular screw without reconstruction of the coracoclavicular ligament. The screw was placed percutaneously using local anesthesia and fluoroscopic technique. After removal of the anchors and the synthetic loop, 4.8-mm drill was placed on the superior surface of the clavicle so that a hole drilled through the clavicle will be aligned with the base of coracoid when the clavicle was reduced. Then passed a second 3.6-mm diameter drill point through the previous hole of the clavicle and drill a hole in the coracoid. We drilled 1 cortex in Unicortical screw reconstruction testing and 2 cortices in Bicortical screw reconstruction testing. Then we selected a 6.5-mm cancellous screw ( Fig. 21 )of appropriate length with a washer and inserted it through the clavicle hole. A washer was used to prevent penetration of the clavicle by the screw head. Tightened the screw until the inferior surface of the clavicle was level with the inferior surface of the acromion (Fig.22).

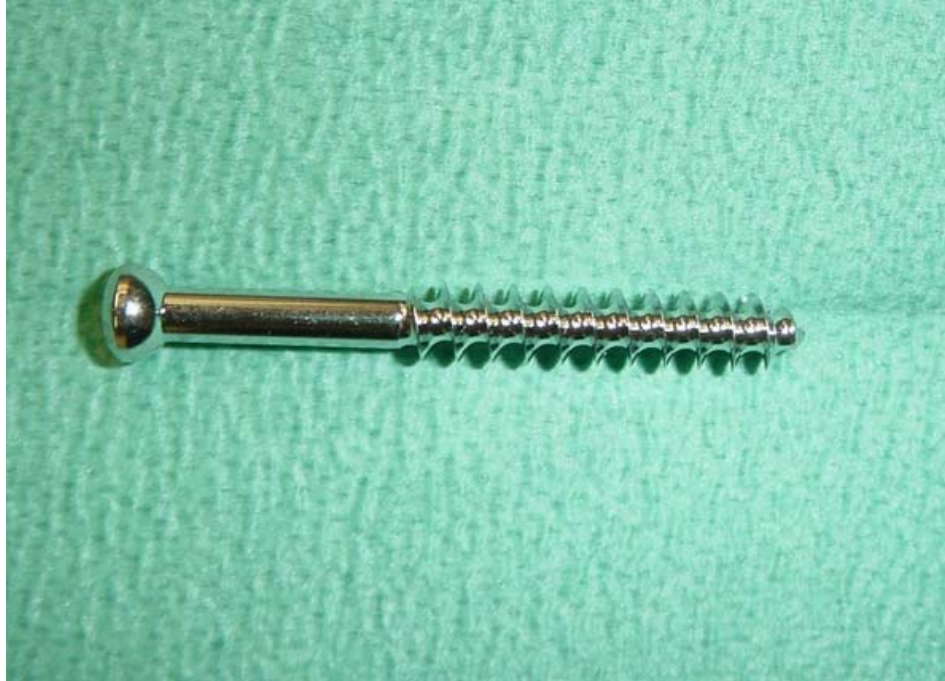

Fig 21. The 6.5-mm cancellous screw

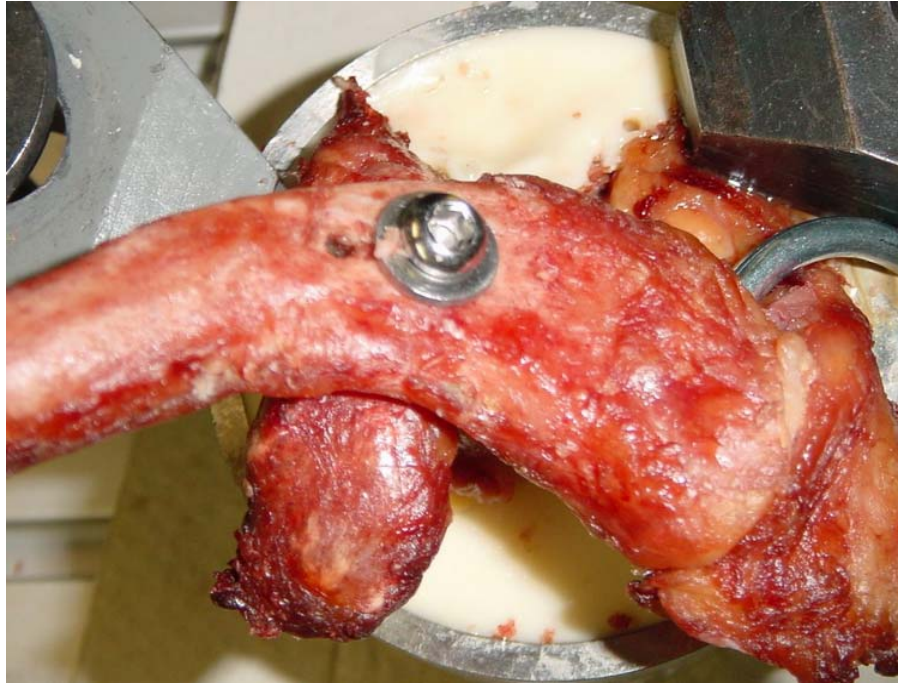


Fig 22. Modified Bosworth technique for reduction and fixation of acromioclavicular dislocation. Construct with a screw and washer placed through the clavicle and into the base of coracoid.

### **3.4 Data and Statistical analysis**

Data were recorded with a dedicate software ( Textexpert 8.1, Zwick-Roell, Ulm, Germany) and compiled using a desktop computer and Excel software ( Microsoft Corp., Redmond, Washington). Stiffness was calculated from the slope of the linear portion of the load-displacement curve. Modes of failure were analysed by the computer sensor and direct observation.

Load-displacement values were analysed for each test to determine structural properties, that is, peak load ( in newtons), stiffness (in newtons per millimeter), and elongation at peak load ( in millimeters) (Fig.23). The statistical analysis was performed on a PC computer, using a SPSS software (version 11.0.1, SPSS Inc.,Chicago, Illinois, USA.). One-way analysis of variance was performed with the different constructs as the factors. Where there was an overall significant difference, which construct was different was determined by Fisher's least significant difference ( LSD ) method for the post hoc multiple comparisons for means. Statistical significance was attained when  $P$  was less than 0.05

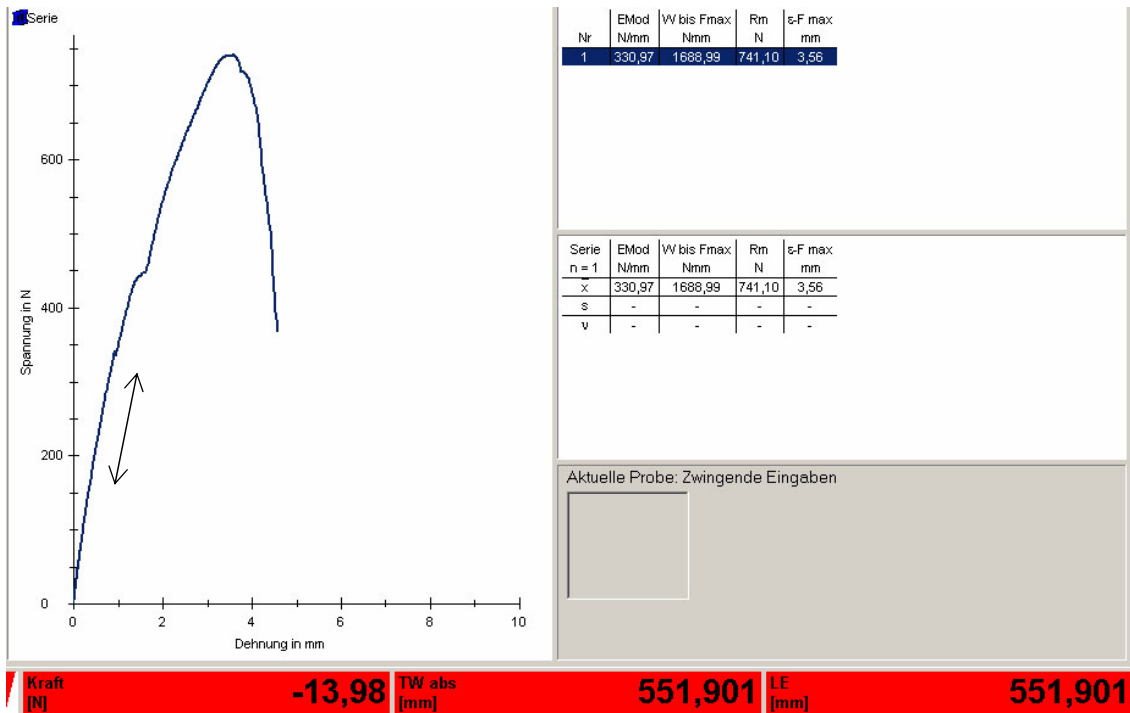


Fig 23. Load-displacement curve for the coracoclavicular ligament. The arrow indicate the portion of the curve that was used to calculate stiffness

## 4 RESULTS

There are a total of 116 Tests run, with 20 in coracoclavicular ligament complex and 10 in each reconstruction technique ( except for 5.0-mm Corkscrew with fiberwire#5 , 6 tests were performed) . The mode of failure, Ultimate tensile strength, stiffness, elongation at failure were observed and reported.

### 4.1 Coracoclavicular ligament complex

Intact coracoclavicular ligament complexes failed mainly by midsubstance rupture (16 of 20) or coracoid insertional failure ( 4 of 20). Clavicular insertional failure was not seen.

Ultimate tensile strength, tensile stiffness and elongation at failure are presented in table 3. The values shown are the means. The load to failure values (mean $\pm$ SD) for the intact coracoclavicular ligament was 578 $\pm$ 112 N, with maximum of 815 N and minimum of 433 N. Tensile stiffness was 77 $\pm$ 36 N/mm, range from 49.2 to 120.9 N/mm, and elongation at failure was 12 $\pm$ 2.5 mm, ranged from 8.3 to 16.9 mm.

### 4.2 Coracoclavicular Reconstructions

#### 4.2.1 Standard Coracoclavicular Reconstruction

Failure mechanism for the reconstructed specimens were limited to damage to the implant material or to a bone component of the shoulder girdle. Coracoacromial ligament transfer failed either by suture rupture at the point of exit from the clavicular medullary canal (1 of 10) or, more commonly, suture pull out from the coracoacromial ligament ( 9 of 10). All unicortical coracoclavicular screws pulled out of the coracoid, while bicortical coracoclavicular failed in one of three modes: Screw pullout ( 7 of 10),

Coracoid fracture ( 2 of 10), Clavicular fracture ( 1 of 10 ). All Coracoclavicular slings failed by suture rupture, irrespective of PDS or Mersilene placement.

#### **4.2.2 Suture Anchors Reconstruction**

##### ***Sutures***

The maximum load at failure was  $256.9 \pm 42.0$  N ( Mean and Standard deviation) for Fiberwire#2 and  $463.4 \pm 84.3$  N for Fiberwire#5 suture. Elongation at failure was  $7.6 \pm 2.2$  mm for Fiberwire#2 and  $10.6 \pm 3.9$  mm for Fiberwire#5; and stiffness was  $29.6 \pm 10$  N/mm for Fiberwire#2 and  $35.2 \pm 13.9$  N/mm for Fiberwire#5.

##### ***Suture-Anchor with titanium plate Constructs***

The mode of failure for the suture anchors with titanium plate constructs varied and occurred in one of three modes: anchor pullout, in which the intact anchor including suture came out of the coracoid; suture breakage, in which the suture failed at the point at which it was connected to the anchor; and eyelet breakage, meaning that the suture pulled out intact after cutting through the eyelet of the anchor. The mode of failure of the 5 anchor reconstruction tests is shown in Table 2. The pull out strength, stiffness and elongation at failure of the anchor reconstruction were shown in Table 3 and Fig. 25-27

**Table 2. Mode of Failure for Suture Anchors**

Anchor	Anchor pullout	Eyelet breakage	Suture breakage	Number
Fastak+FW#2	10%	-	90%	10
Fastak+FW#5	70%	10%	20%	10
3.5-mm Corkscrew+FW#5	60%	-	40%	10
5.0-mm Corkscrew+FW#5	16.6%	-	83.3%	6
CorkscrewFT+FW#2	-	100%*	-	10

\* *Fiberwire # 2 loop in the screw rupture*

Most of these anchors failed either by anchor pullout or suture breakage. The exception was the 5.5-mm Corkscrew FT. This anchor obtained strong purchase to the bone, and was so strong that fiberwire loop in the screw breakage was the predominant mode of failure. The different anchors displayed some variations in the mode of failure, depending on the type of the anchor and the size of the fiberwire.



*Modification 1 ( 2.8-mm Fastak, Fiberwire#2).* Of the 2.8-mm Fastak with fiberwire # 2, 1 failed at the anchor pullout and 9 failed at the suture breakage with no deformation of the screws. The mean ultimate tensile strength for this suture anchor was 393 N with a maximum of 465 N and minimum of 327 N.

*Modification 2 (2.8-mm Fastak, Fiberwire#5).* Testing of the 2.8-mm Fastak with fiberwire #5, 7 failed at the anchor pullout, 2 failed at the suture breakage and 1 failed at the eyelet breakage. The mean ultimate tensile strength for this suture anchor was 412 N with maximum of 531.2 N and minimum of 316.2 N

*Modification 3 ( 3.5-mm Corkscrew, Fiberwire#5).* Using the larger anchors (3.5-mm Corkscrew) in the combination with the fiberwire#5 increased the ultimate tensile strength because of the better fixation strength of the 3.5mm anchors in the coracoid. For the 3.5-mm corkscrew/fiberwire #5 combination, most failures occurred at the anchor pullout (60%) but at higher loads, 40% failed at the suture breakage. The mean ultimate tensile strength for this suture anchor was 502 N with maximum of 573.7 N and minimum of 457.3 N

*Modification 4 ( 5.0-mm Corkscrew, Fiberwire#5).* The highest ultimate tensile load among the suture anchors testing was seen for the 5.0-mm corkscrew with fiberwire #5 combination. The mean ultimate tensile strength for this suture anchor was 767 N with maximum of 863.0 N and minimum of 621.7 N. Suture breakage was the predominant failure mode( 83% ), 17% failed at the anchor pullout.

*Modification 5 ( 5.5-mm CorkscrewFT, Fiberwire#2).* The Corscrew FT has a novel loop of No.2 fiberwire suture that serves as the eyelet for the anchor. Testing of the

5.5-mm corkscrew with fiberwire #2, 100% failed at the fiberwire eyelet ( Loop in the screw rupture). The mean ultimate tensile strength for this suture anchor was 219.6 N with maximum of 257.54 N and minimum of 166.7 N

The ultimate tensile strength, stiffness, and elongation at failure were presented in load vs displacement curves. The shape of the load vs. displacement curves complexes are typical, including an initial nonlinear low-stiffness toe region, followed by a linear region with greater stiffness ( Fig. 24). The stiffness of the 2.8-mm Fastak Fiberwire#2, 2.8-mm Fastak Fiberwire#5, 3.5-mm Corkscrew Fiberwire#5, 5.0-mm Corkscrew Fiberwire#5, 5.5-mm Corkscrew Fiberwire#2 were 54.4, 58.7, 81.2, 86.1, 39.9 N/mm., respectively. The elongation at failure ranged from 4.34 to 24.9 mm across the groups. Mean failure load , stiffness, elongation at failure and mode of failure of the different augmentations and intact coracoclavicular ligament complex are summarized in Table 3. and Fig. 25-27

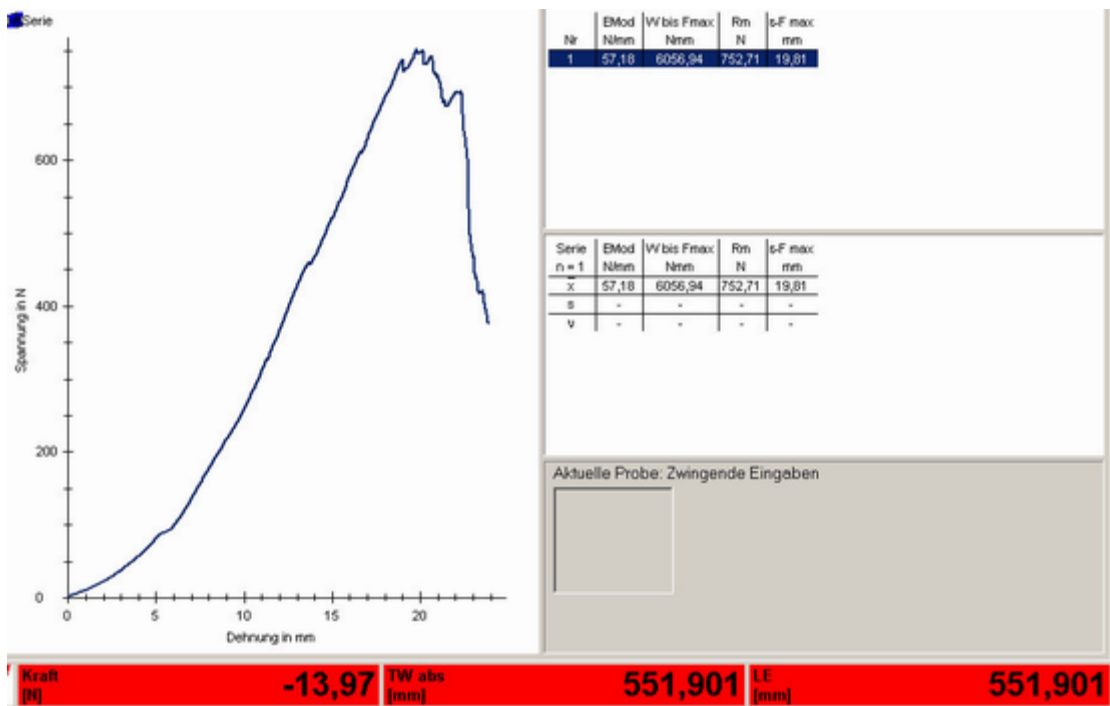


Fig 24. Load-displacement curve for the native coracoclavicular ligament.

**Table 3. Comparison of Biomechanical characteristics of the intact coracoclavicular ligament(CC) and the different reconstruction techniques**

Method	Tensile Strength (N)	Tensile stiffness(N/mm)	Elongation at failure(mm.)	Mode of failure
Native CC ligament (N= 20)	578.28±111.90	77.69±36.03	11.98±2.48	Midsubstance tear 80% Coracoid insertion tear 20%
CA ligament transfer (N= 10)	112.07±33.28	20.74±6.84	12.28±6.76	Suture rupture 10% Suture pullout from lig 90%
2.8-mm Fastak FW#2 ( N=10)	393±57.9	54.37±15.5	9.5±4.1	Anchor pullout 10% Suture rupture 90%
2.8-mm Fastak FW # 5 ( N=10)	412.07±71.19	58.68±15.30	9.08±3.5	Anchor pullout 70% Suture rupture 20 % Eyelet breakage 10 %
3.5-mm Corkscrew FW# 5 ( N=10)	502.70±42.97	81.23±46	8.60±1.94	Anchor pullout 60% Suture rupture 40 %
5.5-mm Corkscrew FT FW#2 ( N=10)	219.60±40.3	39±9.1	7.21±1.94	Fiberwire loop in the screw rupture 100%
5.0-mm Corkscrew FW#5 (N=6)	767.05±109.4	86.08±34.2	10.8±2.95	Anchor pullout 17% Suture rupture 83 %
Unicortical CC screw ( N=10)	333.59±128.88	80.5±47.6	4.6±2.7	Screw pullout 100%
Bicortical CC screw ( N=10)	726.71±230.23	188.6±154.81	5.6±2.47	Screw pullout 70% Coracoid fracture 20% Clavicle fracture 10%
5-mmPDS tape ( N=10)	584.2±191	35.4±12.6	24.9±3.46	Suture rupture 100 %
5-mm Mersilene tape ( N=10)	498.92±53.36	57.2±6.8	11.8±2.89	Suture rupture 100%

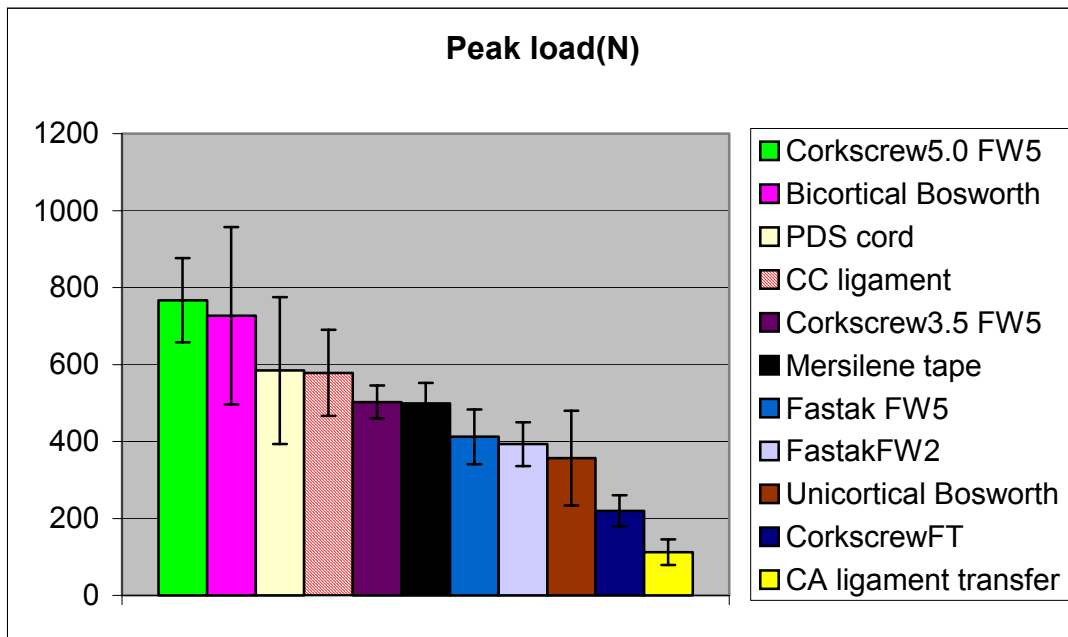


Fig 25. Demonstrating the ultimate tensile strength of different reconstruction techniques

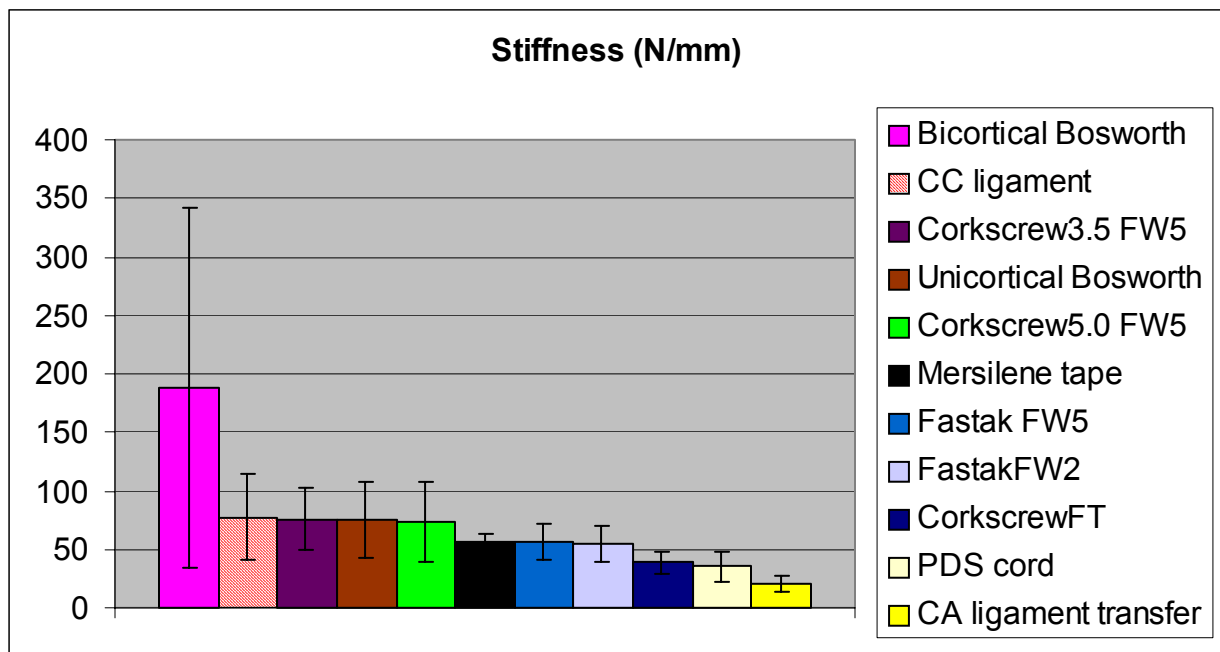


Fig 26. Demonstrating the stiffness of different reconstruction techniques

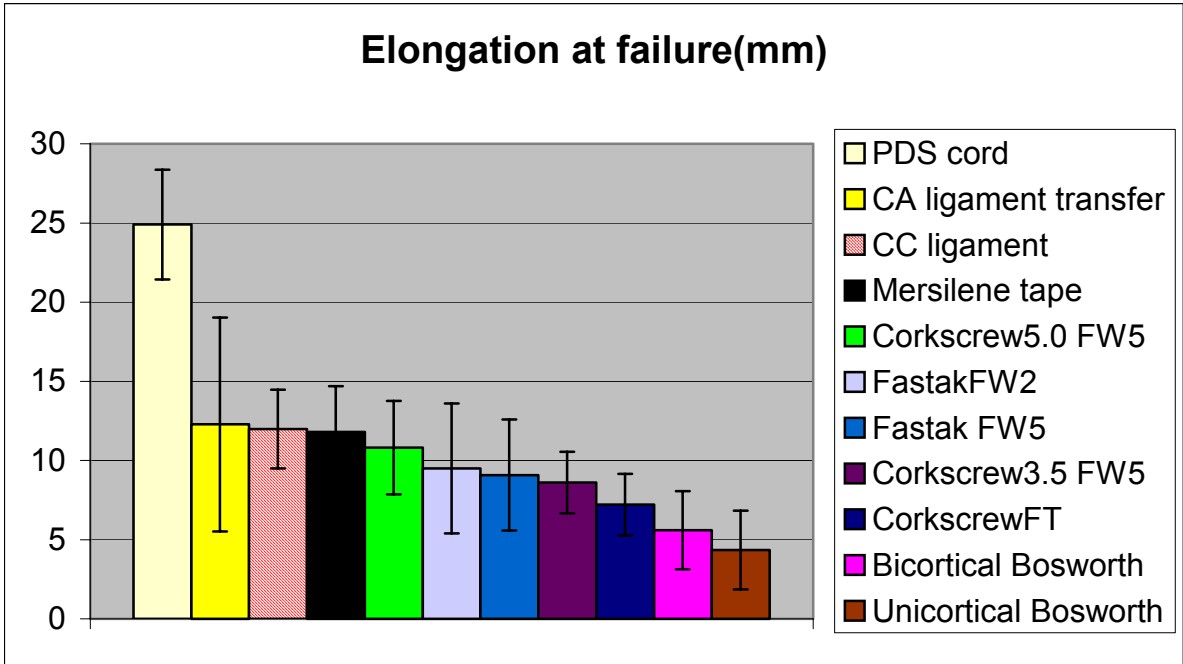


Fig 27. Demonstrating the elongation at failure of different reconstruction techniques

In conclusion, the ultimate tensile strength of the intact coracoclavicular ligament complex was significantly higher than that for Coracoacromial ligament transfer ( $P < 0.001$ ), 2.8-mm Fastak with fiberwire#2 ( $P = 0.001$ ), 2.8-mm Fastak with fiberwire#5 reconstruction ( $P < 0.001$ ), 5.5-mm Corkscrew FT with fiberwire#2 reconstruction ( $P < 0.001$ ), Unicortical coracoclavicular screw reconstruction ( $P < 0.001$ ). There was no significant difference in the mean failure loads of the intact coracoclavicular ligament complex, PDS augmentation, Mersilene tape augmentation and 3.5-mm Corkscrew with fiberwire#5 reconstruction ( $P = 0.978, 0.122, 0.161$  respectively). Only the ultimate tensile strength of Bicortical coracoclavicular screw augmentation and 5.0-mm Corkscrew with fiberwire#5 were significantly higher than the native coracoclavicular ligament complex ( $P = 0.003, 0.003$  respectively).

In term of stiffness, the unicortical Bosworth screw, all suture anchors reconstruction and 5-mm Mersilene tape had stiffness similar to that of the native coracoclavicular ligament ( $P > 0.05$ ). Bicortical Bosworth screw had 2.5 times stiffer than the coracoclavicular ligament ( $P < 0.001$ ). Whereas, Coracoacromial ligament transfer, Coracoclavicular slings using PDS were less than half as stiff as the intact coracoclavicular ligament ( $p < 0.05$ ). The result were also reflected in the elongation at failure



## 5 DISCUSSION

Whenever reconstruction the acromioclavicular joint, it is important to understand that it is not the clavicle that rises and needs to be repositioned, but rather the scapular with the entire arm complex drops down and must be resuspended again. The secure linkage between the clavicle and scapula is not only important for suspending the weight of the arm, but also allowing correct movements of the scapula during arm elevation (Neer, 1990). Operative interventions for these injuries attempt to reproduce, either statically or dynamically, the anatomic restraints that stabilize the acromioclavicular joint. As such, the acromioclavicular joint can be reapproximated using one of three stabilization techniques : (1) primary fixation across the acromioclavicular joint; (2) secondary stabilization of the joint by recreating the anatomic linkage between the distal clavicle and the coracoid process; or (3) dynamic stabilization of the joint by creating an inferiorly directed force on the distal clavicle. These three methods are not mutually exclusive, however, as they may be combined in a single operative setting to produce a final construct with superior mechanical stability.

A variety of surgical procedures, both historic and contemporary, have been described to treat pathological conditions about the acromioclavicular joint dislocation. This article cannot perform the biomechanical studies of all procedures. Rather, we focus on contemporary procedures that are commonly performed by orthopaedic surgeons, our proposed technique using suture anchor system, and the native coracoclavicular ligament complexes.

## 5.1 Primary Stabilization

Primary stabilization of the acromioclavicular joint can be accomplished in variety of methods. Fixation across the joint using various forms of hardware, including Kirschner wires, screws, and Steinman pins, has been used in the past with varying degrees of success. When possible, this fixation may be combined with a primary repair of the acromioclavicular ligament ( Rockwood and Young, 1990; Roper and Levack, 1982).

A fixation device can be performed percutaneously or in an open manner with either smooth or threaded pins. The thin shape of the acromion as well as the curved nature of the distal clavicle can make the percutaneous fixation technically demanding. In addition, large displacement with possible soft tissue interposition may not allow the closed reduction of the joint that is required for percutaneous fixation. Known complication associated with pin fixation are an increased incidence of degenerative acromioclavicular joint disease, breakage and migration of the pins. Hardware migration, the most serious complication of acromioclavicular joint injury, is associated with surgical treatment of dislocations. The frequency of pin migration and seriousness of potential complications have prompted most surgeons to abandon their use, especially the use of smooth pins. Those who still use pins check their position with frequent radiographs and remove them after some interval of healing. Pin migration into the lung and spinal cord has been reported (Mazet et al., 1943; Norell et al.,1965). Lindsey reported migration into a patient's neck posterior to carotid sheath ( Lidsey and Gutokski, 1986). Eaton and Urban reported migration into the pleural cavity ( Eaton and Serletti, 1981; Urban and Jaskiewicz, 1984). Sethi et al. reported laceration of the subclavian

artery by a migrated pin (Sethi et al., 1976). Grauthof and Klammer reported five cases of migration into the aorta, subclavian artery, or lung ( Grauthoff and Klammer, 1978). Even techniques such as bending the end of the wire or using a tension band technique cannot absolutely prevent migration ( Rockwood, 1984). Some recent studies have advocated the use of a specialized hardware called the acromioclavicular hook plate in order to stabilize the dislocated acromioclavicular joint. Originally described in the 1980s, this hardware was associated with a reasonable success in treating acromioclavicular joint dislocations ( Mlasowsky et al., 1988; Sim et al., 1995; Faraj and Ketzer, 2001). Unfortunately, this device can also be associated with an extensive secondary surgery for hardware removal. In addition, a more clinical problem is that plates can bend or dislocate and have a risk of infection ( 10-28%) compared to other techniques ( Sim et al., 1995; Faraj and Ketzer, 2001). Due to these unacceptable risks of significant morbidity and possible mortality, we did not include the primary acromioclavicular fixation technique in our study.

## **5.2 Dynamic Stabilization**

In contrast to the static forms of stabilization, dynamic forms of fixation between the distal clavicle and the coracoid process have also been described. In these techniques, a musculo-tendinous unit is transferred to the inferior surface of the distal clavicle. Thus an inferiorly directed force is generated to depress the distal clavicle against the acromioclavicular joint. In one technique, the tip of the coracoid process, with its attachments to the short head of the biceps and the coracobrachialis, is mobilized and then fixed to the undersurface of the clavicle ( Berson et al., 1978; Dewar and Barrington,

1965; Ferris et al., 1989). Initial description of this procedure reported a satisfactory clinical outcome in a limited number of patients suffering from chronic dislocations of the acromioclavicular joint ( Dewar and Barrington, 1965). Possible complications of the procedure include injury to the musculocutaneous nerve, non union or delayed union of the transfer, and persistent acromioclavicular joint instability. Furthermore, a more recent experience revealed that this procedure can be associated with a high rate of continued shoulder girdle discomfort, especially in older patients ( Ferris et al., 1989). In another form of dynamic fixation, the short head of the biceps tendon is isolated and transferred to the distal clavicle immediately above the coracoid process. Although this procedure has not been widely used, the initial experience was associated with good clinical results( Brunelli, 1988)

General concerns about these dynamic stabilization techniques revolve around their ability to maintain joint reduction and stability. With dynamic stabilization of the acromioclavicular joint, anatomic reduction of the joint may not be maintained during rehabilitation. In addition, dynamic stabilization, without any mechanical augmentation, may allow excessive motion at the acromioclavicular joint. This, in turn, can lead to symptomatic joint instability and arthrosis. As such, dynamic stabilization of the acromioclavicular joint has not been used as a primary surgical option for the acromioclavicular stabilization and also not included in our biomechanical study.

### **5.3 Secondary stabilization**

Secondary stabilization of the acromioclavicular joint can be achieved by recreating the vertical restraint that was originally provided by the coracoclavicular

ligaments. Fixation of the distal clavicle to the coracoid process can be achieved with various methods: Coracoacromial ligament transfer, Coracoclavicular screw fixation, Synthetic loop reconstruction, Suture anchors reconstruction. In our present study, we have performed the biomechanical testing to compare the fixation strength of the native coracoclavicular ligament with the various secondary stabilization methods, including our proposed technique.

### **5.3.1 Native Coracoclavicular ligament complex**

The coracoclavicular ligament is considered to be the primary support from which the scapula is suspended from the clavicle (Nalla and Asvat, 1995). Cadaveric sectioning studies have also aided our understanding of the relative contribution of these ligamentous structures in constraint of distal clavicle translation and rotation. The conoid ligament plays a primary role in constraining anterior and superior rotation and displacement of the distal clavicle, but with further displacement its force contribution increases significantly ( superior displacement-60% of total; anterior displacement-70% of total; superior rotation-82% of total torque). Thus, significant superior displacement of the distal clavicle implies disruption of the conoid ligament ( Fukuda et al., 1986). Fukuda et al also found that the trapezoid ligament contributed the least to superior and horizontal displacement, but most of the constraint (75%) against axial compression of the clavicle toward the acromion at higher displacements.

The strength of the coracoclavicular ligament complex in our study are somewhat higher than, but within the same range as, those reported by Harris et al ( Harris et al., 2000).  $578 \pm 112$  Versus  $500 \pm 134$  N for the ultimate tensile strength,  $78 \pm 36$  versus  $103 \pm 30$

N/mm for the stiffness, and  $12 \pm 2.5$  versus  $7.7 \pm 1.9$  mm for the elongation at failure. Older mean specimen age and different design may account for these differences.

### **5.3.2 Coracoacromial ligament transfer**

Another method of obtaining static fixation between the distal clavicle and the coracoid process is through a ligament transfer. In 1972, Weaver and Dunn originally described transfer the end of coracoacromial ligament to the distal end of the clavicle without supplement fixation and this technique is well-accepted as a standard treatment, especially for a chronic symptomatic acromioclavicular separation. Since the initial report, multiple modifications of the procedure have been used with clinical success ( Morrison and Lemos, 1995; Dumontier et al., 1995; Weinstein et al., 1995). The procedure can be performed with or without distal clavicle resection, and the coracoacromial ligament can be transferred with or without a sliver of bone from the acromion. If the distal clavicle is resected and the coracoacromial ligament is transferred with an attached piece of bone, a solid bone-to-bone contact can be achieved that can, at least in theory, facilitate healing and remodeling. Although ligament substitution using coracoacromial ligament provides an attractive biological solution for acromioclavicular separation, the relatively weak strength of this reconstruction can lead to an incomplete reduction or recurrence, which was reported to be as high as 29% ( Weinstein et al., 1995). Biomechanically, isolated transfer of the coracoacromial ligament exhibited inferior strength in comparison to intact coracoclavicular ligament ( Harris et al., 2000). Also, the importance of the coracoacromial ligament to proper shoulder function has been increasingly recognized. It is no longer thought that, because the coracoacromial ligament attaches two portions of the same bone, it does not have significant function. Instead, its

role in shoulder stability, not only to prevent superior migration of the humeral head, but also anterior and inferior stability, has been well documented ( Field et al., 1997; Lee et al., 2001; Willey, 1991; Sanchez-Sotelo et al.,2001).

The results of the biomechanical testing shows that the coracoacromial ligament has only about 20% of the strength and 25% of the stiffness of the native coracoclavicular ligament. Although failure can occur by coracoacromial ligament rupture, suture breakage or suture pull out from ligament, the weakest area is at the suture-ligament interface, and not the suture or ligament. The strength of the suture-ligament complex was limited by the suture holding strength of the ligament itself, which averaged  $112 \pm 33$  N. Even when we select a suture strong enough to hold the ligament, the failure situations are always the suture cutting through the ligament.

According to the very low strength and stiffness of the Weaver-Dunn procedure, we suggest that augmentation with some form of coracoclavicular ligament fixation should be considered for coracoacromial ligament transfer. Clinically this technique should be augmented by synthetic devices, such as use of sutures , tendon grafts or hardware, in order to protect the reconstruction as it matures.

### **5.3.3 Coracoclavicular screw fixation:**

The technique of placing a screw between the clavicle and the coracoid was described by Bosworth in 1941. The screw was placed percutaneously, using local anesthesia and fluoroscopic guidance. With the patient in a sitting position, a stab wound was made on the superior aspect of the shoulder, 3.8 cm medial to the distal end of the clavicle. After a drill hole was made in the clavicle, an assistant reduced the AC joint by depressing the clavicle and elevating the arm using a special clavicle-depressing

instrument. An awl was used to develop a hole in the superior cortex of the base of the coracoid process, which was visualized using fluoroscopy. A regular bone screw was then inserted. The screw was left indefinitely, unless specific indications for removal developed. Bosworth did not recommend either repair of the coracoclavicular ligaments or exploration of the AC joint. Bosworth also described a newly developed lag screw with a broad head, which he preferred to the original regular bone screw.

Percutaneous insertion of a cannulated coracoclavicular screw was reported by Tsou in 1989. Tsou fluoroscopically placed a guide pin from the clavicle to the coracoid process. After adequate positioning of the pin within the coracoid had been confirmed radiographically, a cannulated drill bit and screw were sequentially passed over the guide pin. Tsou reported a 32% technical failure rate in 53 patients with complete AC dislocation using this technique. Accurate insertion of the screw is difficult to perform percutaneously. Furthermore, the percutaneous technique does not allow coracoclavicular ligament repair, deltoid and trapezius reattachment, or AC joint debridement.

Many other surgeons have reported the use of a Bosworth screw or a slight modification of the original technique. In 2003, Talbert et al proposed the 4.5-mm bioabsorbable screw fixation in coracoclavicular ligament reconstruction. The study was performed in seven matched pairs of fresh frozen shoulders. The average pullout strength of the 4.5-mm bioabsorbable screw was  $580.4 \pm 188.8$  N, exceeded the reported strength ( $500 \pm 134$  N) of the intact coracoclavicular ligament (Harris et al., 2000). Rockwood et al presented a technique for the chronic, symptomatic dislocated AC joint in which the coracoacromial ligament was transferred from its acromial insertion to the intramedullary canal of the clavicle, along with temporary placement of a coracoclavicular screw to



stabilize the clavicle until the ligament healed. The screw is usually removed 8 weeks postoperatively, necessitating a second procedure.

In our study, the mechanical performance of coracoclavicular screw fixation was closest to that of the native coracoclavicular ligament. If bicortical purchase was obtained, ultimate strength was 25% higher than that in the intact ligament. However if only one cortex was breached, strength was reduced by 38% compared with the intact ligament, indicating the critical importance of correct screw placement.

Despite the biomechanical advantages, the complication of Bosworth technique include screw pull out, infection and irritation over the screw head ( Galpin, 1985). Screw breakage has also been reported ( Guy, 1998) . However the risk of early implant removal to prevent implant failure should be balanced against the risk of recurrent deformity, which may be as high as 35% if the implant is removed at 6 weeks after the surgery ( Banniser et al., 1989)

#### **5.3.4 Synthetic loop reconstruction**

Obviating the need for subsequent hardware removal, fixation between the distal clavicle and the coracoid process can also be obtained with synthetic loop. Simple cerclage techniques (Colosimo et al.,1996; Hessmann et al., 1995; Kiefer et al., 1986; Nuber et al.,1999) using various synthetic materials have also been described. Multiple strands of suture can be passed through or around both the distal clavicle and the coracoid process to simulate the stability that was originally provided by the coracoclavicular ligaments. Stam and Dawson and Goldberg et al described the use of Dacron ligaments looped over the clavicle ( Stam and Dawson, 1991; Golberg et al., 1987). Verhaven et al

utilized a double Dacron velour ligament for fixation in a prospective study in 28 consecutive patients with a mean follow-up of 5.1 years; 71% had good or excellent results ( Verhaven et al., 1993). There was little correlation between the end result and the degree of residual dislocation, coracoclavicular ossification and posttraumatic arthritic changes, or osteolysis of the distal clavicle. Browne et al. used 5-mm mersilene tape for coracoclavicular fixation ( Browne et al., 1977). Simple coracoclavicular cerclage causes anterior subluxation of the distal clavicle with malreduction of the acromioclavicular joint (Baker et al., 2003; Jerosch et al.,1999; Morrison and Lemos, 1995). A modification of the cerclage technique to place material through an osseous tunnel in the clavicle rather than complete around it would be better to avoid such complication. Morrison and Lemos reported 12 of 14 good and excellent results when using a synthetic loop through drill holes in the base of the coracoid and the anterior third of the clavicle ( Morrison and Lemos, 1995) .

Polydioxanonsulphate ( PDS) bands have a high initial strength 350 N for 5-mm bands and 700 N for the 10-mm bands. The half life of PDS band strength is 6 weeks. Hessmann et al. (1995) proposed acromioclavicular reconstruction augmented with 5-mm and 10-mm PDS bands. The results were good and excellent in 89% with 92% achievement of range of motion with an abduction deficit less than 20 degrees. This guarantees adequate temporary postoperative acromioclavicular joint reinforcement until the acromioclavicular and coracoclavicular ligaments are sufficiently healed to provide acromioclavicular stability ( Hessmann et al., 1995). The advantages of using PDS band augmentation in cases of complete acromioclavicular separation are that there is no risk of movement of implants and metal removal is avoided. Unfortunately, the redislocations

at the acromioclavicular joint using PDS band were also reported in 1.6% to 25 % of the patients (Gollwitzer, 1993, Monig et al., 1999). Postoperative infection due to PDS augmentation occurred in up to 15.4% of patients. In addition, erosion of cerclage material through the clavicle or coracoid was well-documented complication ( Dahl, 1981; Dahl, 1982; Goldberg et al., 1987). Moneim and Balduini noted a coracoid fracture after reconstruction of the coracoclavicular ligaments through two drill holes in the clavicle ( Moneim and Balduini, 1982). Fractures of the distal clavicle secondary to the use of loop sutures between the coracoid and the distal clavicle have been reported ( Dust et al., 1989, Martell, 1992). Bostman and Pihlajamaki reported the primary complication of PDS implants placed intraarticularly is aseptic synovitis ( Bostman and Pihlajamaki, 2000). The implant create an distinct foreign body reaction within the tissue. Gollwitzer suspected an incompatibility with PDS cord in 3 of 29 patients. Although histologic examination showed positive bacteriology, wound erythema and drainage only disappeared after removal of PDS cords ( Gollwitzer, 1993). Histologic studies of foreign body reaction of PDS cord have shown polymetric birefringent particles surrounded by mononuclear phagocytes and multinucleated foreign body giant cells ( Rokkanen et al., 2000 )

The use of number five Mersilene tape ( Ethicon, Inc., Somerville, New Jersey) to hold the clavicle to the coracoid process has been popularized by Weaver and Dunn for treating both acute and chronic acromioclavicular separations. Mersilene tape has the advantage of being nonstretchable, as compared with PDS and fascia lata or tendonous material. Also fibrous ingrowth can occur around the tape.

In our study, we found that the coracoclavicular fixation using synthetic loops, both PDS and Mersilene tape, were comparable with intact coracoclavicular ligament in terms of strength. However the PDS tape, provided stiffness, demonstrating less than 50% the stiffness of native coracoclavicular ligament and elongation at failure, showing more than 100% comparing to the coracoclavicular ligament complex. In summary we concluded that the coracoclavicular ligament reconstruction using PDS band may not be appropriate for the reconstruction of the severe types of the acromioclavicular joint dislocation when large displacement have occurred. Although the PDS band is strong ( high ultimate tensile strength) but it is very elastic (low stiffness), undergoing marked deformation at low load, and may not be suitable for high graded acromioclavicular dislocation.

### **5.3.5 Suture anchors with small titanium plate**

Attachment of soft tissue to bone is a technique frequently required in orthopaedic surgical procedures. Suture anchors have gained wide acceptance to facilitate the reattachment of tissue to bone. They are used in repair of soft tissue avulsions from bone as well as in reconstructive procedures. In addition, they are commonly used for glenohumeral instability, SLAP, and rotator cuff repairs ( Bacilla,1997; Burkhart, 2001; Gartsman, 2001). Other applications include the open reattachment of tendons and ligaments in the hand, elbow ( Bovard, 1994; Hallock, 1994; Rehak, 1994) , proximal humerus, knee( Gillquist, 1992) and foot (Pederson, 1991; Chen, 1992; Schon, 1991). During the past decade, both considerable development and consolidation in the area of suture anchors have occurred. First-generation suture anchors often did not provide

adequate fixation in the cancellous bone. However, the current generation of anchors designed has been shown to possess excellent pullout characteristics ( Barber et al., 1995; Barber et al.,1996; Barber et al.,1997; Barber et al.,1999). Some anchors have been phased out, and new anchor designs were introduced. The continued development of anchors requires surgeons to stay current with objective measures of anchor performance. This study evaluated the biomechanical properties of 5 suture anchors in acromioclavicular reconstruction. The anchors tested included 2.8-mm Fastak with fiberwire #2, 2.8-mm Fastak with fiberwire#5, 3.5-mm corkscrew with fiberwire#5, 5.0-mm corkscrewFT with fiberwire#2, 5.0-mm corkscrew with fiberwire#5

The corkscrew 5.0 with fiberwire number 5.0 had the lowest percentage of anchor failures and produced the most highest ultimate tensile strength values 767 N. Most other suture anchors failure were suture breakage at the anchor eyelets or pull out of the suture anchor from coracoid except for the CorkscrewFT. The Corkscrew FT with fiberwire#2 failed by suture broken 100% with significantly less force overall than the other anchors ( Fig.28). This may be attributed to the weakest link between the suture and loop in the screw.

Because suture anchors are usually very small, the anchor eyelets have to be narrow and thin, making them prone to sharp edges. The bigger the eyelet, the smoother it is. Therefore, it is more suture-friendly, and stronger suture material or multiple strands could be used. The assumption that larger anchors are less likely to weaken sutures at their eyelet is confirmed by the study of Meyer et al ( Meyer et al., 2002). Generally speaking, there are 2 eyelet designs: round eyelets and streamlined eyelets with suture protection channels. Streamlined eyelets with adjacent sharp edges to the suture channel

are the most sensitive to the direction of mechanical loading of the sutures. They cut the suture material if the threads lay outside the suture channel. Although anchors with round eyelets are less sensitive to the anchor insertion orientation, they may also cut sutures. Therefore, the smoothness of the eyelet edge is more important than the design type.

**Table 4. Suture Anchors Properties**

Type of Anchor	Material	Inner diameter ( mm)	Outer diameter ( mm)	Length (mm)	Predill
2.8-mm Fastak	Titanium Alloy	1.8	2.8	11.7	No
3.5-mm Corkscrew	Titanium Alloy	2.2	3.5	15	No
5.0-mm Corkscrew	Titanium Alloy	3.4	5.0	15	No
Corkscrew FT	Titanium Alloy	3.5	5.5	15	3.5

A statistical analysis of the anchors in our study showed that for screw anchors, the larger size , the greater the pull-out strength. This is because of the increasing surface area on the screw threads with the larger sizes. This correlation was highly significant in our present study (  $P = 0.0002$ ).




Fig 28. The fiberwire loop in the 5.5-mm CorkscrewFT rupture, the anchor does not pullout

The mechanical performance of the whole construct evaluated in this study is determined by the relationship of two parameters: the pullout strength of the anchor inserted into a defined bony environment, which depends on the strength of the suture material, anchor configuration, the local bone quality, anchor suture interaction, which depends strongly on the material, configuration, and surface of the eyelet. Whereas the anchor-bone interaction depends strongly on the anatomic and mechanical conditions at the insertion site. The quality of bone at the insertion site appears to be a major factor in the overall pull-out strength. Carpenter et al. found that there was a correlation between cortical thickness and pull-out strength (Carpenter et al., 1993). Thus, the variation in ultimate tensile strength was not completely explained by the cortical thickness at the insertion sites and could possibly be explained by a combination of cortical and trabecular bone properties. It is likely that the trabecular bone quality has a role because anchors are generally placed in position that includes both cortical and trabecular bone. In our study, we found that the coracoid process composed of more cortical bone than cancellous bone. So the pull out strength of the suture anchors were higher than the previous reported which were performed in metaphyseal region, which composed of more cancellous component than cortical component (Barber et al., 1999).

Jerosch et al studied 8 different techniques to reconstruct the acromioclavicular in human cadveric shoulder specimens and found that a bone anchor system for distal fixation in the base of the coracoid process and medialized hole in the clavicle restored anatomy best (Jerosch et al., 1999). Baker et al performed a cadaveric study examining the acromioclavicular joint congruity after different methods of coracoclavicular loop reconstruction and concluded that the drill hole moved anteriorly on the clavicle, joint



congruity was more closely approached and less anterior displacement of the clavicle occurred. However, none of the methods of coracoclavicular loop fixation restored full acromioclavicular joint congruity ( Baker et al., 2003).

Another advantage of suture anchors are their simplicity of fixation. Their small size enable them to be completely buried into the bone thus decreasing the risk of migration into the joint or surrounding tissue, while most of traditional techniques of fixation require large exposure of bone and are not well suited for small structures and tight places.

In summary, comparison the pullout strength of the 5 anchoring methods revealed that the 5-mm corkscrew with fiberwire#5.0 was the strongest method with 1.3 times stronger than the coracoclavicular ligament ( $P=0.003$ ) and 2, 1.8, 1.5 and 3.5 times stronger than 2.8-mm Fastak with FW2.0 ( $P= 0.005$ ), 2.8-mm Fastak with FW5.0 ( $P< 0.001$ ), 3.5-mm Corkscrew with FW5.0( $P<0.001$ ), Corkscrew FT with FW2.0 ( $P<0.001$ ) respectively.

## 6 CLINAL APPLICATION

In considering the clinical applications of the present study, several significant limitations should be recognized. First, because of limited availability, mechanical testing was performed on older specimens, in which age-related bone density changes are common. Failure mode and magnitude may not be the same in a younger athletic population in which these injuries typically occur. Second, this experiment isolates and evaluates the static stabilizers of the acromioclavicular joint. No secondary dynamic stabilizers are considered. All musculotendinous insertions are released and removed. These secondary stabilizers play a role in acromioclavicular joint stability, but to include their contribution was beyond the scope of this study. Third, this study is an in vitro, time-zero study. We are unable to determine the effects of healing process on the coracoclavicular ligament overtime in an in vivo model. Forth, we studied unidirectional load displacement, whereas the actual coracoclavicular ligament underwent stresses in multiple planes. Finally, this study did not address the stability of the reconstruction in cyclic loading as might be experienced during in vivo conditions.

Nonetheless, the results the present study provide useful quantitative information about the immediate mechanical behavior of our proposed technique and contemporary reconstructive techniques in comparison with the intact coracoclavicular ligament complex. Understanding the mechanical limits of each reconstruction may also indicate the loads and range of shoulder motion tolerable during rehabilitation.

## **7 CONCLUSION**

We have presented an alternative technique for acromioclavicular joint reconstruction. This technique, which uses suture anchors and small titanium plate which originally designed for rotator cuff repairs, facilitates the minimal exposure or arthroscopic procedure. Attractive characteristics of this technique include the ability to use a strong anchor and suture, which has the same biomechanical property as native coracoclavicular ligament. Most importantly, however, is the strength of the reconstruction, which facilitates aggressive postoperative rehabilitation, earlier return to sports and work, and better outcomes. Finally, clinical studies and long term follow-up studies will be necessary to determine the true indications for our new suture anchors reconstruction of the coracoclavicular ligaments.

## 8 ABSTRACT

To date, there is no consensus regarding surgical treatment for severely dislocated acromioclavicular joints. The purpose of this study was to compare the biomechanical properties of our proposed technique using suture anchors and small titanium plate with those of the native coracoclavicular ligament and various other standard coracoclavicular reconstruction techniques. We tested 20 fresh-frozen cadaveric bone-ligament-bone preparations of the coracoclavicular ligament in uniaxial tension until failure. Reconstruction of the coracoclavicular ligament was achieved using coracoacromial ligament transfer, Bosworth screws, Synthetic loop, 5 modifications of suture anchors with small titanium plate; all reconstructions were also tested to failure. The intact coracoclavicular ligament failed by avulsion or midsubstance tear at 578(+112) N, with a stiffness of 77(+36)N/mm and elongation at failure of 12(+2.5) mm. The ultimate tensile strength of the coracoclavicular ligament complex was significantly higher than that for coracoacromial ligament transfer ( $P < 0.001$ ), 2.8-mm Fastak with fiberwire#2 ( $P = 0.001$ ), 2.8-mm Fastak with fiberwire#5 ( $P < 0.001$ ), 5.5-mm Corkscrew FT with fiberwire#2 ( $P < 0.001$ ), Unicortical coracoclavicular screw reconstruction ( $P < 0.001$ ). There was no significant difference in the mean failure loads of the coracoclavicular ligament complex, PDS augmentation, Mersilene augmentation and 3.5-mm Corkscrew with fiberwire#5 reconstruction ( $P = 0.978, 0.122, 0.161$  respectively). Only the ultimate tensile strength of Bicortical coracoclavicular screw augmentation and 5.0-mm Corkscrew with fiberwire#5 were significantly higher than the native coracoclavicular ligament complex, 726(+230)N ( $P = 0.003$ ) and 767(+109)N ( $P = 0.003$ ) respectively. In term of stiffness, the unicortical Bosworth screw, all suture anchors reconstruction and 5-mm Mersilene tape had stiffness similar to that of the native coracoclavicular ligament ( $P > 0.05$ ). Bicortical Bosworth screw were 2.5 times stiffer than the coracoclavicular ligament ( $P < 0.001$ ). Whereas, Coracoacromial ligament transfer, Coracoclavicular slings using PDS were less than half as stiff as the intact coracoclavicular ligament ( $p < 0.05$ ). These results provide a useful baseline for comparison of the initial performance of reconstructive techniques with the performance of the native coracoclavicular ligament

**Key words:** Acromioclavicular joint Separation, Biomechanical study, Reconstruction, Suture anchor

## Zusammenfassung

Bis jetzt gibt es keine Übereinstimmung über die chirurgische Behandlung schwer dislozierter Akromioklavikular-Gelenke. Der Zweck dieser Studie war, die biomechanischen Eigenschaften unserer vorgeschlagenen Technik mit Nahtankern und kleinen Titanplatten mit denen des nativen korakoklavikulären Ligaments und verschiedener anderer Standardrekonstruktionstechniken zu vergleichen. Wir prüften 20 frisch gefrorene Knochen-Ligament-Knochen-Präparate des korakoklavikulären Ligaments aus Leichen in der einachsigen Zugspannung bis zum Versagen. Die Rekonstruktion des korakoklavikulären Ligaments wurde mit korakoakromialer Ligamentübertragung, Bosworth-Schrauben, synthetischer Schleife und 5 Veränderungen der Nahtanker mit einer kleinen Titanplatte erzielt; alle Rekonstruktionen wurden bis zum Versagen geprüft. Das intakte korakoakromiale Ligament versagte durch Avulsion oder durch einen Midsubstance-Riss bei  $578(\pm 112)$  N, mit einer Steifigkeit von  $77(\pm 36)$  N/mm und Verlängerung an der Rissstelle von  $12(\pm 2.5)$  Millimeter. Die Bruchfestigkeit des korakoakromialen Ligamentkomplex war signifikant höher als die für die korakoakromiale Ligamentübertragung ( $P < 0.001$ ), 2.8-Millimeter Fastak mit Fiberwire#2 ( $P = 0.001$ ), 2.8-Millimeter Fastak mit Fiberwire#5 ( $P < 0.001$ ), 5.5-Millimeter Corkscrew FT mit Fiberwire#2 ( $P < 0.001$ ), oder die Rekonstruktion mittels unikortikaler korakoakromialer Schraube ( $P < 0.001$ ). Es gab keinen signifikanten Unterschied bezüglich der mittleren Versagenslasten des korakoklavikulären Ligamentkomplexes, der PDS Augmentation, der Mersilene Augmentation und des Corkscrew 3.5-Millimeter mit Fiberwire#5 Rekonstruktion ( $P = 0.978, 0.122, \text{ bzw. } 0.161$ ). Nur die Bruchfestigkeit der bikortikalen korakoklavikulären Schrauben Augmentation und des Corkscrew 5.0-Millimeter mit Fiberwire#5 waren signifikant höher als der native korakoakromiale Ligamentkomplex,  $726(\pm 230)$  N ( $P=0.003$ ) bzw.  $767(\pm 109)$  N ( $P=0.003$ ). In Bezug auf die Steifigkeit waren die unikortikale Bosworth-Schraube, alle Nahtankerrekonstruktionen und das 5-Millimeter Mersilene-Band dem nativen korakoklavikulären Ligaments ähnlich ( $P > 0.05$ ). Die Bicortical Bosworth-Schraube war 2,5mal steifer als das korakoklavikuläre Ligament ( $P < 0.001$ ), während sich die korakoakromiale Ligamentübertragung und korakoklavikuläre Schlingen mittels PDS weniger als halb so steifes wie das intakte korakoklavikuläre Ligament erwiesen ( $p < 0.05$ ). Diese Ergebnisse bieten eine nützliche Ausgangslinie für den Vergleich der initialen Leistung rekonstruktiver Techniken mit der Leistung des nativen korakoakromialen Ligaments. **Key words:** Acromioclavicular joint Separation, Biomechanical study, Reconstruction, Suture anchor

## 9 REFERENCES

- Albrecht F. The Balsler plate for acromioclavicular fixation. *Chirurg.* 53 (1983) 732-734
- Allman F.Jr. Fractures and ligamentous injuries of the clavicle and its articulation. *J Bone Joint Surg.* 49A ( 1976) 774–784
- Baber F.A., Herbert M.A., Click J.N. The ultimate tensile strength of suture anchors. *Arthroscopy.* 11 (1995) 21-28
- Baber F.A., Herbert M.A., Click J.N. Suture anchor strength revisited. *Arthroscopy.* 12 (1996) 32-38
- Baber F.A., Herber M.A., Click J.N. Internal fixation strength of suture anchors: Update 1997. *Arthroscopy.* 13 (1997) 355-362
- Baber F.A., Herber M.A., Click J.N. Suture anchors: Update 1999. *Arthroscopy.* 15(1999) 719-725
- Baker J.E., Nicandri G.T., Young D.C., Owen J.R., Wayne J.S. A cadaveric study examining acromioclavicular joint congruity after different methods of coracoclavicular loop repair. *J Shoulder Elbow Surg.* 12 (2003) 595-598
- Bailey R: A dynamic repair for complete AC joint dislocation. *J Bone Joint Surg Am.* 47 ( 1965) 858-863
- Bailey R, O'Connor G, Tilus P : A dynamice repair for acute and chronic injuries of the acromioclavicular area. *J Bone Joint Surg.* 54 ( 1972) 1802-1806
- Banniser G.C., Wallace W.A., Stableforth P.G., Hutson M.A. The management of acute acromioclavicular dislocation. A randomized prospective controlled trial. *J Bone Joint Surg.* 71B (1989) 848-850
- Bearden J., Hughston J., Whatley W. Acromioclavicular dislocation: Method of treatment. *J Sports Med.* 1 ( 1973) 5-17
- Berson B.L., Gillbert M.S., Green S. Acromioclavicular dislocations: treatment by transfer of the conjoined tendon and distal end of the coracoid process to the clavicle. *Clin Orthop.* 135 (1978) 157-164
- Bostman O.M., Pihlajamaki H.K. Adverse tissue reactions to bioabsorbable fixation devices. *Clin Orthop.* 371 (2000) 216-227

- Bosworth B.M. Acromioclavicular separation: New method of repair. *Surg Gynecol Obstet.* 73 (1941) 866–871
- Bovard R.S., Derkash R.S., Freeman J.R. Grade III avulsion fracture repair on the UCL of the proximal joint of the thumb. *Orthop Rev.* (1994) 167-169
- Browne J.E., Stanley R.F., Tullos H.S. Acromioclavicular joint dislocations: comparative results following operative treatment with and without primary distal clavisectomy. *Am J Sports Med.* 5 (1977) 258–263
- Brunelli G, Brunelli F: The treatment of acromioclavicular dislocation by transfer of the short head of biceps. *Int Orthop.* 12 ( 1988) 105-108
- Bunnell S. Fascial graft for dislocation of the acromioclavicular joint. *Surg Gynecol Obstet.* 46 ( 1928) 563-564
- Carpenter J.E., Fish D.N., Huston L.J., Goldstein S.A. Pull-out strength of five suture anchors. *Arthroscopy.* 9 (1993) 109-113
- Caspi I., Ezra E, Nerubay J. Musculocutaneous nerve injury after coracoid process transfer for clavicle instability: report of three cases. *Acta Orthop Scand.* 58 (1987) 294-295
- Cave E.F. *Fractures and Other Injuries.* Chicago, Year Book Medical. 1958
- Cadenat F.M. The treatment of dislocations and fractures of the outer end of the clavicle. *Int Clin.* 1 (1917) 145–169
- Chen D.S., Wertheimer S.J. Centrally located osteochondral fracture of the talus. *J Foot Surg.* 31 (1992) 134-140
- Colosimo A.J., Hummer C.D. 3rd, Heidt R.S. Jr. Aseptic foreign body reaction to Dacron graft material used for coracoclavicular ligament reconstruction after type III acromioclavicular dislocation. *Am J Sports Med.* 24 (1996) 561–563
- Copeland S., Kessel L. Disruption of the acromioclavicular joint: Surgical anatomy and biological reconstruction. *Injury.* 11 (1980) 208-214
- Daly P., Sim F.H., Simonet W.T. Ice hockey injuries: a review. *Sports Med.* 10 (1990) 122–131
- DePalma A.F. *Surgery of the shoulder*, 2nd ed. Philadelphia: JB Lippincott. 1973
- Dewar F.P., Barrington T.W. The treatment of chronic acromioclavicular dislocation. *J Bone Joint Surg Br.* 47 ( 1965) 32-35.

- Diaz J.J., Gregg P.J. Acromioclavicular joint injuries in sport: recommendations for treatment. *Sports Med.* 11 (1991) 125–132
- Dumontier C., Sautet A., Man M. Acromioclavicular dislocations: treatment by coracoacromial ligamentoplasty. *J Shoulder Elbow Surg.* 4 (1995) 130-134
- Dust WN, Lenczner EM. Stress fracture of the clavicle leading to nonunion secondary to coracoclavicular reconstruction with Dacron. *Am J Sports Med.* 17 (1989) 128–129.
- Ferris B.D., Bhamra M., Paton D.F. Coracoid process transfer for acromioclavicular dislocations: a report of 20 cases. *Clin Orthop.* 242 (1989) 184-194
- Field L.D., Dines D.M., Zabinski S.J. Hemiarthroplasty of the shoulder for rotator cuff arthropathy. *J Shoulder Elbow Surg.* 6 (1997) 18-23
- Fukuda K., Craig E.V., An K.N., Cofield R.H., Chao E.Y.S. Biomechanical study of the ligamentous system of the acromioclavicular joint. *J Bone Joint Surg.* 68A (1986) 434–440
- Galpin R.D., Hawkins R.J., Grainger R.W. A comparative analysis of operative versus nonoperative treatment of grade III acromioclavicular separations. *Clin Orthop.* 193 (1985) 150-155
- Gerber C., Rockwood CJ. Subcoracoid dislocation of the lateral end of the clavicle. A report of three cases. *J Bone Joint Surg Am.* 69 (1987) 924-927
- Gillquist J. Reconstruction of the anterior cruciate ligament: Indications, operative technique, and rehabilitation. *Oper Tech Orthop.* 2 (1992) 104-111
- Glorian B., Delplace J. Dislocation of the acromioclavicular treated by transplant of coracoid process. *Rev Chir Orthop.* 59 (1973) 667-679
- Goldberg J.A., Viglione W., Cumming W.J. Review of coracoclavicular ligament reconstruction using Dacron graft material. *Aust NZ J Surg.* 57 (1987) 441–445
- Gollwitzer M. Surgical management of complete acromioclavicular joint dislocation (Tossy III) with PDS cord cerclage. *Aktuelle Traumatol.* 23 (1993) 366-370
- Grauthoff V., Klammer H. Complications due to migration of a Kirschner wire from the clavicle. *Fortschr Geb Roentgenstr Nuklearmed.* 128 (1978) 591-594



- Harris R.I., Wallace A.L., Harper G.D., Goldberg J.A., Sonnabend D.H., Walsh W.R. Structural properties of the intact and reconstructed coracoclavicular ligament complex. *Am J Sports Med.* 28 ( 2000) 103–108
- Hallock G.G. The Mitek mini GII anchor introduced for tendon reinsertion in the hand. *Ann Plastic Surg.* 33 (1994) 211-213
- Hessmann M., Gotzen L., Gehling H. Acromioclavicular reconstruction augmented with polydioxanonsulphate bands. Surgical technique and results. *Am J Sports Med.* 23 (1995) 552–56
- Imhoff AB, Ansah P.: Arthroscopic Reconstruction of the Acromio-Clavicular Joint. Workshop, Congress of German Association of Arthroscopy Dresden 4.October 2003
- Imhoff AB., Ticker J., Fu FH: An Atlas of Shoulder Arthroscopy. Dunitz London 2003
- Inman V.T., Saunders J.B. deCM, Abbott L.C. Observations on the function of shoulder joint. *J Bone Joint Surg.* 26 (1944) 1–30
- Jerosch J., Filler T., Peuker E., Greig M, Siewering U. Which stabilization technique corrects anatomy best in patients with A—separation? An experimental study. *Knee Surg Sports Traumatol Arthrosc.* 7 (1999) 365-72
- Kiefer H., Claes, Burri C. The stabilizing effect of various implants on the torn acromioclavicular joint. Biomechanical study. *Arch Orthop Trauma Surg.* 106 (1986) 42-46
- Lee T.Q., Black A.D., Tibone J.E. Release of the coracoacromial ligament can lead to glenohumeral laxity: A biomechanical study. *J Shoulder Elbow Surg.* 10 (2001) 68-72
- Linsey R, Gutowski W: The migration of a broken pin following fixation of the AC joint: A case report and review of the literature. *Orthopedics.* 9 (1986) 413-416
- Martell J.R. Clavicular nonunion complications with the use of Merselene tape. *Am J Sports Med.* 20 (1992) 360–362
- Mazet R. Jr. Migration of Kirschner wire from shoulder region into lung: report of two cases. *J Bone Joint Surg.* 25 (1943) 477-483
- Meyer D., Nyffeler R., Fucentese S., Gerber C. Failure of suture material at suture anchor eyelets. *Arthroscopy.* 18 ( 2002) 1013-1019

- Mlasowsky B., Brenner P., Duben W. Repair of complete acromioclavicular dislocation (Tossy stage III) using Balser's hook plate combined with ligament sutures. *Injury*. 19 (1988) 227-232
- Moneim M.S., Balduini F.C. Coracoid fracture as a complication of surgical treatment by coracoclavicular tape fixation. A case report. *Clin Orthop*. 168 (1982) 133 – 135,
- Monig S.P., Burger C., Helling H.J., Prokop A., Rehm K.E. Treatment of complete acromioclavicular dislocation: Present indications and surgical technique with bioabsorbable cords. *Int J Sports Med*. 20 ( 1999) 560-562
- Morrison D.S., Lemos M.J. Acromioclavicular separation. Reconstruction using synthetic loop augmentation. *Am J Sports Med*. 23 (1995) 105–110
- Mumford E. Acromioclavicular dislocation- a new treatment. *J Bone Joint Surg Am*. 23 (1941) 799-802
- Nalla S., Asvat R. Incidence of the coracoclavicular joint in South Africa populations. *J Anat*. 186 ( 1995) 645-649
- Neault M.A., Nuber G.W., Marymont J.V. Infections after surgical repair of acromioclavicular separations with nonabsorbable tape or suture. *J Shoulder Elbow Surg*. 5 (1996) 477–478.
- Neer C.S. *Shoulder reconstruction*. Saunders, Philadelphia. (1990)
- Neviaser R.J. Injuries to the clavicle and acromioclavicular joint. *Orthop Clin North Am* 18 (1987) 433-438
- Norell H. Jr., Llewellyn R.C. Migration of a threaded Steinmann pin from an acromioclavicular joint into the spinal canal: a case report. *J Bone Joint Surg Am*. 47 (1965) 1024-26
- Nuber G.W., Bowen M.K. Acromioclavicular joint injuries and distal clavicle fractures. *J Am Acad Orthop Surg*. 5 (1997) 11-18
- Nuber G.W., Bowen M.K. Disorders of the acromioclavicular joint: pathophysiology, diagnosis, and management. In: Iannotti JP, Williams GR, eds. *Disorders of the shoulder: diagnosis and management*. Philadelphia: Lippincott Williams & Wilkins. (1999) 739–764

- Pederson B., Wertheimer S.J., Tesoro D., Coraci M. Mitek anchor system: A new technique for tenodesis and ligamentous repair of the foot and ankle. *J Foot Surg.* 30 (1991) 48-51
- Powers JA, Bach PJ: Acromioclavicular separation. *Clin Orthop* 104: 213-223, 1974
- Rehak D.C., Sotereanos D.G., Bowman M.W., Herndon J.H. The Mitek bone anchor: Application to the hand, wrist and elbow. *J Hand Surg.* 19A (1994) 853-860
- Rockwood C.A. Jr., Young D.C. Disorders of the acromioclavicular joint, in Rockwood CA Jr, Matsen FA III (eds):*The Shoulder*.Volume 1. Philadelphia, WB Saunders. (1990) 413–476
- Rockwood C.A. Jr. Injuries to the acromioclavicular joint, in Rockwood CA Jr, Green DP (eds):*Fractures in Adults*. Volume 1. Second edition. Philadelphia, JB Lippincott. (1984) 860–910, 974–982
- Rockwood C.A., Matsen F.A. *The shoulder*. Saunders, Philadelphia. (1998) 948-951
- Rokkanen P.U., Bostman O.M., Hirvensalo E. Bioabsorbable fixation in orthopaedic surgery and traumatology. *Biomaterials.* 21 (2000) 2607-2613
- Rowe C.R., Cave E.F. *Fractures and other injuries*. Chicago: Year Book Medical. 1961
- Roper B.A., Levack B. The surgical treatment of acromioclavicular dislocations. *J Bone Joint Surg.* 64 (1982) 587-599
- Salter E.G. Jr., Nasca R.J., Shelley B.S. Anatomical observations on the acromioclavicular joint and supporting ligaments. *Am J Sports Med.* 15 (1987) 199–206
- Sanchez-Satelo J., Cofield R.H., Rowland C.M. Shoulder hemiarthroplasty of glenohumeral arthritis associated with severe rotator cuff deficiency. *H Bone Joint Surg.* 83A (2001) 1814-1822
- Schon L.C., Clanton T.O., Baxter D.E. Reconstruction for subtalar instability: A review. *Foot Ankel.* 11 (1991) 319-325
- Sethi G.K., Scott S.M. Subclavian artery laceration due to migration of a Hagie pin. *Surgery.* 80 (1976) 644-646
- Sim E., Schwarz N., Hocker K., Berzlanovich A. Repair of complete acromioclavicular separations using the acromioclavicular-hook plate. *Clin Orthop.* 314 (1995) 134-142

- Skjeldal S, Lundlad R, Dullerud R. Coracoid process transfer for acromioclavicular dislocation. *Acta Orthop Scand.* 59 (1988) 180-182
- Stam L., Dawson I. Complete acromioclavicular dislocations: treatment with a Dacron ligament. *Injury.* 22 (1991) 173–176
- Talbert T.W., Green J.R.<sup>3rd</sup>, Mukherjee D.P., Ogden A.L., Mayeux R.H. Bioabsorbable screw fixation in coracoclavicular ligament reconstruction. *J Long Term Eff Med Implants.* 13 (2003) 319-323
- Thorndike A.J., Quigley T.B. Injuries to the acromioclavicular joint: a plea for conservative treatment. *Am J Surg.* 55 (1942) 250–261
- Tossy J.D., Mead N.C., Sigmond H.M. Acromioclavicular separations: Useful and practical classification for treatment. *Clin Orthop.* 28 (1963) 111–119
- Tsou P.M. Percutaneous cannulated screw coracoclavicular fixation for acute acromioclavicular dislocations. *Clin Orthop.* 243 (1989) 112-121
- Urban J., Jaskiewicz A. Idiopathic displacement of Kirschner wire to the thoracic cavity after the osteosynthesis of the AC joint. *Chir Narzadow Ruchii Orthop Pol.* 49 (1984) 399-402
- Urist M.R. The treatment of dislocations of the acromioclavicular joint. A survey of the past decade. *Am J Surg.* 98 (1959) 423-431
- Verhaven E., DeBoeck H., Haentjens P. Surgical treatment of acute type-V acromioclavicular injuries in athletes. *Arch Orthop Trauma Surg.* 112 (1993) 189–192
- Weaver J.K., Dunn H.K. Treatment of acromioclavicular injuries, especially complete acromioclavicular separation. *J Bone Joint Surg.* 54A (1972) 1187–1194
- Weinstein D.M., McCann P.D., McIlveen S.J. Surgical treatment of complete acromioclavicular dislocations. *Am J Sports Med.* 23 (1995) 324-321
- Wiley A.M. Superior humeral dislocation. A Complication following decompression and debridement for rotator cuff tears. *Clin Orthop.* 263 (1991) 135-141

## 10 FIGURE LEGENDS

<b>Figure 1.</b>	Demonstrating the acromioclavicular joint (1), coracoacromial ligament (2), Trapezoid ligament (3), and Conoid ligament (4)....	11
<b>Figure 2.</b>	Showing the dislocated acromioclavicular on the left shoulder. The arrow shows tenting of the skin at the distal clavicle.....	14
<b>Figure 3.</b>	Demonstrating Rockwood Classification of acromioclavicular joint injury .....	16
<b>Figure 4.</b>	Demonstrating the coracoclavicular ligament complex. (T= Trapezoid, C=Conoid) .....	21
<b>Figure 5.</b>	Demonstrating the Zwick testing machine. The data were acquired by using the Zwick soft ware and complied using a desktop computer.....	22
<b>Figure 6.</b>	The body of scapula was embedded in an open-top steel box with Epoxy resin, allowing the upper part of the spine, glenoid and coracoid to protude. The clavicle was secured to the testing machine (Zwick) with nut and bolts through 2 drill holes into the clavicle that were connected with a plate.....	23
<b>Figure 7.</b>	Depiction of coracoacromial ligament .....	25
<b>Figure 8.</b>	Demonstrating the Weaver-Dunn procedure. The distal clavicle was excised and the coracoacromial ligament was transferred into the medullary canal of the clavicle.....	26

<b>Figure 9.</b>	View from the top of the Imhoff delivery device and small titanium plates.....	28
<b>Figure 10.</b>	The suture anchors tested include ( from left to right) the 5.5-mm Corkscrew FT, 5.0-mm Corkscrew, 3.5-mm Corkscrew, 2.8-mm Fastak .....	29
<b>Figure 11.</b>	The 2.8-mm Fastak with fiberwire and a small titanium plate .....	30
<b>Figure 12.</b>	The 5.5-mm Corkscrew FT with fiberwires#2. The arrow demonstrates the fiberwire#2 loop in the screw.....	31
<b>Figure 13.</b>	The 2.8-mm Fastak is placed into the superior surface of the base of the corocoid .....	32
<b>Figure 14.</b>	The strand of each suture is passed out just anterior to the distal clavicle.....	33
<b>Figure 15.</b>	The meniscus needle with a 2/0 thread is passed through the tunnel from superior .....	34
<b>Figure 16.</b>	The free ends of the fiberwires are retrieved through the tunnel in distal clavicle .....	35
<b>Figure 17.</b>	The four free ends of the Fiberwires No.2 are passed through the holes of the titanium plate and the slip-knot are performed and tightened over the titanium .....	36
<b>Figure 18.</b>	Setup of the specimen in the mechanical testing machine. Construct with 2.8-mm Fastak with fiberwire#2 and small titanium plate	

loaded on testing apparatus.....	37
<b>Figure 19.</b> Technique for reconstruction with Corkscrew FT with 2 loops of fiberwire#2 .....	38
<b>Figure 20.</b> Five-mm PDS tape is looped under the coracoid and through a drill hole in the clavicle, then tied on the medial side.....	40
<b>Figure 21.</b> The 6.5-mm cancellous screw.....	42
<b>Figure 22.</b> Modified Bosworth technique for reduction and fixation of acromioclavicular dislocation. Construct with a screw and washer placed through the clavicle and into the base of coracoid.....	43
<b>Figure 23.</b> Load-displacement curve for the coracoclavicular ligament. The arrow indicate the portion of the curve that was used to calculate stiffness .....	45
<b>Figure 24.</b> Load-displacement curve for the native coracoclavicular ligament...	51
<b>Figure 25.</b> Demonstrating the ultimate tensile strength of different reconstruction techniques.....	53
<b>Figure 26.</b> Demonstrating the stiffness of different reconstruction techniques..	54
<b>Figure 27.</b> Demonstrating the elongation at failure of different reconstruction techniques .....	55
<b>Figure 28.</b> The fiberwire loop in the 5.5-mm Corkscrew FT rupture, the anchor does not pullout .....	71

## 11 TABLE LEGENDS

<b>Table 1.</b>	Main primary stabilizers of the AC-joint in relation to the direction of the force.....	12
<b>Table 2.</b>	Mode of Failure for Suture Anchors.....	48
<b>Table 3.</b>	Comparison of Biomechanical characteristics of the intact coracoclavicular ligament(CC) and the different reconstruction techniques.....	52
<b>Table 4.</b>	Suture Anchors Properties.....	70



## 12 ACKNOWLEDGEMENTS

I wish to gratefully thank

**Prof. Dr. Med. Andreas B. Imhoff** – Director of the Department of Sportorthopedics, Technical University of Munich for his phenomenal support of my research and medical practice in the Sports Medicine clinic and Rechts der Isar Hospital—München. I am especially grateful for his valuable insight, which generated helpful and indispensable discussions;

**Dr. Erwin Steinhauser** – Division of Biomechanics, Department of Orthopaedics, Technical University of Munich, for his inspiration, genuine support and continual assistance in statistical analyses leading to the completion of this research;

**Assistant Prof. Dr. Kammal Kumalpawa** – Dean of Faculty of Medicine, Thammasat University, Thailand, for encouraging me to further my medical studies in Germany;

**Arthrex** – A medical equipment and supplies company, for contributing the suture anchors device necessary for conducting my research;

**Dr. Pataravit Rukskul and Mr. Torsten Steinbrunn** – My colleagues and dear friends, for their invaluable suggestions, criticisms and assistance throughout this research endeavor;

**Dr. Singh Intrachooto-** My brother-in-law for his advice on administrative logistics and expedient editing;

I would very much like to thank the entire staff of the Department of Sports Orthopaedics, Technical University of Munich, for a truly effective and efficient assistance, especially in obtaining the principal data.

Most important of all, I owe a deeply grateful thank to my wife, **Dr. Janejai Chernchujit**, my mother **Sophis Chernchujit**, and my entire family, for their untiring love, thoughtfulness and assistance through this and all previous challenges.

### **13 GRANT SOURCES**

My stay in Germany, at department of orthopedics and sportorthopedics, Technical University of Munich, and the fulfillment of the present study project was made possible through the scholarship from **Faculty of Medicine, Thammasat University, Thailand** (1 April 2003 – 30 September 2004).

## **BANCHA CHERNCHUJIT, M.D.**

Department of Orthopaedic Surgery, Faculty of Medicine, Thammasat University (Rangsit Campus), Klong 1, Klong-Luang, Pathumthani 12121, Thailand

**Born:** May 14, 1970

### **Education:**

1987 - 1989 **High School** – Triamudomsuksa School, Bangkok, Thailand  
1989 - 1995 **M.D.** – Siriraj Medical School, Mahidol University, Bangkok, Thailand

### **Post-doctoral Training:**

1995 - 1996 **Internship** – Faculty of Medicine, Thammasat University, Pathumthani, Thailand  
1996 - 2000 **Residency Training in Orthopaedics** – Faculty of Medicine, Siriraj Hospital, Mahidol University, Bangkok, Thailand  
2000 **Fellowship** – Fellows of the Royal College of Orthopaedic Surgeons of Thailand  
2000 **Fellowship** – Fellows of the Royal College of Surgeons of Thailand  
2002 - 2004 **Fellowship in Sportsorthopaedics** – Department of orthopaedics and Sports Medicine, Technical University of Munich, Munich, Germany

### **Licensure:**

1995 **Thailand**

### **Certification:**

1999 **Diplomate Thai Board of Orthopaedic Surgery**

### **Academic Appointments:**

2000 - 2003 **Instructor** in Orthopaedic Surgery, Faculty of Medicine, Thammasat University, Pathumthani, Thailand

### **Memberships:**

Thai Medical Association  
The Royal College of Surgeons of Thailand  
The Royal College of Orthopaedic Surgeons of Thailand

**Marital Status:** Married

### **Office Address:**

Division of Orthopaedic Surgery, Faculty of Medicine, Thammasat University (Rangsit Campus) Klong 1, Klong-Luang, Pathumthani 12121, Thailand

### **Home Address:**

2308/21 Paholyotin Ladyao, Jatujak, Bangkok, 10260, Thailand

**Email Address:** [bancha61@yahoo.com](mailto:bancha61@yahoo.com)

**Representative Publications:**

**Books**

Chernchujit, B. : Prevention of osteoporosis.10<sup>th</sup> year Anniversary of Thammasat university hospital. 377 pp (in Thai).

**Articles in journals/contributions to books**

Chernchujit, B : Viscosupplementation. Clinic. 2003,February; 19(2):118-130.

Chernchujit, B : Old lateral Condylar fracture: Clinic. 2002, December;18(12): 1033-1038.

Manorangsang S, Chernchujit B : gait analysis : Thammasat Medical Journal. 2003, June-September; 3 (3), 528-537

Chernchujit, B; Imhoff AB : Arthroscopic stabilization of acromioclavicular joint disruption. Arthroscopy.2004 ( in press)

Rukskul, P. and Chernchujit B., Ossification of posterior longitudinal ligament presented with hemiplegia : case discussion, in preparation, approximate page volume : 5 pages.

Rukskul, P. and Chernchujit, B., Hemiparesis associated with blunt cervical injury, in preparation, approximate page volume : 5 pages.

**Published contributions to academic conferences**

Chernchujit, B.(2001) : Location of superior cluneal nerve on the posterior iliac crest . Proceedings of the Joint Meeting of Royal College of Orthopedics of Thailand at Royal Cliff Beach Hotel, Choburi, Thailand, 23 October 1999.

Last Update : 20 January 2004